



PATIENT

Tilly Weinberger

SPECIES

Feline

BREED

DSH

SEX

Spayed Female

AGE

4 Years

WEIGHT

4.3 kg

INTERPRETED BY

Eric Lindquist, DMV
DABVP, Cert. IVUSS

IMAGING PERFORMED BY

Dr. Belan

HOSPITAL NAME

McKnight 24 Hour AH

REFERRING VET

Dr. Gruffydd

INVOICE

13234

DATE

12/29/21

PRESENTING CLINICAL SIGNS

History: Vomiting diarrhea 48 hrs anorexic originally was hyperglycaemic now hypoglycaemic but eating and not vomiting. Owner says will eat needles of off the X mas tree. Being fed every 2-4 hrs

Abnormal PE/Chem/CBC/UA Results: Hyperglycaemic on presentation now hypoglycemic. Glucoseuria and mild elevated fructosamine. Blood sugar low normal at time of scan

ULTRASONOGRAPHIC EXAMINATION OF THE ABDOMEN

Urinary System

The **urinary bladder**, trigone, and pelvic urethra presented normal thicknesses and normal tone. The ureters were not visible which is normal. No uroliths or sediment were visualized, and anechoic urine was present. No evidence of inflammatory or neoplastic changes were noted. Ureteral papillae were normal.

The **kidneys** revealed normal size and structure, corticomedullary definition and ratio for this age. The cortices presented largely uniform texture with normal echogenic relationship to liver and spleen. Medullary structure differed distinctly from the cortex and no evidence of pelvic dilation was present. The capsules were acceptably uniform without significant irregularities. The right kidney measured 3.64 cm. The left kidney measured 3.77 cm.

Adrenal Glands

Both **adrenal glands** were visualized and recognized as having normal shape, size, position and echogenicity for this breed. The phrenic vasculature, glandular echogenicity and detail were unremarkable. Capsule, cortex, and medullary definition were normal for this age patient. The left adrenal gland measured 0.33 cm. The right adrenal gland measured 0.27 cm.

Spleen

The **spleen** presented a smooth homogeneous parenchyma hyperechoic to liver and renal cortical parenchyma. The capsule was smooth without noticeable expansion or deviation from within the spleen or adjacent pathology. The splenic vasculature demonstrated normal volume without signs of congestion or thrombosis. No sonographic evidence of acute or chronic inflammatory, neoplastic, or infarctual changes were noted.

Liver

The **liver** images submitted revealed subjectively normal liver size, contour, and structure. Parenchymal echogenicity was naturally coarse and hypoechoic to the spleen. Vascular and biliary tracts were of normal volume with no evidence of congestion. The gallbladder presented acceptably thin walls with primarily anechoic content. The cystic and common bile ducts were normal. No pathological hepatic lymphadenopathy was evident. No overt structural evidence of inflammatory, infiltrative or regenerative pathology was evident. Portal vein to vena cava ratio was 1:1.

Gastrointestinal

Examination of the **gastrointestinal tract** revealed a stomach and intestine free of stasis, of normal wall thickness, acceptable curvilinear mural detail, and peristaltic activity. Small and large intestine demonstrated normal luminal chyme and stool consistency respectively. No obstructive or overt infiltrative disease was noted. No associated abnormal lymphatic activity was noted.



PATIENT

Pancreas

Tilly Weinberger

The base and limbs of the **pancreas** were observed to be largely isoechoic to surrounding omental fat. Pancreatic duct and capsular contour were acceptably normal and parenchyma respected normal curvilinear patterns. No overt evidence of active inflammatory or neoplastic disease was noted.

SPECIES

Feline

ULTRASONOGRAPHIC FINDINGS

- Structurally unremarkable abdomen

BREED

DSH

INTERPRETATION OF THE FINDINGS & FURTHER RECOMMENDATIONS

No evidence of pathology. The cause of anorexia is not evident.

SEX

Spayed Female

AGE

4 Years

WEIGHT

4.3 kg

INTERPRETED BY

Eric Lindquist, DMV
DABVP, Cert. IVUSS

IMAGING PERFORMED BY

Dr. Belan

HOSPITAL NAME

McKnight 24 Hour AH

REFERRING VET

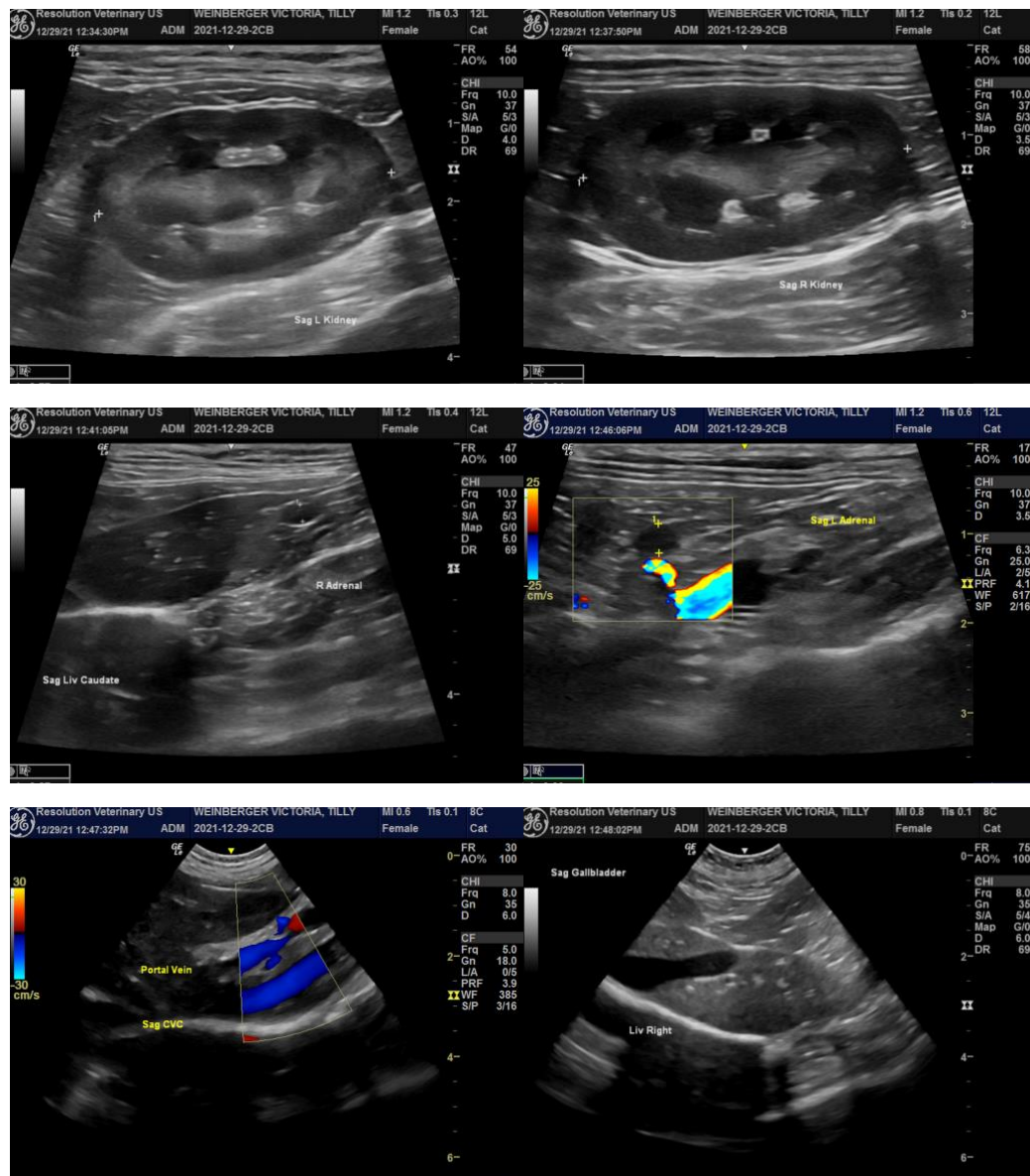
Dr. Gruffydd

INVOICE

13234

DATE

12/29/21





PATIENT

Tilly Weinberger

SPECIES

Feline

BREED

DSH

SEX

Spayed Female

AGE

4 Years

WEIGHT

4.3 kg

INTERPRETED BY

Eric Lindquist, DMV
DABVP, Cert. IVUSS

IMAGING PERFORMED BY

Dr. Belan

HOSPITAL NAME

McKnight 24 Hour AH

REFERRING VET

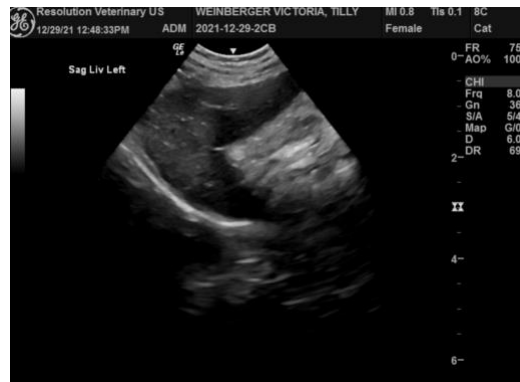Dr. Gruffydd

INVOICE

13234

DATE

12/29/21



The information and recommendations provided are based on the images presented by the referring veterinarian. No evaluation can be communicated regarding pathology that was not visible in the image/video clips provided.

Thank you for this referral. If the clinical or image interpretation does not parallel your findings or if I can be of any further assistance please contact me.

Eric Lindquist, DMV, DABVP, Cert. IVUSS, CEO of SonoPath.com
info@SonoPath.com