



PATIENT

Yum Yum Doyle

SPECIES

Feline

BREED

DSH

SEX

Spayed Female

AGE

2008

WEIGHT

7.76 lbs

INTERPRETED BY

Eric Lindquist, DMV
DABVP, Cert IVUSS

IMAGING PERFORMED BY

Denise Bruno, LVT,
RDMS

HOSPITAL NAME

Brooklyn Heights VH

REFERRING VET

Dr. Thomson

INVOICE

13218

DATE

12/28/21

PRESENTING CLINICAL SIGNS

History: Thin, weight loss, despite good appetite

ULTRASONOGRAPHIC EXAMINATION OF THE ABDOMEN

Urinary System

The **urinary bladder**, trigone, and pelvic urethra presented normal thicknesses and normal tone. The ureters were not visible which is normal. No uroliths or sediment were visualized, and anechoic urine was present. No evidence of inflammatory or neoplastic changes were noted. Ureteral papillae were normal. The pelvic urethra was imaged 3.0 cm beyond the cystourethral junction.

The **kidneys** revealed largely normal size and structure, corticomedullary definition and ratio (cortex 1/3 of medulla) were essentially maintained with some minor age-related loss of curvilinear patterns regarding the capsule and C/M junction. The cortices presented largely uniform texture with some increased echogenicity expected for his age patient. Medullary structure differed distinctly from that of the cortex and no evidence of pelvic dilation was present. The right kidney measured 3.7 cm. The left kidney measured 3.77 cm.

Adrenal Glands

Both **adrenal glands** were visualized and recognized as having normal shape, size, position and echogenicity for this breed. The phrenic vasculature, glandular echogenicity and detail were unremarkable. Capsule, cortex, and medullary definition were normal for this age patient. The right adrenal gland measured 0.39 cm. The left adrenal gland measured 0.42 cm.

Spleen

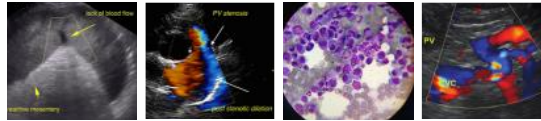
The **spleen** presented a smooth homogeneous parenchyma hyperechoic to liver and renal cortical parenchyma. The capsule was smooth without noticeable expansion or deviation from within the spleen or adjacent pathology. The splenic vasculature demonstrated normal volume without signs of congestion or thrombosis. No sonographic evidence of acute or chronic inflammatory, neoplastic, or infarctual changes were noted.

Liver

The **liver** images submitted revealed subjectively normal liver size, contour, and structure. Parenchymal echogenicity was naturally coarse and hypoechoic to the spleen. Vascular and biliary tracts were of normal volume with no evidence of congestion. The gallbladder presented acceptably thin walls with primarily anechoic content. The cystic and common bile ducts were normal. No pathological hepatic lymphadenopathy was evident. No overt structural evidence of inflammatory, infiltrative or regenerative pathology was evident.

Gastrointestinal

The **gastrointestinal** presentation revealed mild uniform prominence of the gastric mucosa as well as areas of "ropey" small intestinal wall. Muscularis/mucosal ratio was 1:1. The intestinal submucosa was slightly irregular, thickened and hyperechoic suggestive of low grade, chronic disease. Intestinal wall thickness measured up to 0.32 cm. No concerning lymphadenopathy was visible. No evidence of obstruction was present. Chronic inflammatory bowel disease is likely with a low possibility of an early neoplastic event such as lymphoma. Full thickness tissue biopsies via open laparotomy, ideally guided



PATIENT

Yum Yum Doyle

by intraoperative ultrasound in order to obtain the most representative mural sample, would be necessary to rule out this possibility.

Pancreas

SPECIES

Feline

The base and limbs of the **pancreas** were observed to be largely isoechoic to surrounding omental fat. Some moderate parenchymal remodeling, however, with mild deviation from curvilinear normalcy was observed. Pancreatic duct and capsular irregularities were present consistent with age related changes. If pain upon imaging (+ Murphy sign) was present or if the patient is focally painful in subxyphoid palpation then low-grade smoldering chronic pancreatitis should be suspected.

BREED

DSH

SEX

Spayed Female

- Diffuse intestinal thickening with hypertrophied muscularis
- Prominent pancreas
- Geriatric abdominal changes

AGE

2008

ULTRASONOGRAPHIC FINDINGS

INTERPRETATION OF THE FINDINGS & FURTHER RECOMMENDATIONS

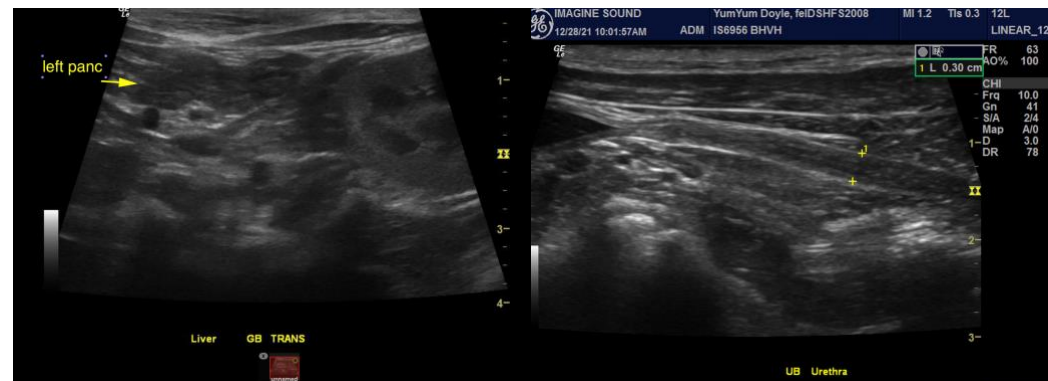
WEIGHT

7.76 lbs

Low grade pancreatic inflammation possible as the cause of the clinical signs +/- inflammatory bowel. No overt neoplastic criteria visible in this patient. However, emerging gastrointestinal round cell neoplasia cannot be completely ruled out. Full thickness biopsies would be necessary for further definition.

INTERPRETED BY

Eric Lindquist, DMV
DABVP, Cert IVUSS



IMAGING PERFORMED BY

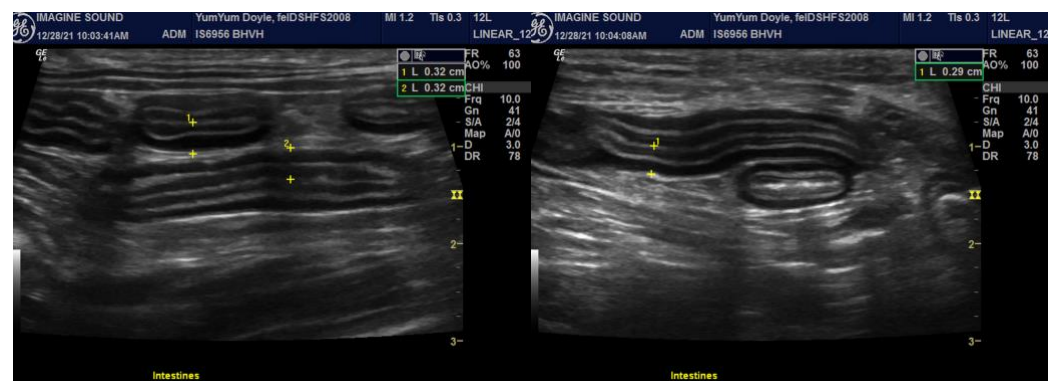
Denise Bruno, LVT,
RDMS

HOSPITAL NAME

Brooklyn Heights VH

REFERRING VET

Dr. Thomson



INVOICE

13218

DATE

12/28/21



PATIENT

Yum Yum Doyle

SPECIES

Feline

BREED

DSH

SEX

Spayed Female

AGE

2008

WEIGHT

7.76 lbs

INTERPRETED BY

Eric Lindquist, DMV
DABVP, Cert IVUSS

IMAGING PERFORMED BY

Denise Bruno, LVT,
RDMS

HOSPITAL NAME

Brooklyn Heights VH

REFERRING VET

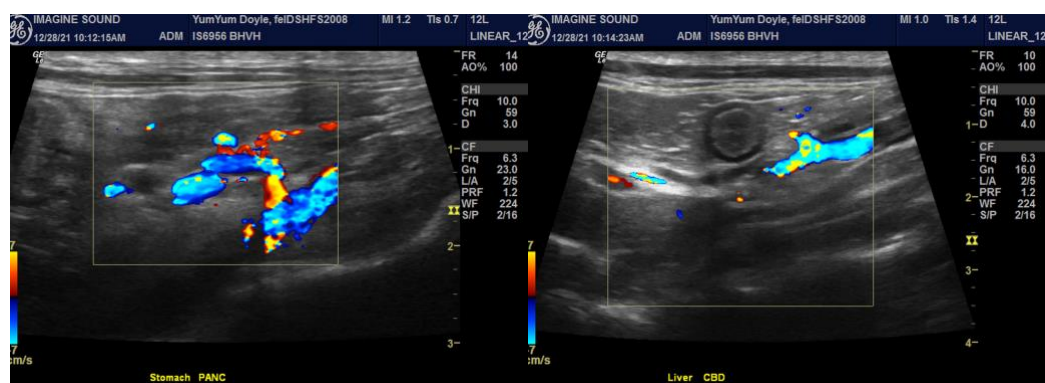
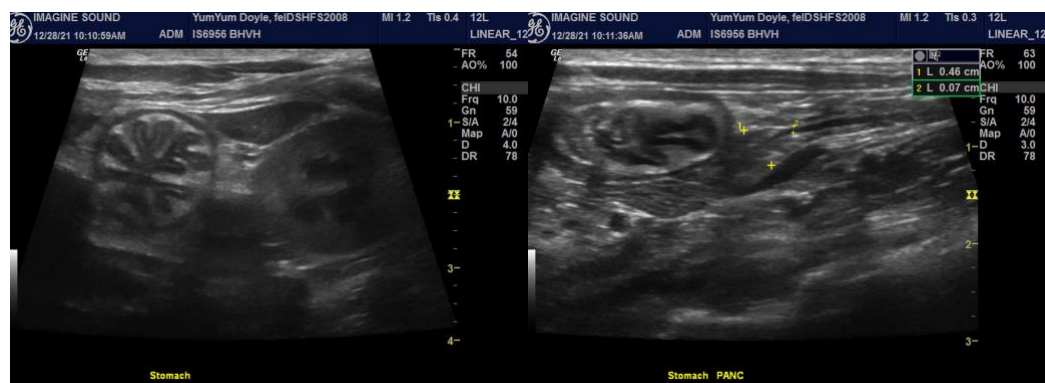
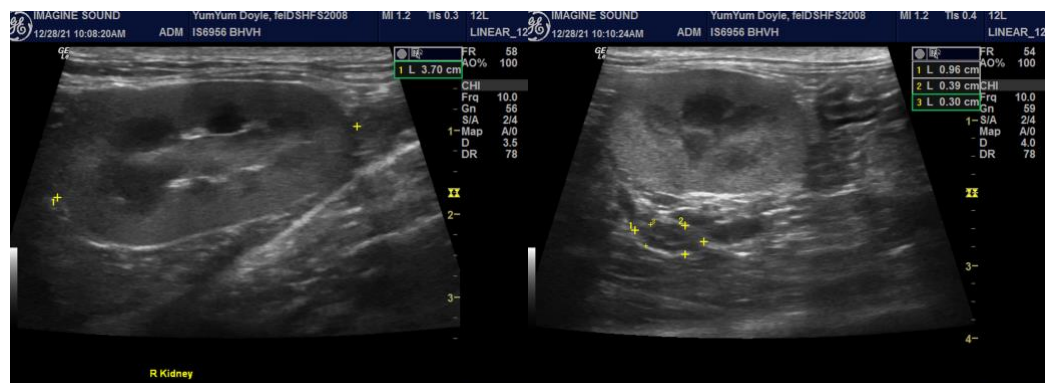
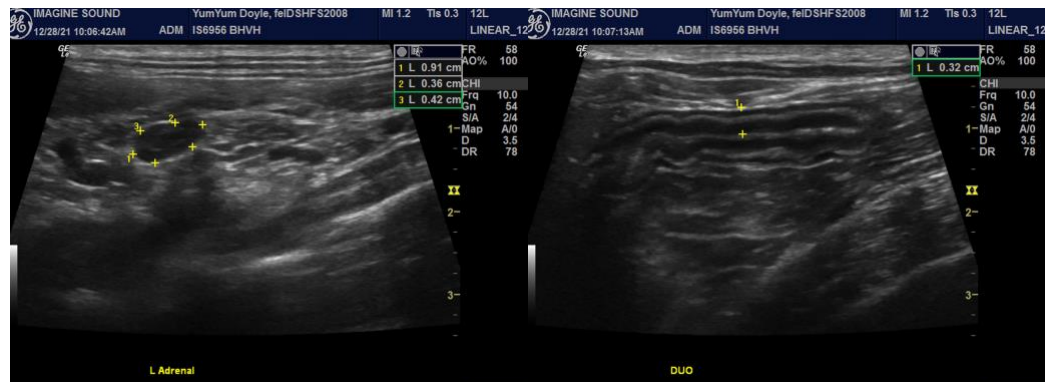
Dr. Thomson

INVOICE

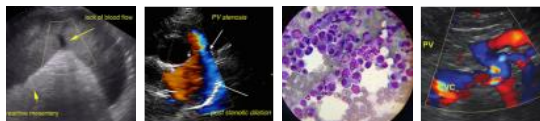
13218

DATE

12/28/21



The information and recommendations provided are based on the images presented by the referring veterinarian. No evaluation can be communicated regarding pathology that was not visible in the image/video clips provided.



PATIENT

Yum Yum Doyle

Thank you for this referral. If the clinical or image interpretation does not parallel your findings or if I can be of any further assistance please contact me.

SPECIES

Feline

Eric Lindquist, DMV, DABVP, Cert. IVUSS, CEO of SonoPath.com
Eric.Lindquist@SonoPath.com

BREED

DSH

SEX

Spayed Female

AGE

2008

WEIGHT

7.76 lbs

INTERPRETED BY

Eric Lindquist, DMV
DABVP, Cert IVUSS

IMAGING PERFORMED BY

Denise Bruno, LVT,
RDMS

HOSPITAL NAME

Brooklyn Heights VH

REFERRING VET

Dr. Thomson

INVOICE

13218

DATE

12/28/21