



**PATIENT**

Felix Witko

**SPECIES**

Feline

**BREED**

DSH

**SEX**

Neutered Male

**AGE**

15 Years

**WEIGHT**

12 Pounds

**INTERPRETED BY**

Eric Lindquist, DMV  
DABVP, Cert. IVUSS

**IMAGING PERFORMED BY**

Kelly Vazquez

**HOSPITAL NAME**

North Haledon VC

**REFERRING VET**

Dr. Mansfield

**INVOICE**

33782

**DATE**

12/28/21

**PRESENTING CLINICAL SIGNS**

Weight loss, decreased appetite, previously well regulated hyperthyroidism. Current meds: methimazole.

Abnormal PE/Chem/CBC/UA Results: Ca++ 11.5, PSL 29, T4 8.4.

**ULTRASONOGRAPHIC EXAMINATION OF THE ABDOMEN**

**Urinary System**

The **urinary bladder**, trigone, and pelvic urethra presented normal thicknesses and normal tone. The ureters were not visible which is normal. No uroliths or sediment were visualized and anechoic urine was present. No evidence of inflammatory or neoplastic changes were noted. Ureteral papillae were normal.

The **kidneys** revealed largely normal size and structure, corticomedullary definition and ratio (cortex 1/3 of medulla) were essentially maintained with some age-related loss of curvilinear patterns regarding the capsule and C/M junction. The cortices presented largely uniform texture with some increased echogenicity expected for his age patient. Medullary structure differed distinctly from that of the cortex and no evidence of pelvic dilation was present. The left kidney measured 3.67 cm. The right kidney measured 4.0 cm.

**Adrenal Glands**

Both **adrenal glands** were visualized and recognized as having normal shape, size, position and echogenicity for this breed. The phrenic vasculature, glandular echogenicity and detail were unremarkable. Capsule, cortex, and medullary definition were normal for this age patient. The right adrenal gland measured 0.34 cm.

**Spleen**

The **spleen** presented a smooth homogeneous parenchyma hyperechoic to liver and renal cortical parenchyma. The capsule was smooth without noticeable expansion or deviation from within the spleen or adjacent pathology. The splenic vasculature demonstrated normal volume without signs of congestion or thrombosis. No sonographic evidence of acute or chronic inflammatory, neoplastic, or infarctual changes were noted.

**Liver**

The **liver** presented coarse architecture with mildly increased portal markings. The gallbladder wall was echogenic. Consistent with history of cholangitis.

**Gastrointestinal**

Examination of the **gastrointestinal tract** revealed a stomach and intestine free of stasis, of normal wall thickness, acceptable curvilinear mural detail, and peristaltic activity. Small and large intestine demonstrated normal luminal chyme and stool consistency respectively. No obstructive or overt infiltrative disease was noted. No associated abnormal lymphatic activity was noted.

**Pancreas**

The base and limbs of the **pancreas** were observed to be largely isoechoic to surrounding omental fat. Some parenchymal remodeling, however, with mild deviation from curvilinear normalcy was observed. Pancreatic duct and capsular irregularities were present consistent with age related changes. If pain upon imaging (+ Murphy sign) was present or if the patient is focally painful in subxyphoid palpation then low-grade smoldering chronic pancreatitis should be suspected.



**PATIENT**

Felix Witko

**SPECIES**

Feline

**BREED**

DSH

**SEX**

Neutered Male

**AGE**

15 Years

**WEIGHT**

12 Pounds

**ULTRASONOGRAPHIC FINDINGS**

- Hepatic remodeling – consistent with history of cholangitis
- Mild age related renal changes
- Unremarkable abdomen otherwise

**INTERPRETATION OF THE FINDINGS & FURTHER RECOMMENDATIONS**

Possible low-grade pancreatitis as cause of the clinical signs. However, no evidence of neoplasia. Subxiphoid palpation is recommended to assess for pain or discomfort associated with the pancreas. Maldigestion panel, three view chest radiographs and full CNS examination is recommended to examine for occult disease that could be responsible for the weight loss. Evaluation for competitive eating environments should also be considered.

**INTERPRETED BY**

Eric Lindquist, DMV  
DABVP, Cert. IVUSS

**IMAGING PERFORMED BY**

Kelly Vazquez

**HOSPITAL NAME**

North Haledon VC

**REFERRING VET**

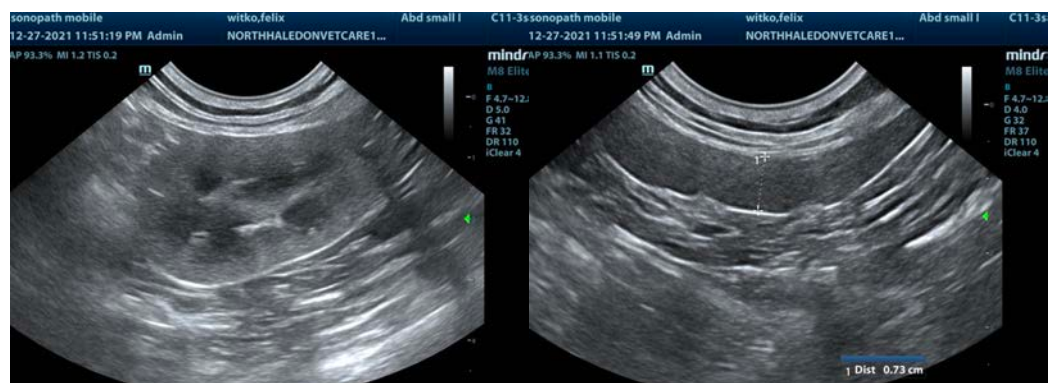
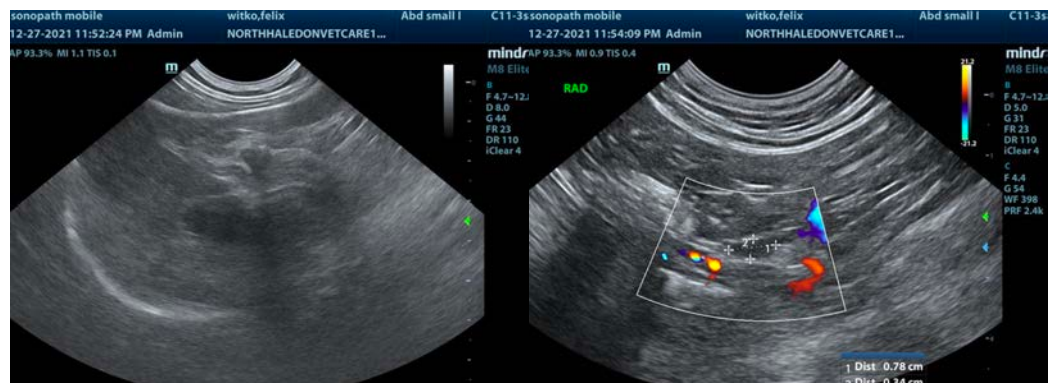
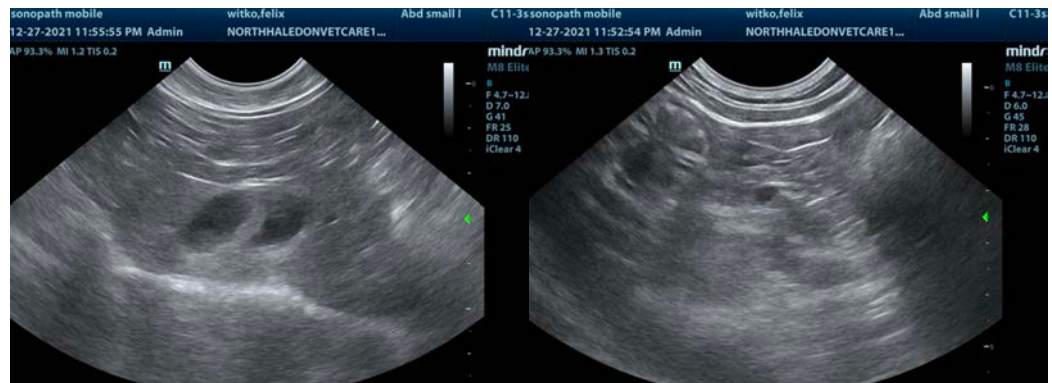
Dr. Mansfield

**INVOICE**

33782

**DATE**

12/28/21





**PATIENT**

Felix Witko

**SPECIES**

Feline

**BREED**

DSH

**SEX**

Neutered Male

**AGE**

15 Years

**WEIGHT**

12 Pounds

**INTERPRETED BY**

Eric Lindquist, DMV  
DABVP, Cert. IVUSS

**IMAGING  
PERFORMED BY**

Kelly Vazquez

**HOSPITAL NAME**

North Haledon VC

**REFERRING VET**

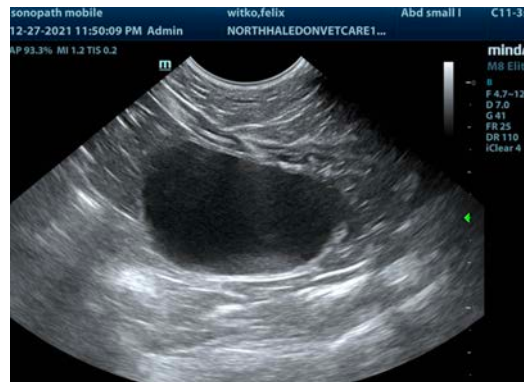Dr. Mansfield

**INVOICE**

33782

**DATE**

12/28/21



The information and recommendations provided are based on the images presented by the referring veterinarian. No evaluation can be communicated regarding pathology that was not visible in the image/video clips provided.

Thank you for this referral. If the clinical or image interpretation does not parallel your findings or if I can be of any further assistance please contact me.

Eric Lindquist, DMV, DABVP, Cert. IVUSS, CEO of SonoPath.com  
[info@SonoPath.com](mailto:info@SonoPath.com)