



**PATIENT PRESENTING CLINICAL SIGNS**

Chloe Hubert      Approx. 3-4 months suspected seizures- cries, urinate then sleeps. More and more episodes, used to be once a month - recent murmur heard. Current meds: just started Phenobarb 15mg BID 12/17/21  
 Abnormal PE/Chem/CBC/UA Results:      Sept 2021: BUN 35, Plat 531 UA: pH7 SG: 1.020

**SPECIES ULTRASONOGRAPHIC EXAMINATION OF THE HEART**

Canine

BREED	CANINE CARDIAC PARAMETERS	MR VMAX (m/s)	TR VMAX (m/s)	LA/AO (Boon method)	LA/AO (Heart Base; Swe)	FS (%)	EF (%)	EPSS (cm)
Shih Tzu								
SEX	NORMAL PARAMETER	4.5-5.5	<2.7	1.3	<1.6	28-40	40-100	<0.6
Spayed Female	PATIENT	5.7	2.9	1.21	1.5	51	84	NM
AGE	CANINE CARDIAC PARAMETERS	HR (BPM)	AV VMAX (m/s)	PV MAX (m/s)	BODY WEIGHT (kg)	LA 2D short axis Base view (cm)	LVIDd Avg; 2D and m-mode short axis (cm)	LVIDs Avg; 2D and m-mode short axis (cm)
16 Years								
WEIGHT	NORMAL PARAMETER	50-100	0.7-1.7	0.7-1.6				
10.9 Pounds	PATIENT	156	1.3	0.92		3.1	2.63	

**INTERPRETED BY Cardiac Presentation**

Eric Lindquist, DMV  
DABVP, Cert. IVUSS

**IMAGING PERFORMED BY**

Jessica Miller

**HOSPITAL NAME**

Whippany Vet Hospital

**REFERRING VET**

Dr. Cordero

The echocardiogram for this patient presented excessive **left atrial size** expressed both in the LA/AO and LA max measurements Chamber volumes and echogenicity were normal. The cranial and caudal **mitral** valve leaflets presented vegetative thickening consistent with endocardiosis. Doppler indicated measurable insufficiency. Prolapse of the anterior mitral valve leaflet noted. The **left ventricle** presented thicknesses with linear contour and was not dilated nor restricted. The **myocardium** presented normal echogenicity without subjective evidence of significant fibrotic or ischemic disease. **Contractility** of the ventricular walls was adequate and in normal range for this patient evidenced by the fractional shortening measurement and subjective evaluation of the different regions of the myocardium. **Aortic** insufficiency noted at 4.0 m/sec. The **right atrium** and auricle revealed normal size, structure and content. No evidence of masses was noted or chamber overload. **Tricuspid** insufficiency noted. The **right ventricle** was of normal size (1/3 diameter of LV), chordae structure, myocardial echogenicity and thickness. **Pulmonic** tract assessment revealed normal valve structure, laminar flow, and diameter (approx.1:1 pa/ao ratio). No visible **pericardial** or free pleura fluid was noted. No echographically detectable evidence of infiltrative disease was visible. The cranial **mediastinum and pericardial regions** were free of masses in the visible window.

**ULTRASONOGRAPHIC FINDINGS**

- Left atrial enlargement with mitral insufficiency - Stage B2 valvular disease
- Concurrent aortic insufficiency

**INTERPRETATION OF THE FINDINGS & FURTHER RECOMMENDATIONS**

**DATE** 12/28/21  
 Recommend initiating Pimobendan at 0.3 mg/kg BID. ACE inhibitor therapy would be warranted if systolic pressure is 160 or greater. The seizure activity is likely unrelated to the cardiac presentation.



**PATIENT**

Chloe Hubert

CT with contrast of the brain would be recommended given the patient history. However, adjustment for early stage B2 valvular disease would be warranted with Pimobendan.

**SPECIES**

Canine

**SonoPath CT Services** are offered at the [Blainstow Animal Hospital](https://www.blainstowanimalhospital.com/). Blainstow animal hospital is just a 30-minute drive west on route 80 from the route 80/287 interchange/Parsippany, New Jersey. More information can be found at:

<https://sonopath.com/resources/sonopaths-teleconsultation-services-and-sdep-certification/sonopath-ct-services>

**BREED**

Shih Tzu

**SEX**

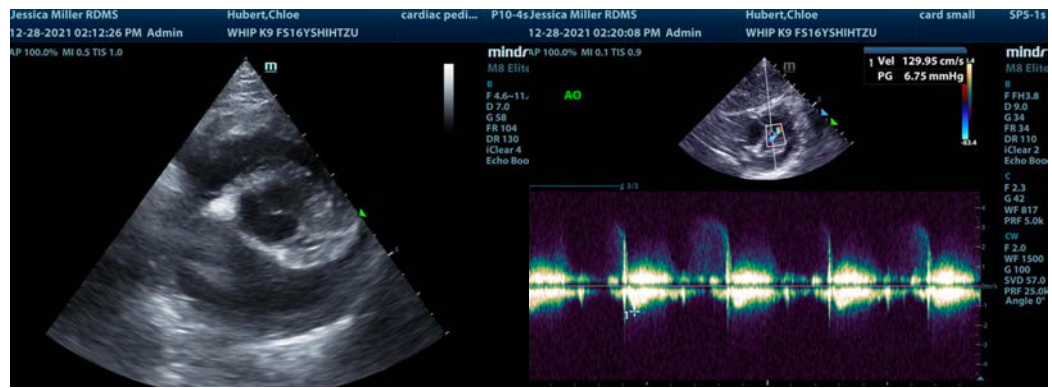
Spayed Female

**AGE**

16 Years

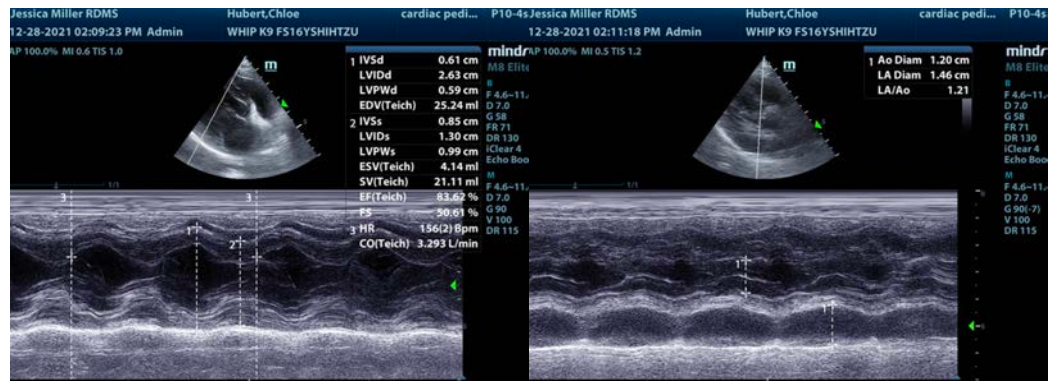**WEIGHT**

10.9 Pounds



**INTERPRETED BY**

Eric Lindquist, DMV  
DABVP, Cert. IVUSS

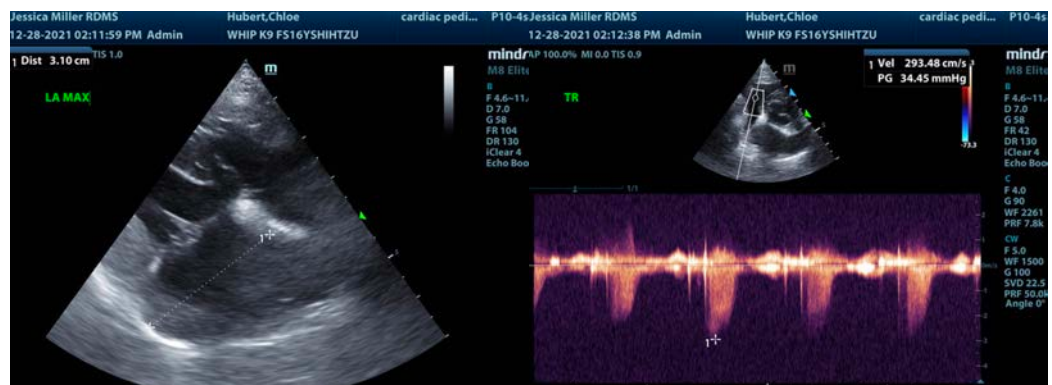


**IMAGING PERFORMED BY**

Jessica Miller

**HOSPITAL NAME**

Whippany Vet Hospital



**REFERRING VET**

Dr. Cordero

**INVOICE**

33791

**DATE**

12/28/21



**PATIENT**

Chloe Hubert

**SPECIES**

Canine

**BREED**

Shih Tzu

**SEX**

Spayed Female

**AGE**

16 Years

**WEIGHT**

10.9 Pounds

**INTERPRETED BY**

Eric Lindquist, DMV  
DABVP, Cert. IVUSS

**IMAGING PERFORMED BY**

Jessica Miller

**HOSPITAL NAME**

Whippany Vet Hospital

**REFERRING VET**

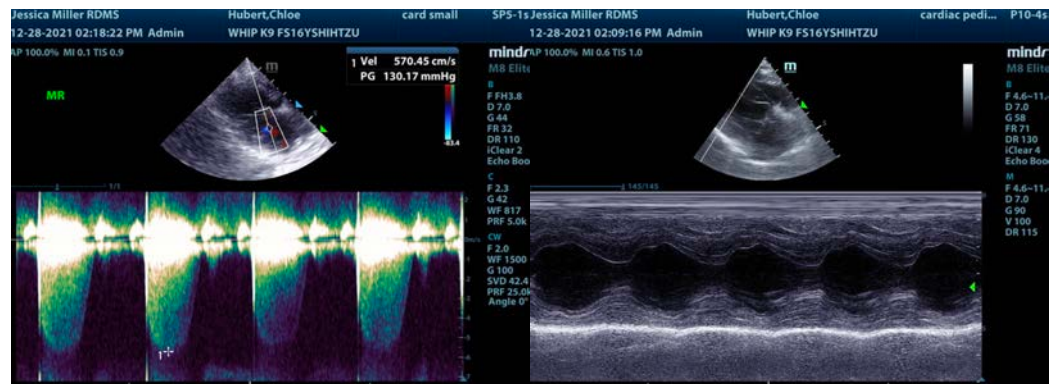
Dr. Cordero

**INVOICE**

33791

**DATE**

12/28/21



The information and recommendations provided are based on the images presented by the referring veterinarian. No evaluation can be communicated regarding pathology that was not visible in the image/video clips provided.

Thank you for this referral. If the clinical or image interpretation does not parallel your findings or if I can be of any further assistance please contact me.

Eric Lindquist, DMV, DABVP, Cert. IVUSS, CEO of SonoPath.com  
[info@SonoPath.com](mailto:info@SonoPath.com)