



**PATIENT**

Champ Alves

**SPECIES**

Canine

**BREED**

Pit Bull Mix

**SEX**

Intact Male

**AGE**

7 Years

**WEIGHT**

79 Lbs.

**PRESENTING CLINICAL SIGNS**

History: recheck of aortic stenosis from echo 11/17/20

**ULTRASONOGRAPHIC EXAMINATION OF THE HEART**

CANINE CARDIAC PARAMETERS	MR VMAX (m/s)	TR VMAX (m/s)	LA/AO (Boon method)	LA/AO (Heart Base; Swe)	FS (%)	EF (%)	EPSS (cm)
<b>NORMAL PARAMETER</b>	4.5-5.5	<2.7	1.3	<1.6	28-40	40-100	<0.6
<b>PATIENT</b>	--	2.30	1.37	1.17	40	71	0.3
CANINE CARDIAC PARAMETERS	HR (BPM)	AV VMAX (m/s)	PV MAX (m/s)	BODY WEIGHT (kg)	LA 2D short axis Base view (cm)	LVIDd Avg; 2D and m-mode short axis (cm)	LVIDs Avg; 2D and m-mode short axis (cm)
<b>NORMAL PARAMETER</b>	50-100	0.7-1.7	0.7-1.6	BELOW	BELOW	BELOW	BELOW
<b>PATIENT</b>	143	3.57	2.0	--	3.89	4.28	--

**Cardiac Presentation**

The cardiac presentation in this patient presented mild left ventricular concentric hypertrophy with persistent increased left ventricular outflow velocity consistent with subaortic stenosis. Periodic arrhythmia noted in this patient. Internal diameters were normal. Right ventricular outflow tract velocity was upper limits of normal. Minor tricuspid insufficiency noted at 2.30 m/s. No pericardial or pleural effusion present. No therapy recommended at this time. Secondary aortic insufficiency also noted, similar to the prior sonogram.

**ULTRASONOGRAPHIC FINDINGS**

- Stable subaortic stenosis with occasional arrhythmia

**INTERPRETATION OF THE FINDINGS & FURTHER RECOMMENDATIONS**

EKG warranted. Holter monitor would be indicated if any exercise intolerance is an issue. Recheck echo in 6-12 months.

**INTERPRETED BY**

Eric Lindquist, DMV  
DABVP, Cert. IVUSS

**IMAGING PERFORMED BY**

Diane McFadden

**HOSPITAL NAME**

ACC Flanders

**REFERRING VET**

Dr. Hallihan

**INVOICE**

13201

**DATE**

12/28/21



**PATIENT**

Champ Alves

**SPECIES**

Canine

**BREED**

Pit Bull Mix

**SEX**

Intact Male

**AGE**

7 Years

**WEIGHT**

79 Lbs.

**INTERPRETED BY**

Eric Lindquist, DMV  
DABVP, Cert. IVUSS

**IMAGING PERFORMED BY**

Diane McFadden

**HOSPITAL NAME**

ACC Flanders

**REFERRING VET**

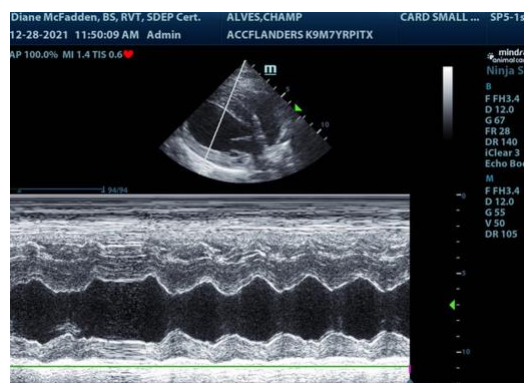
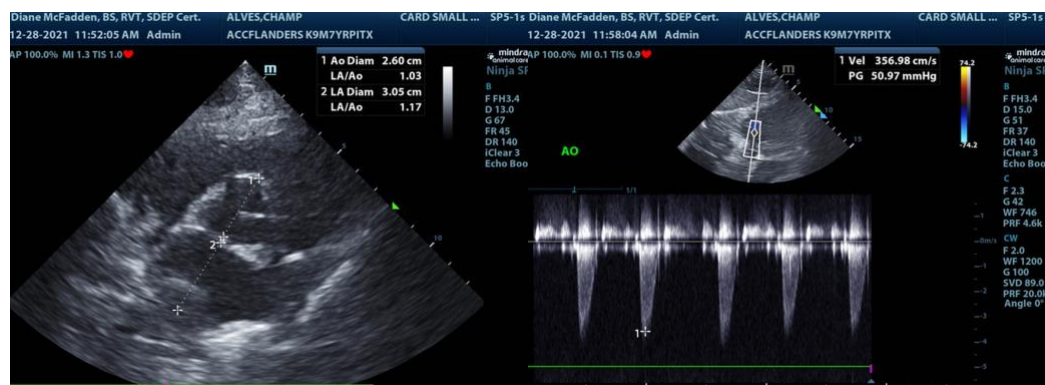
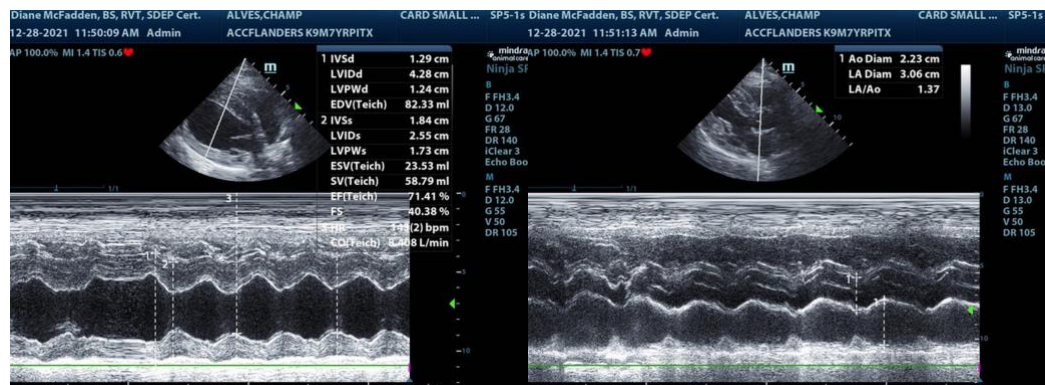
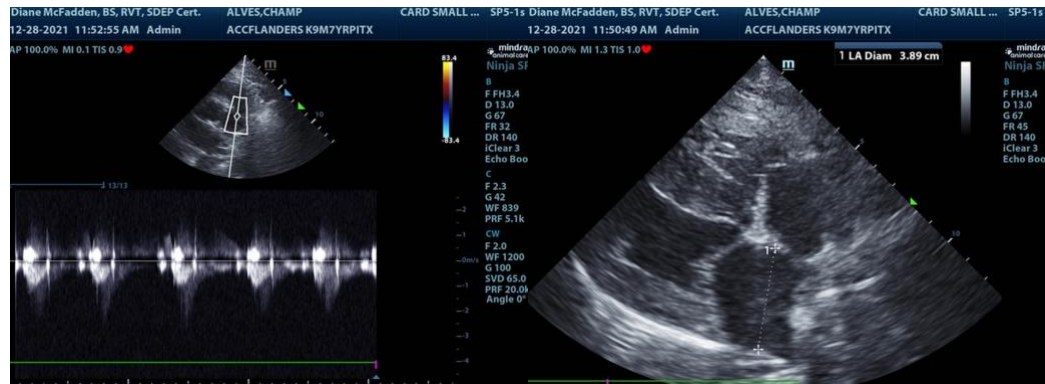
Dr. Hallihan

**INVOICE**

13201

**DATE**

12/28/21



The information and recommendations provided are based on the images presented by the referring veterinarian. No evaluation can be communicated regarding pathology that was not



**PATIENT**

visible in the image/video clips provided.

Champ Alves

Thank you for this referral. If the clinical or image interpretation does not parallel your findings or if I can be of any further assistance please contact me.

**SPECIES**

Canine

**Eric Lindquist**, DMV, DABVP, Cert. IVUSS, CEO of SonoPath.com  
info@SonoPath.com

**BREED**

Pit Bull Mix

**SEX**

Intact Male

**AGE**

7 Years

**WEIGHT**

79 Lbs.

**INTERPRETED BY**

Eric Lindquist, DMV  
DABVP, Cert. IVUSS

**IMAGING  
PERFORMED BY**

Diane McFadden

**HOSPITAL NAME**

ACC Flanders

**REFERRING VET**

Dr. Hallihan

**INVOICE**

13201

**DATE**

12/28/21