



<b>DATE</b>	<b>PRESENTING CLINICAL SIGNS</b>
12/27/22	Presented 12/20/2022 for a several week history of ADR, inappetence which had improved some by the time of the appointment. O's noticed abdomen looked larger. Main exam finding rotund abdomen with fluid wave. Current Medications: Triheart monthly.
<b>PATIENT</b>	Lab Results: blood chem and cbc largely wnl. Abdominal fluid aspirated straw colored slight blood tinge SP Gr 1.018/TS 3.3
Rhapsody Urbanski	Radiographs: Lack of serosal detail, fluid. Date of Previous IntraPet Ultrasound: No previous.
<b>SPECIES</b>	Sedation: Not required to complete full diagnostic ultrasound. Stat Report: Not requested.
Canine	Imaging Performed By: Rachel Brillhart, RDMS.
<b>BREED</b>	<b>ULTRASONOGRAPHIC EXAMINATION OF THE ABDOMEN</b>
Labrador Mix	<b>Urinary System</b>
<b>SEX</b>	The <b>urinary bladder</b> , trigone, and pelvic urethra presented normal thicknesses and normal tone. The ureters were not visible which is normal. No uroliths or sediment were visualized and anechoic urine was present. No evidence of inflammatory or neoplastic changes was noted. Ureteral papillae were normal.
Spayed female	The <b>kidneys</b> revealed largely normal size and structure, corticomedullary definition and ratio (cortex 1/3 of medulla) were essentially maintained with some age-related loss of curvilinear patterns regarding the capsule and C/M junction. The cortices presented largely uniform texture with some increased echogenicity expected for his age patient. Medullary structure differed distinctly from that of the cortex and no evidence of pelvic dilation was present. The right kidney measured 5.65 cm.
<b>AGE</b>	
3/24/12	
<b>WEIGHT</b>	
51 lbs	<b>Adrenal Glands</b>
<b>INTERPRETED BY</b>	Both <b>adrenal glands</b> were visualized and recognized as having normal shape, size, position and echogenicity for this breed. The phrenic vasculature, glandular echogenicity and detail were unremarkable. Capsule, cortex, and medullary definition were normal for this age patient. The right adrenal gland measured 2.28 x 0.57 cm at the caudal pole and 0.76 cm at the cranial pole.
Eric Lindquist, DMV DABVP, Cert. IVUSS	
<b>HOSPITAL NAME</b>	<b>Spleen</b>
Pleasantville AH	The <b>spleen</b> was heterogenous with mixed hyperechoic and hypoechoic nodular changes noted.
<b>REFERRING VET</b>	<b>Liver</b>
Dr. Gounaris	The <b>liver</b> revealed increased portal markings, coarse architecture and irregular contour. A hypoechoic, target type nodule was noted in the left lateral liver and measured 2.93 cm. Other heterogenous nodular changes were noted in the liver. The gallbladder and common bile duct were unremarkable.
<b>INVOICE</b>	<b>Gastrointestinal</b>
42383	Examination of the <b>gastrointestinal tract</b> revealed a stomach and intestine free of stasis, of normal wall thickness, acceptable curvilinear mural detail, and peristaltic activity. Small and large intestine demonstrated normal luminal chyme and stool consistency respectively. No obstructive or overt infiltrative disease was noted. No associated abnormal lymphatic activity was noted.
	<b>Pancreas</b>
	The <b>pancreas</b> was largely. However, minor, heterogenous parenchymal changes were noted.

### Free Abdomen

A large amount of free fluid was noted in the abdomen.

### Heart

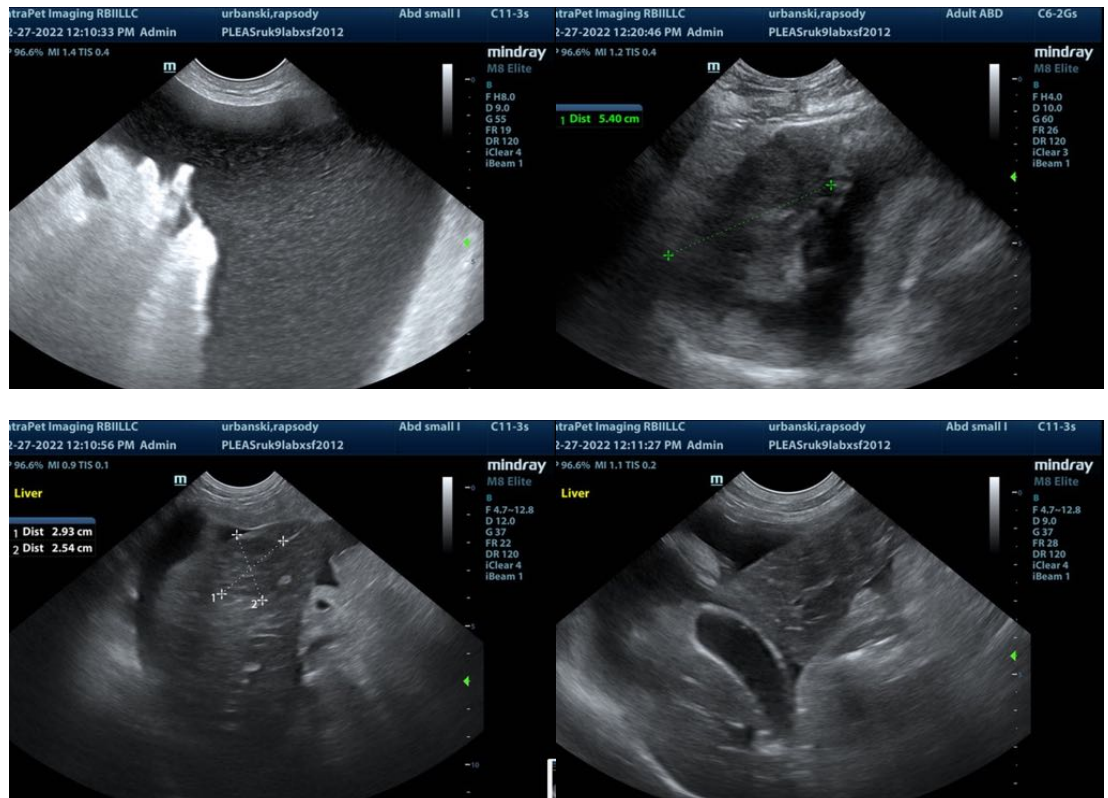
Rapid view of the heart revealed a muscle based mass in the right ventricle and right ventricular septum and free wall. This is strongly suggestive for sarcomatous change. The mass measured up to 5.0 cm. No pericardial effusion was noted.

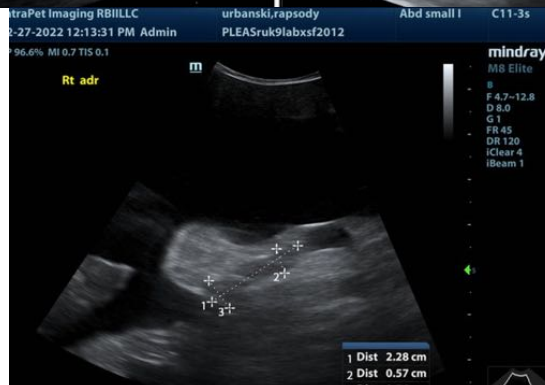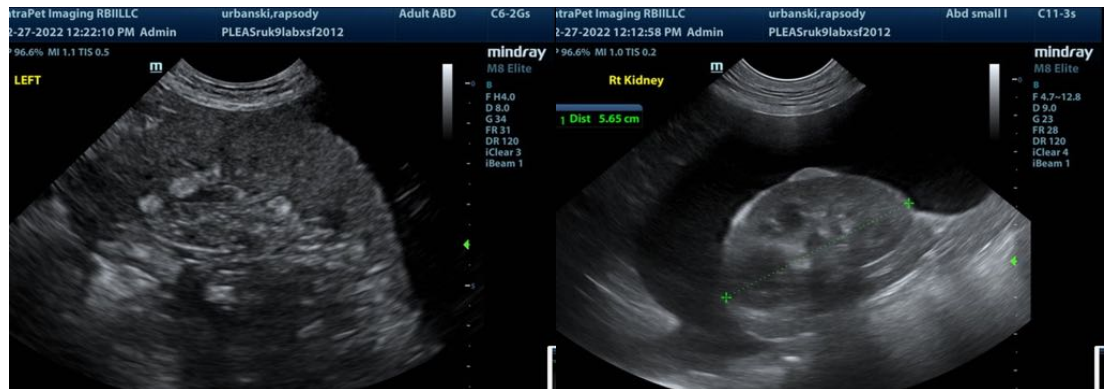
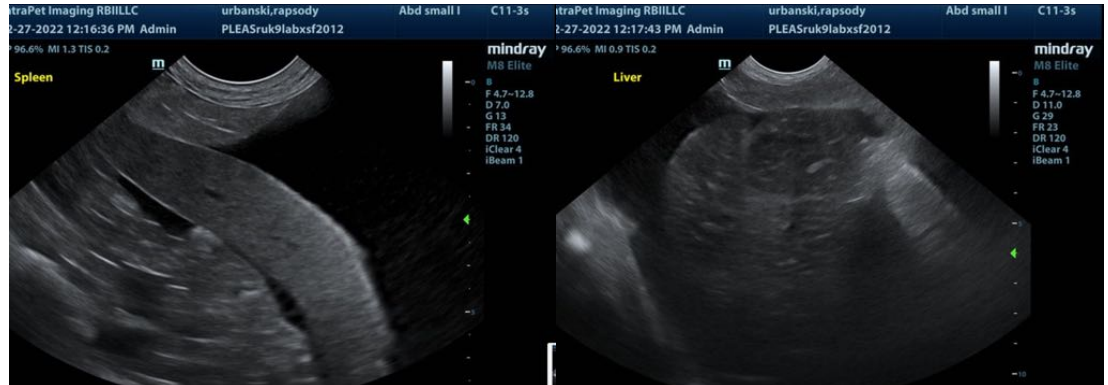### ULTRASONOGRAPHIC FINDINGS

Abdominal sarcomatosis type presentation with hepatic nodules and concurrent right ventricular mass. Heterogenous pancreatic changes.

### INTERPRETATION OF THE FINDINGS & FURTHER RECOMMENDATIONS

Multi-centric sarcoma is suspected. FNA of the liver, cytospin of the free fluid in the abdomen may prove effective regarding definitive diagnosis with cytospin.





The information and recommendations provided are based on the images presented by the referring veterinarian. No evaluation can be communicated regarding pathology that was not visible in the image/video clips provided.

Thank you for this referral. If the clinical or image interpretation does not parallel your findings or if I can be of any further assistance please contact me.

**Eric Lindquist**, DMV, DABVP, Cert. IVUSS, CEO of SonoPath.com  
 Eric.Lindquist@SonoPath.com