



PATIENT

Nino Barrios

PRESENTING CLINICAL SIGNS

History: vomiting yellow bile, lethargic panting

SPECIES

Canine

ULTRASONOGRAPHIC EXAMINATION OF THE ABDOMEN

Urinary System

BREED

Bichon Mix

The **urinary bladder**, trigone, and pelvic urethra presented normal thicknesses and normal tone. The ureters were not visible which is normal. No uroliths or sediment were visualized and anechoic urine was present. No evidence of inflammatory or neoplastic changes was noted. Ureteral papillae were normal.

SEX

Neutered male

The **kidneys** revealed largely normal size and structure, corticomedullary definition and ratio (cortex 1/3 of medulla) were essentially maintained with some age-related loss of curvilinear patterns regarding the capsule and C/M junction. The cortices presented largely uniform texture with some increased echogenicity expected for his age patient. Medullary structure differed distinctly from that of the cortex and no evidence of pelvic dilation was present. Mineralization was noted in the kidneys. The right kidney measured 4.3 cm.

AGE

13 years

WEIGHT

20 lbs

Adrenal Glands

Both **adrenal glands** were visualized and recognized as having normal shape, size, position and echogenicity for this breed. The phrenic vasculature, glandular echogenicity and detail were unremarkable. Capsule, cortex, and medullary definition were normal for this age patient. The right adrenal gland measured 1.84 x 0.67 cm at the cranial pole and 0.48 cm at the caudal pole. The left adrenal gland measured 1.38 x 0.34 cm at the caudal pole and 0.64 cm at the cranial pole.

INTERPRETED BY

Eric Lindquist, DMV
DABVP, Cert. IVUSS

IMAGING PERFORMED BY

Jenn

Spleen

The **spleen** presented a smooth homogeneous parenchyma hyperechoic to liver and renal cortical parenchyma. The capsule was smooth without noticeable expansion or deviation from within the spleen or adjacent pathology. The splenic vasculature demonstrated normal volume without signs of congestion or thrombosis. No sonographic evidence of acute or chronic inflammatory, neoplastic, or infarctual changes was noted.

HOSPITAL NAME

Rockaway

REFERRING VET

Dr. Maniar

Liver

The **liver** images from right and left intercostal as well as subcostal views revealed subjectively normal liver size, contour, and structure. Some age-related parenchymal remodeling was noted but likely not clinically significant at this time. Vascular and biliary tracts were of normal volume and no evidence of congestion was noted. The gallbladder presented some dependent debris with essentially normal contour. The cystic and common bile ducts were normal. No overt evidence of active inflammatory, infiltrative or regenerative pathology was noted but should be paired with current or past LE elevations regarding any clinical significance to this presentation. The hepatic lymph nodes were unremarkable.

INVOICE

42364

DATE

12/27/22



PATIENT

Gastrointestinal

Nino Barrios

The **stomach** revealed a minor amount of fluid filled lumen with an edematous gastric wall. There was no evidence of foreign bodies. The small intestines and colon were unremarkable.

SPECIES

Canine

Pancreas

BREED

Bichon Mix

The base and limbs of the **pancreas** were observed to be largely isoechoic to surrounding omental fat. Pancreatic duct and capsular contour were acceptably normal and parenchyma respected normal curvilinear patterns. No overt evidence of active inflammatory or neoplastic disease was noted.

SEX

Neutered male

ULTRASONOGRAPHIC FINDINGS

Geriatric abdomen.

Mild gastritis pattern.

AGE

13 years

Otherwise, unremarkable abdomen.

WEIGHT

20 lbs

INTERPRETATION OF THE FINDINGS & FURTHER RECOMMENDATIONS

A clinical trial of the following may prove effective.

Helicobacter/Gastritis protocol

A clinical trial of **Zithromax (Dogs: 5-10 mg/kg p.o. q24h. May increase dosing interval to q48h after 3-5 days of treatment)**, **Metronidazole (10-20 mg/kg p.o. b.i.d.)**, **Pepcid (0.5-1 mg/kg s.i.d.)** and **Sucralfate (0.5-2 g/dog PO)** or **Omeprazole (1 mg/kg p.o. s.i.d.)** over the next 3 weeks along with a **novel-protein or hydrolyzed diet** with slurry feeding b.i.d./t.i.d. over the next 2-4 days and then increase to canned diet bid. Dry food should be avoided over the next 4 weeks. A recheck sonogram to assess GI improvement or progression would be ideal in 4 weeks.

INTERPRETED BY

Eric Lindquist, DMV
DABVP, Cert. IVUSS

IMAGING PERFORMED BY

Jenn

HOSPITAL NAME

Rockaway

REFERRING VET

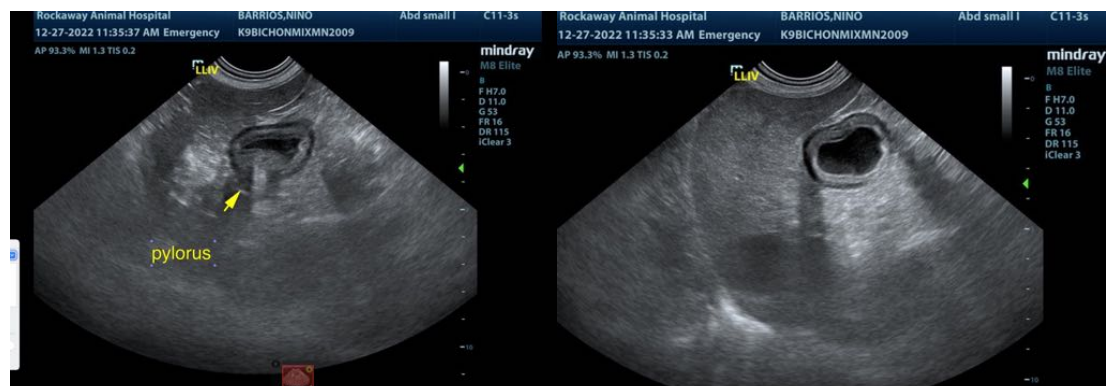
Dr. Maniar

INVOICE

42364

DATE

12/27/22





PATIENT

Nino Barrios

SPECIES

Canine

BREED

Bichon Mix

SEX

Neutered male

AGE

13 years

WEIGHT

20 lbs

INTERPRETED BY

Eric Lindquist, DMV
DABVP, Cert. IVUSS

IMAGING PERFORMED BY

Jenn

HOSPITAL NAME

Rockaway

REFERRING VET

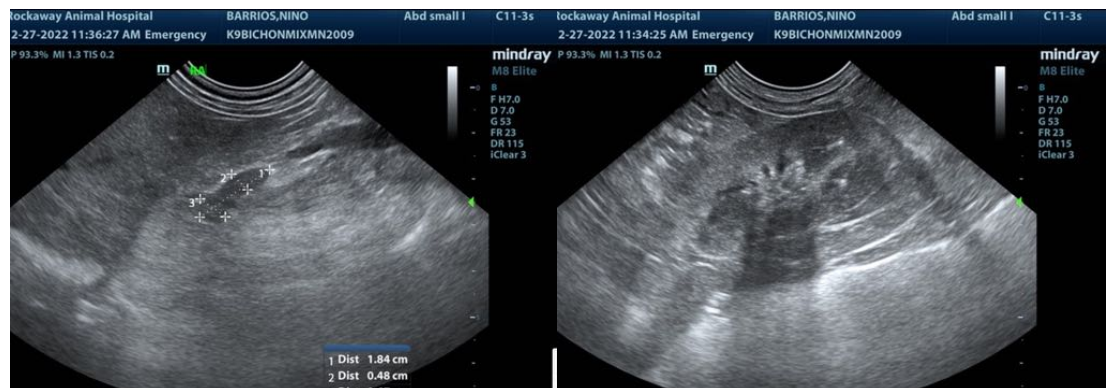
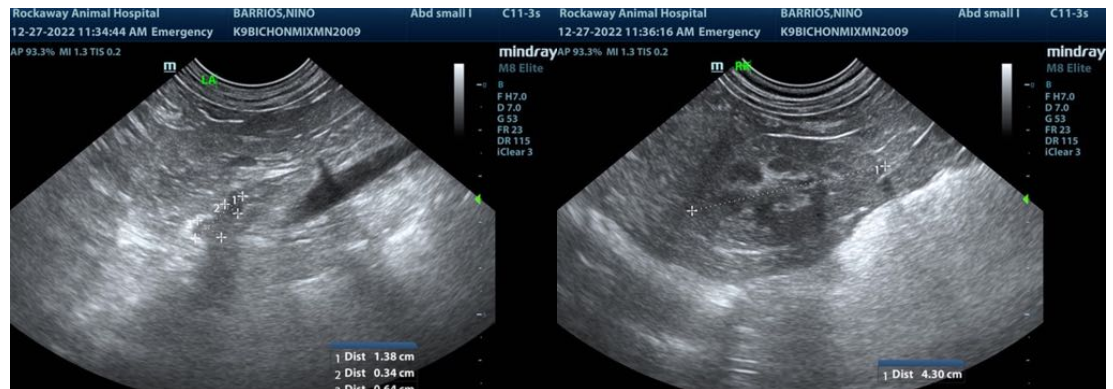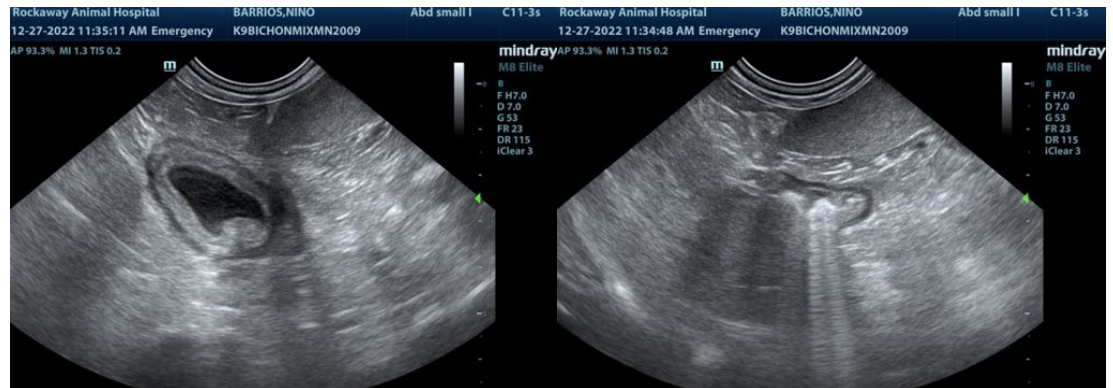
Dr. Maniar

INVOICE

42364

DATE

12/27/22



The information and recommendations provided are based on the images presented by the referring veterinarian/sonographer. No evaluation can be communicated regarding pathology that was not visible in the image/video clips provided.

Thank you for this referral. If the clinical or image interpretation does not parallel your findings or if I can be of any further assistance please contact me.

Eric Lindquist, DMV, DABVP, Cert. IVUSS, CEO of SonoPath.com
info@SonoPath.com