



PATIENT

Dexter Webb

SPECIES

Feline

BREED

Russian Blue

SEX

Neutered male

AGE

5 years

WEIGHT

14 lbs

INTERPRETED BY

Eric Lindquist, DMV
DABVP, Cert. IVUSS

IMAGING PERFORMED BY

Dr. Treat

HOSPITAL NAME

Green Mountain VH

REFERRING VET

Dr. Treat

INVOICE

42368

DATE

12/27/22

PRESENTING CLINICAL SIGNS

History: Dec 26th present vomiting for 2 days. Owner thought it may have eaten part of the Christmas tree. It wanted to eat but was vomiting. It was still presented BAR. Very little abdominal discomfort upon palpation. Was treated with sub q fluids and cerenia injection. Dec 27th present lethargic, painful, inappetent, urinating but no producing stool. Abdominal ultrasound cat produced gas and diarrhea.

ULTRASONOGRAPHIC EXAMINATION OF THE ABDOMEN

Urinary System

The **urinary bladder**, trigone, and pelvic urethra presented normal thicknesses and normal tone. The ureters were not visible which is normal. No uroliths or sediment were visualized and anechoic urine was present. No evidence of inflammatory or neoplastic changes was noted. Ureteral papillae were normal.

The **kidneys** revealed normal size and structure, corticomedullary definition and ratio for this age. The cortices presented largely uniform texture with normal echogenic relationship to liver and spleen. Medullary structure differed distinctly from the cortex and no evidence of pelvic dilation was present. The capsules were acceptably uniform without significant irregularities. The kidneys measured 3.5 cm.

Adrenal Glands

Both **adrenal glands** were visualized and recognized as having normal shape, size, position and echogenicity for this breed. The phrenic vasculature, glandular echogenicity and detail were unremarkable. Capsule, cortex, and medullary definition were normal for this age patient.

Spleen

The **spleen** presented a smooth homogeneous parenchyma hyperechoic to liver and renal cortical parenchyma. The capsule was smooth without noticeable expansion or deviation from within the spleen or adjacent pathology. The splenic vasculature demonstrated normal volume without signs of congestion or thrombosis. No sonographic evidence of acute or chronic inflammatory, neoplastic, or infarctual changes was noted. The spleen measured 0.7 cm.

Liver

The **liver** images submitted revealed subjectively normal liver size, contour, and structure. Parenchymal echogenicity was naturally coarse and hypoechoic to the spleen. Vascular and biliary tracts were of normal volume with no evidence of congestion. The gallbladder presented acceptably thin walls with primarily anechoic content. The cystic and common bile ducts were normal. No pathological hepatic lymphadenopathy was evident. No overt structural evidence of inflammatory, infiltrative or regenerative pathology was evident.



PATIENT

Dexter Webb

SPECIES

Feline

BREED

Russian Blue

SEX

Neutered male

AGE

5 years

WEIGHT

14 lbs

INTERPRETED BY

Eric Lindquist, DMV
DABVP, Cert. IVUSS

IMAGING PERFORMED BY

Dr. Treat

HOSPITAL NAME

Green Mountain VH

REFERRING VET

Dr. Treat

INVOICE

42368

DATE

12/27/22

Gastrointestinal

The **gastrointestinal** presentation revealed mild uniform prominence of the gastric mucosa as well as areas of "ropey" small intestinal wall with slight disruption of the normal 1:3 muscularis/mucosal ratio. The intestinal submucosa was slightly irregular, thickened and hyperechoic suggestive of low grade, chronic disease. No concerning lymphadenopathy was visible. No evidence of obstruction was present. Chronic inflammatory bowel disease is likely with a low possibility of an early neoplastic event such as lymphoma. Full thickness tissue biopsies via open laparotomy, ideally guided by intraoperative ultrasound in order to obtain the most representative mural sample, would be necessary to rule out this possibility.

Pancreas

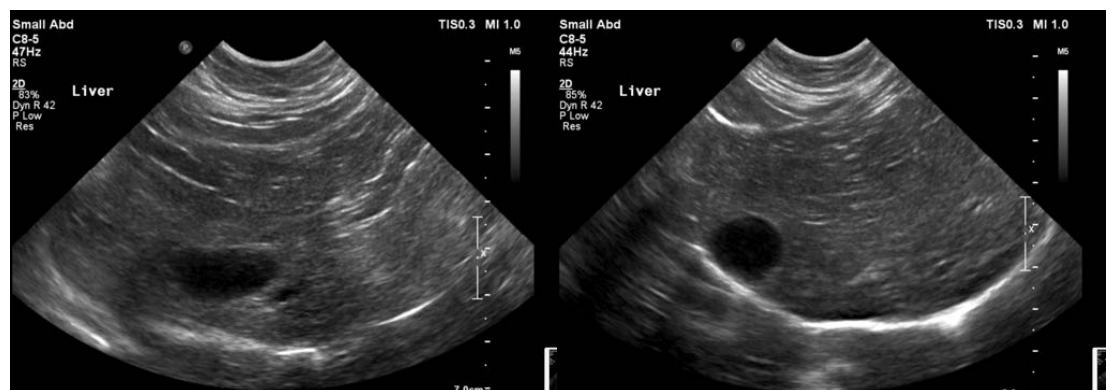
The base and limbs of the **pancreas** were observed to be largely isoechoic to surrounding omental fat. Pancreatic duct and capsular contour were acceptably normal and parenchyma respected normal curvilinear patterns. No overt evidence of active inflammatory or neoplastic disease was noted.

ULTRASONOGRAPHIC FINDINGS

Minor intestinal thickening. No neoplastic criteria or foreign bodies were noted.

INTERPRETATION OF THE FINDINGS & FURTHER RECOMMENDATIONS

Underlying inflammatory bowel, occult parasitism and dietary intolerance is all possible. Supportive care should prove effective.





PATIENT

Dexter Webb

SPECIES

Feline

BREED

Russian Blue

SEX

Neutered male

AGE

5 years

WEIGHT

14 lbs

INTERPRETED BY

Eric Lindquist, DMV
DABVP, Cert. IVUSS

IMAGING PERFORMED BY

Dr. Treat

HOSPITAL NAME

Green Mountain VH

REFERRING VET

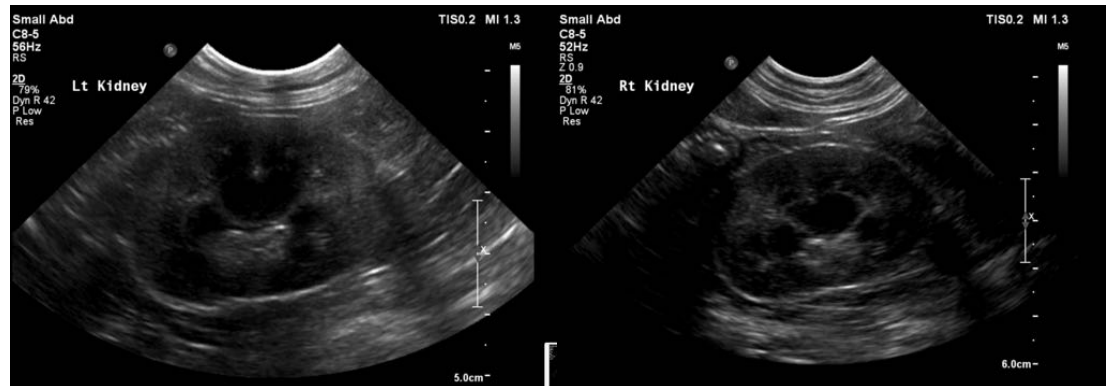Dr. Treat

INVOICE

42368

DATE

12/27/22



The information and recommendations provided are based on the images presented by the referring veterinarian/sonographer. No evaluation can be communicated regarding pathology that was not visible in the image/video clips provided.

Thank you for this referral. If the clinical or image interpretation does not parallel your findings or if I can be of any further assistance please contact me.

Eric Lindquist, DMV, DABVP, Cert. IVUSS, CEO of SonoPath.com
info@SonoPath.com