

IMAGING PERFORMED BY

IntraPet.com



**SonoPath**

Clinical Sonography & Telemetry

EDUCATIONAL TELECONSULTATION SERVICES™

1-800-838-4268 info@sonopath.com SonoPath.com

**DATE PRESENTING CLINICAL SIGNS**

12/27/21

History: Patient has a soft mass present on the later right abdomen, it feels deeper than the skin/dermal layer. Is the mass within the abdomen? Is the mass attached to an organ?

**PATIENT**

Max Schaefer

Lab Results: NSF.  
Date of Previous IntraPet Ultrasound: 9-18-2019 (Echo).  
Sedation: Gabapentin, Trazadone.  
Stat Report: Not requested.

**SPECIES**

Canine

**BREED**

Beagle

**SEX**

Neutered Male

**AGE**

10/1/13

**WEIGHT**

39 Pounds

**INTERPRETED BY**

Eric Lindquist, DMV  
DABVP, Cert. IVUSS

**IMAGING PERFORMED BY**

Rachel Brilhart RDMS

**HOSPITAL NAME**

BPH of Timonoum

**REFERRING VET**

Dr. Borrison

**INVOICE**

33736

**ULTRASONOGRAPHIC EXAMINATION OF THE ABDOMEN**

**Urinary System**

The **urinary bladder**, trigone, and pelvic urethra presented normal thicknesses and normal tone. The ureters were not visible which is normal. No uroliths or sediment were visualized and anechoic urine was present. No evidence of inflammatory or neoplastic changes were noted. Ureteral papillae were normal.

The **kidneys** revealed largely normal size and structure, corticomedullary definition and ratio (cortex 1/3 of medulla) were essentially maintained with some age-related loss of curvilinear patterns regarding the capsule and C/M junction. The cortices presented largely uniform texture with some increased echogenicity expected for his age patient. Medullary structure differed distinctly from that of the cortex and no evidence of pelvic dilation was present. The right kidney measured 5.55 cm. The left kidney measured 5.19 cm.

**Adrenal Glands**

Both **adrenal glands** were visualized and recognized as having normal shape, size, position and echogenicity for this breed. The phrenic vasculature, glandular echogenicity and detail were unremarkable. Capsule, cortex, and medullary definition were normal for this age patient. The left adrenal gland measured 2.46 cm x 0.59 cm at the caudal pole and 0.54 cm at the cranial pole. The right adrenal gland measured 2.53 cm x 0.73 cm at the caudal pole and 0.83 cm at the cranial pole.

**Spleen**

The **spleen** presented a smooth homogeneous parenchyma hyperechoic to liver and renal cortical parenchyma. The capsule was smooth without noticeable expansion or deviation from within the spleen or adjacent pathology. The splenic vasculature demonstrated normal volume without signs of congestion or thrombosis. No sonographic evidence of acute or chronic inflammatory, neoplastic, or infarctual changes were noted.

**Liver**

The **liver** images submitted revealed subjectively normal liver size, contour, and structure. Parenchymal echogenicity was naturally coarse and hypoechoic to the spleen. Vascular and biliary tracts were of normal volume with no evidence of congestion. The gallbladder presented acceptably thin walls with primarily anechoic content. The cystic and common bile ducts were normal. No pathological hepatic lymphadenopathy was evident. No overt structural evidence of inflammatory, infiltrative or regenerative pathology was evident.

**Gastrointestinal**

Minor retention of ingesta noted in the **stomach**. The small intestine and colon were unremarkable.

## Pancreas

The base and limbs of the **pancreas** were observed to be largely isoechoic to surrounding omental fat. Pancreatic duct and capsular contour were acceptably normal and parenchyma respected normal curvilinear patterns. No overt evidence of active inflammatory or neoplastic disease was noted.

## Free Abdomen

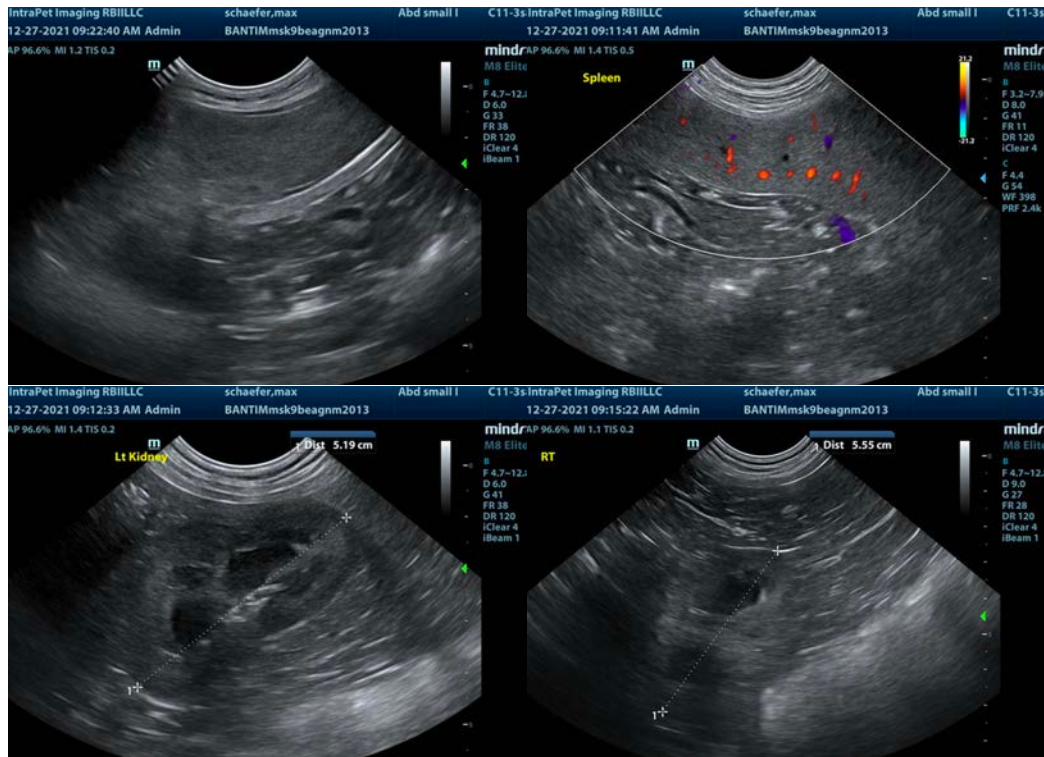
A 5.6 cm x 2.37 cm subcutaneous body wall mass was noted in this patient, isoechoic to surrounding fat. A large amount of abdominal fat noted in this patient.

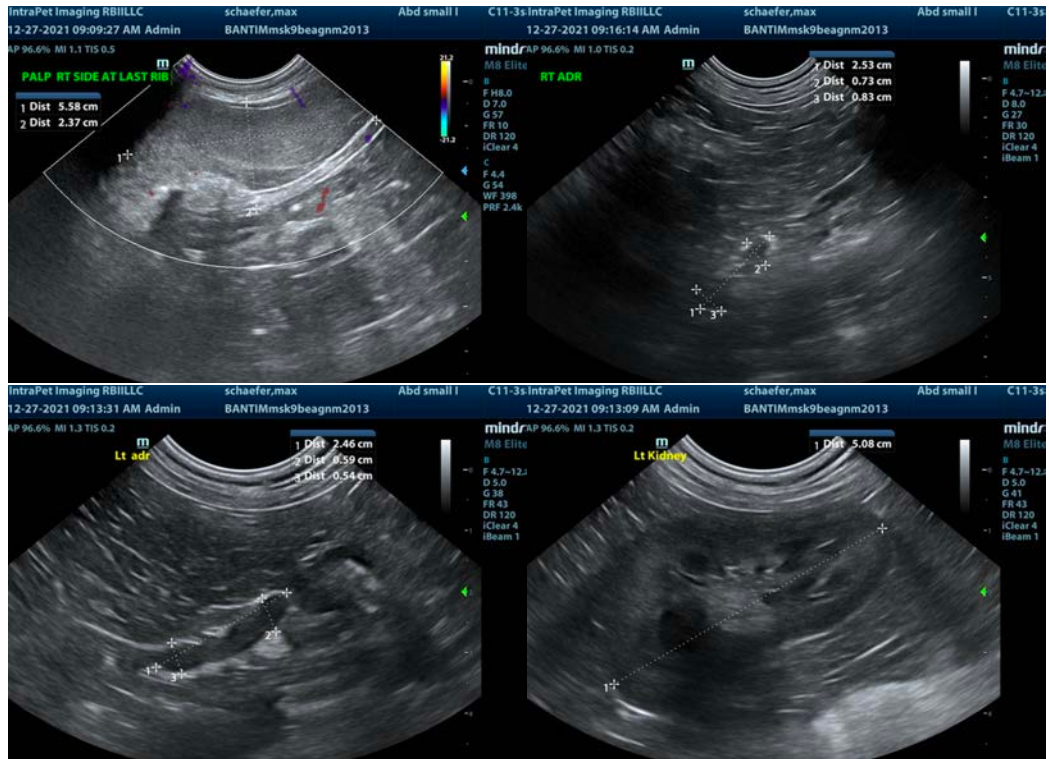
## ULTRASONOGRAPHIC FINDINGS

- Right body wall mass – organized lipoma suspected, possibility of sarcoma.
- Unremarkable abdomen otherwise

## INTERPRETATION OF THE FINDINGS & FURTHER RECOMMENDATIONS

The mass appears potentially resectable and does not encroach upon the peritoneum. It is fairly well organized and encapsulated. Ultrasound guided FNA performed without complication.





The information and recommendations provided are based on the images presented by the referring veterinarian. No evaluation can be communicated regarding pathology that was not visible in the image/video clips provided.

Thank you for this referral. If the clinical or image interpretation does not parallel your findings or if I can be of any further assistance please contact me.

**Eric Lindquist**, DMV, DABVP, Cert. IVUSS, CEO of SonoPath.com  
[info@SonoPath.com](mailto:info@SonoPath.com)