

PATIENT

Cooper Avery

SPECIES

Canine

BREED

Mixed

SEX

Neutered Male

AGE

5 Years

WEIGHT

59.7 Lbs.

INTERPRETED BY

Eric Lindquist, DMV
DABVP, Cert. IVUSS

IMAGING PERFORMED BY

John Ammeraal, DVM

HOSPITAL NAME

Sova

REFERRING VET

John Ammeraal, DVM

PRESENTING CLINICAL SIGNS

History: Urinating blood for a month. Owner brought in for exam today R/O TCC vs blood clots
Abnormal PE/Chem/CBC/UA Results: BCS 7/9 , UA- Pending.

LIMITED ULTRASONOGRAPHIC EXAMINATION

The **urinary bladder** revealed multifocal polypoid changes coalescing into eventual cranial mass, measuring 3 cm. Dorsal polyps were noted as well and concentric thickening continuing into the pelvic urethra. The pattern is most consistent with severe cystitis; however, carcinoma cannot be completely ruled out.

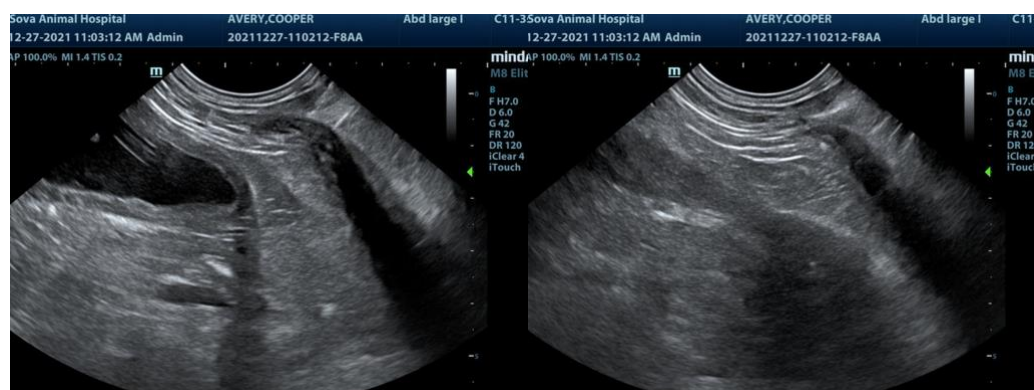The **kidneys** revealed normal size and structure, corticomedullary definition and ratio for this age. The cortices presented largely uniform texture with normal echogenic relationship to liver and spleen. The capsules were acceptably uniform without significant irregularities. The renal pelvises were slightly dilated in both kidneys with echogenic debris. The left kidney measured 7.24 cm. The right kidney measured 7.24 cm.

ULTRASONOGRAPHIC FINDINGS

- Undefined polypoid bladder mass possible. Strong potential for chronic cystitis and polypoid hyperplasia. Possibility of carcinoma.

INTERPRETATION OF THE FINDINGS & FURTHER RECOMMENDATIONS

Ultrasound guided traumatic catheterization with cytology is recommended and culture or exploratory surgery could be considered with ablation of the cranial half of the urinary bladder. However, this may not resect the entire pathology as mural changes were present in the mid bladder. The pyelectasia in the kidneys may be owing to scarring or possible embedded infection. Prognosis is guarded.



INVOICE

13155

DATE

12/27/21



PATIENT

Cooper Avery

SPECIES

Canine

BREED

Mixed

SEX

Neutered Male

AGE

5 Years

WEIGHT

59.7 Lbs.

INTERPRETED BY

Eric Lindquist, DMV
DABVP, Cert. IVUSS

IMAGING PERFORMED BY

John Ammeraal, DVM

HOSPITAL NAME

Sova

REFERRING VET

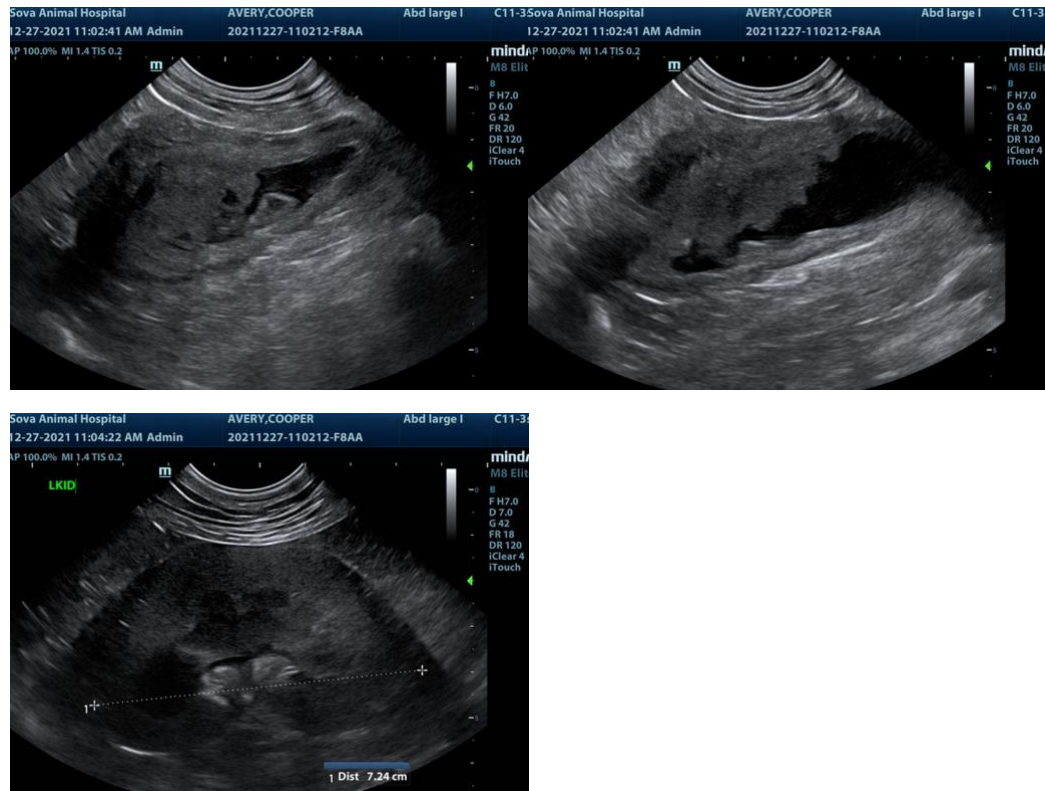
John Ammeraal, DVM

INVOICE

13155

DATE

12/27/21



The information and recommendations provided are based on the images presented by the referring veterinarian. No evaluation can be communicated regarding pathology that was not visible in the image/video clips provided.

Thank you for this referral. If the clinical or image interpretation does not parallel your findings or if I can be of any further assistance please contact me.

Eric Lindquist, DMV, DABVP, Cert. IVUSS, CEO of SonoPath.com
info@SonoPath.com