



PATIENT

Niki Whitaker

SPECIES

Canine

BREED

Mixed

SEX

Spayed Female

AGE

13 Years 4 Months

WEIGHT

N/A

INTERPRETED BY

Eric Lindquist, DMV,
DABVP (CFM), Cert.
IVUSS

IMAGING PERFORMED BY

Vincent Ravancho, CVT

HOSPITAL NAME

Packanack AH

REFERRING VET

Dr. Gonzaga

INVOICE

35091

DATE

12/26/25

PRESENTING CLINICAL SIGNS

History: H/O biliary sludge/debris; H/O chronic renal changes Current medications: Galliprant 60mg 1T SID, Ursodial 250mg, 1.5T SID, Adequan monthly, Pepcid 10-20mg SID, Cobalequin, Hepato, Osteo, Fiber, Naraquin, Provable.

Abnormal PE/Chem/CBC/UA Results: From September 2025, ALP 337, BUN 33, Creat 1.9, SDMA 15.1 USG 1.016.

ULTRASONOGRAPHIC EXAMINATION OF THE ABDOMEN

Urinary System

The **urinary bladder**, trigone, and pelvic urethra presented normal thicknesses and normal tone. The ureters were not visible which is normal. No uroliths or sediment were visualized and anechoic urine was present. No evidence of inflammatory or neoplastic changes was noted. Ureteral papillae were normal. The pelvic urethra was imaged 2.0 cm beyond the cystourethral junction.

The **kidneys** revealed normal size and structure, corticomedullary definition and ratio for this age. The cortices presented largely uniform texture with normal echogenic relationship to liver and spleen. Medullary structure differed distinctly from the cortex, and no evidence of pelvic dilation was present. The capsules were acceptably uniform without significant irregularities. The right kidney measured 5.1 cm. The left kidney measured 4.7 cm. Blood flow to the kidneys was mildly subnormal.

Adrenal Glands

Both **adrenal glands** were visualized and recognized as having normal shape, size, position and echogenicity for this breed. The phrenic vasculature, glandular echogenicity and detail were unremarkable. Capsule, cortex, and medullary definition were normal for this age patient. The right adrenal gland measured 1.43 cm x 0.58 cm at the cranial pole and 0.65 cm at the caudal pole. The left adrenal gland measured 2.4 cm x 0.65 cm at the caudal pole and 0.53 cm at the cranial pole.

Spleen

The **spleen** presented a smooth homogeneous parenchyma hyperechoic to liver and renal cortical parenchyma. The capsule was smooth without noticeable expansion or deviation from within the spleen or adjacent pathology. The splenic vasculature demonstrated normal volume without signs of congestion or thrombosis. No sonographic evidence of acute or chronic inflammatory, neoplastic, or infarctual changes were noted. Caudal folding of the spleen was noted.

Liver

The **liver** images from right and left intercostal as well as subcostal views revealed subjectively normal liver size, contour, and structure. Some moderate age-related parenchymal remodeling was noted but likely not clinically significant at this time. Vascular and biliary tracts were of normal volume, and no evidence of congestion was noted. The gallbladder presented some dependent debris with essentially normal contour. The cystic and common bile ducts were normal. A history of inflammatory hepatopathy is likely. The hepatic lymph nodes were unremarkable.

Gastrointestinal



PATIENT

Niki Whitaker

SPECIES

Canine

BREED

Mixed

SEX

Spayed Female

AGE

13 Years 4 Months

WEIGHT

N/A

INTERPRETED BY

Eric Lindquist, DMV,
DABVP (CFM), Cert.
IVUSS

IMAGING PERFORMED BY

Vincent Ravancho, CVT

HOSPITAL NAME

Packanack AH

REFERRING VET

Dr. Gonzaga

INVOICE

35091

DATE

12/26/25

Examination of the **gastrointestinal tract** revealed a stomach and intestine free of stasis, of normal wall thickness, acceptable curvilinear mural detail, and peristaltic activity. Small and large intestine demonstrated normal luminal chyme and stool consistency respectively. No obstructive or overt infiltrative disease was noted. No associated abnormal lymphatic activity was noted.

Pancreas

The base and limbs of the **pancreas** were observed to be largely isoechoic to surrounding omental fat. Pancreatic duct and capsular contour were acceptably normal and parenchyma respected normal curvilinear patterns. No overt evidence of active inflammatory or neoplastic disease was noted.

ULTRASONOGRAPHIC FINDINGS

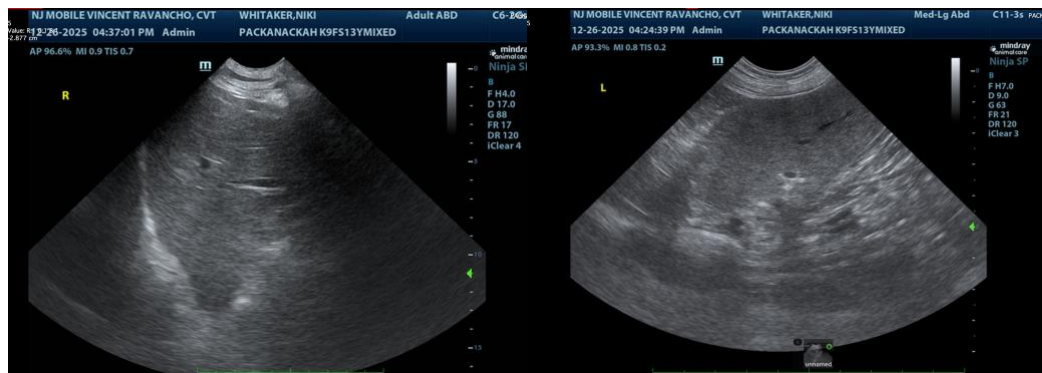
- Moderate degenerative renal changes
- Moderate degenerative hepatic changes

INTERPRETATION OF THE FINDINGS & FURTHER RECOMMENDATIONS

The kidneys are not end-stage from a subjective standpoint. Complicating factors, such as UTI, hypertension, infectious agents or toxin exposure should all be considered in this patient and investigated.

For an additional charge, internal medicine consult can be utilized through SonoPath.com. You can select the internal medicine drop down at <http://spa.sonopath.com/>.

One of the world's top internists & SonoPath associate Dr. Remo Lobetti BVSc, MMedVet, PhD, DECVIM can evaluate your case through SonoPath. <https://sonopath.com/resources/sonopath-services/internal-medicine-teleconsultation-services>





PATIENT

Niki Whitaker

SPECIES

Canine

BREED

Mixed

SEX

Spayed Female

AGE

13 Years 4 Months

WEIGHT

N/A

INTERPRETED BY

Eric Lindquist, DMV,
 DABVP (CFM), Cert.
 IVUSS

IMAGING PERFORMED BY

Vincent Ravancho, CVT

HOSPITAL NAME

Packanack AH

REFERRING VET

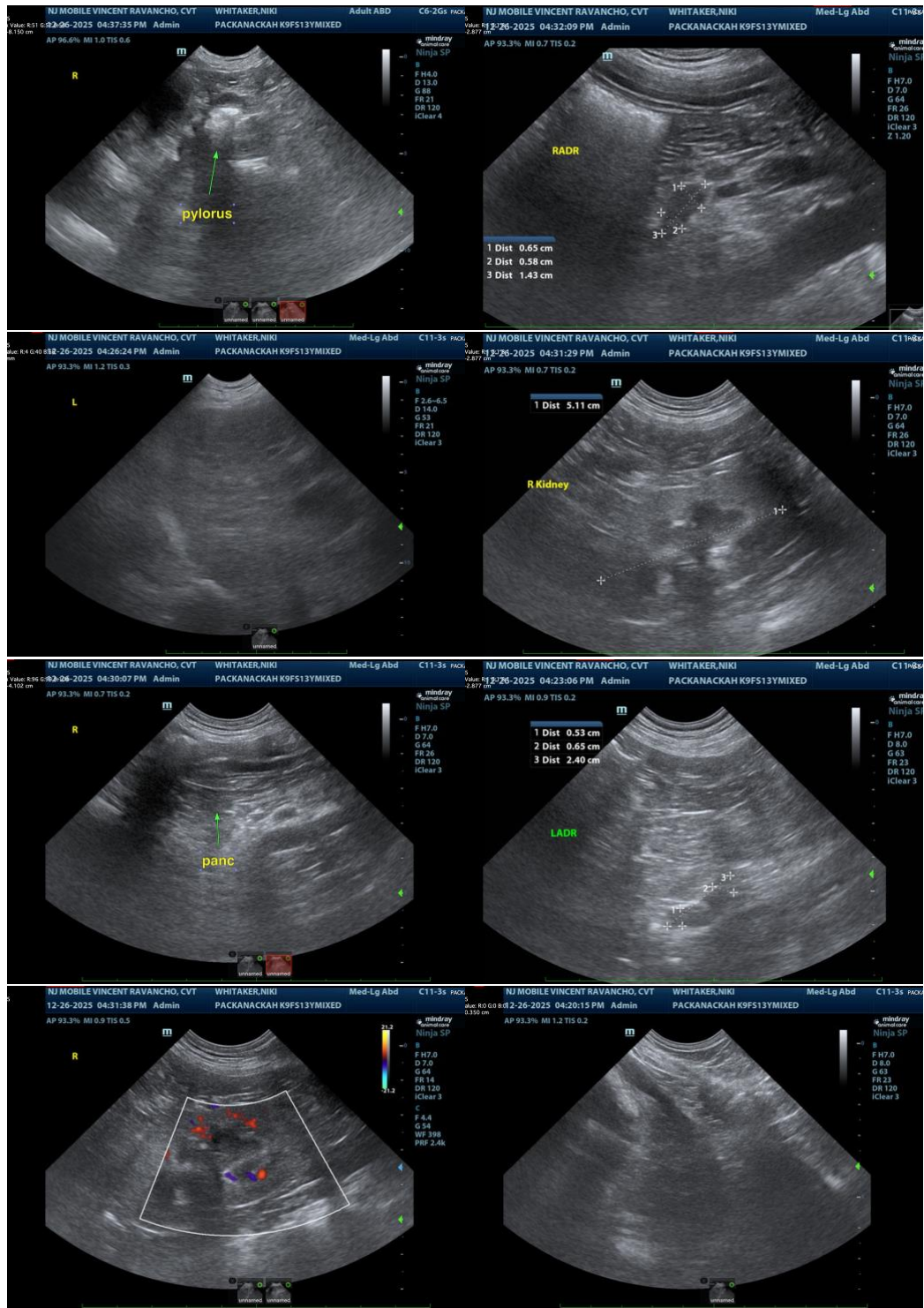
Dr. Gonzaga

INVOICE

35091

DATE

12/26/25





PATIENT

Niki Whitaker

SPECIES

Canine

BREED

Mixed

SEX

Spayed Female

AGE

13 Years 4 Months

WEIGHT

N/A

INTERPRETED BY

Eric Lindquist, DMV,
DABVP (CFM), Cert.
IVUSS

**IMAGING
PERFORMED BY**

Vincent Ravancho, CVT

HOSPITAL NAME

Packanack AH

REFERRING VET

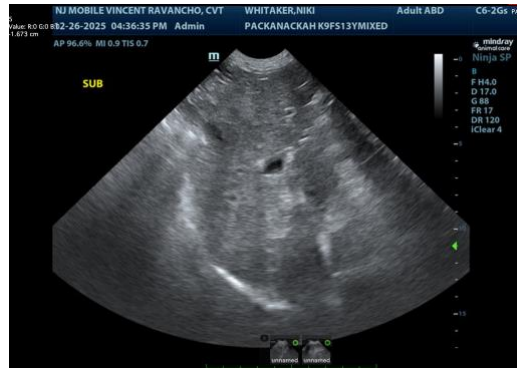Dr. Gonzaga

INVOICE

35091

DATE

12/26/25



The information and recommendations provided are based on the images presented by the referring veterinarian/sonographer. No evaluation can be communicated regarding pathology that was not visible in the image/video clips provided.

Thank you for this referral. If the clinical or image interpretation does not parallel your findings or if I can be of any further assistance please contact me.

Eric Lindquist, DMV, DABVP(CFM), Cert. IVUSS,
CEO, Owner, Founder -- SonoPath.com
info@SonoPath.com