



**PATIENT**

Leonidas Francis

**SPECIES**

Canine

**BREED**

Cockapoo

**SEX**

Neutered Male

**AGE**

12 Years 4 Months

**WEIGHT**

29 Pounds

**INTERPRETED BY**

Eric Lindquist, DMV,  
DABVP(CFM), Cert.  
IVUSS

**IMAGING PERFORMED BY**

Vincent Ravancho, CVT

**HOSPITAL NAME**

Summit Dog and Cat  
Hospital

**REFERRING VET**

Dr. Baker

**INVOICE**

35088

**DATE**

12/26/25

**PRESENTING CLINICAL SIGNS**

History: Hepatomegaly noted Clinical findings: Increased ALKP (329), 18,800 WBC Current medications: Librela inj monthly, 50mg Trazodone For FNA: 47% HCT, 636 PLT Abnormal PE/Chem/CBC/UA Results: Increased ALKP (329), 18,800 WBC.

**ULTRASONOGRAPHIC EXAMINATION OF THE ABDOMEN**

**Urinary System**

The **urinary bladder**, trigone, and pelvic urethra presented normal thicknesses and normal tone. The ureters were not visible which is normal. No uroliths or sediment were visualized and anechoic urine was present. No evidence of inflammatory or neoplastic changes was noted. Ureteral papillae were normal. The pelvic urethra was imaged 2.0 cm beyond the cystourethral junction. The residual prostate measured 0.9 cm.

The **kidneys** revealed normal size and structure, corticomedullary definition and ratio for this age. The cortices presented largely uniform texture with normal echogenic relationship to liver and spleen. Medullary structure differed distinctly from the cortex, and no evidence of pelvic dilation was present. The capsules were acceptably uniform without significant irregularities. The right kidney measured 5.33 cm. The left kidney measured 4.78 cm.

**Adrenal Glands**

Both **adrenal glands** were visualized and recognized as having normal shape, size, position and echogenicity for this breed. The phrenic vasculature, glandular echogenicity and detail were unremarkable. Capsule, cortex, and medullary definition were normal for this age patient. The left adrenal gland measured 1.7 cm x 0.6 cm at the cranial pole and 0.56 cm at the caudal pole. The right adrenal gland measured 1.56 cm x 1.16 cm at the cranial pole and 0.61 cm at the caudal pole.

**Spleen**

The **spleen** presented a smooth homogeneous parenchyma hyperechoic to liver and renal cortical parenchyma. The capsule was smooth without noticeable expansion or deviation from within the spleen or adjacent pathology. The splenic vasculature demonstrated normal volume without signs of congestion or thrombosis. No sonographic evidence of acute or chronic inflammatory, neoplastic, or infarctual changes were noted.

**Liver**

The **liver** revealed coarse architecture and multifocal hyper- and hypoechoic nondisruptive nodular changes, measuring up to 1.6 cm. Minor increased portal markings were noted. The gallbladder and common bile duct were unremarkable.

**Gastrointestinal**

Examination of the **gastrointestinal tract** revealed a stomach and intestine free of stasis, of normal wall thickness, acceptable curvilinear mural detail, and peristaltic activity. Small and large intestine demonstrated normal luminal chyme and stool consistency respectively. No obstructive or overt infiltrative disease was noted. No associated abnormal lymphatic activity was noted.



**PATIENT**

**Pancreas**

Leonidas Francis

The base and limbs of the **pancreas** were observed to be largely isoechoic to surrounding omental fat. Pancreatic duct and capsular contour were acceptably normal and parenchyma respected normal curvilinear patterns. No overt evidence of active inflammatory or neoplastic disease was noted.

**SPECIES**

Canine

**ULTRASONOGRAPHIC FINDINGS**

**BREED**

Cockapoo

- Nonspecific mild hepatic remodeling with hyper- and hypoechoic nodular changes (likely lipid plaques and nonspecific inflammatory hepatopathy).

**SEX**

**INTERPRETATION OF THE FINDINGS & FURTHER RECOMMENDATIONS**

Neutered Male

Ultrasound guided FNA upon the general parenchyma and nodular changes was noted.

**AGE**

12 Years 4 Months

**WEIGHT**

29 Pounds

**INTERPRETED BY**

Eric Lindquist, DMV,  
DABVP(CFM), Cert.  
IUUSS

**IMAGING PERFORMED BY**

Vincent Ravancho, CVT

**HOSPITAL NAME**

Summit Dog and Cat  
Hospital

**REFERRING VET**

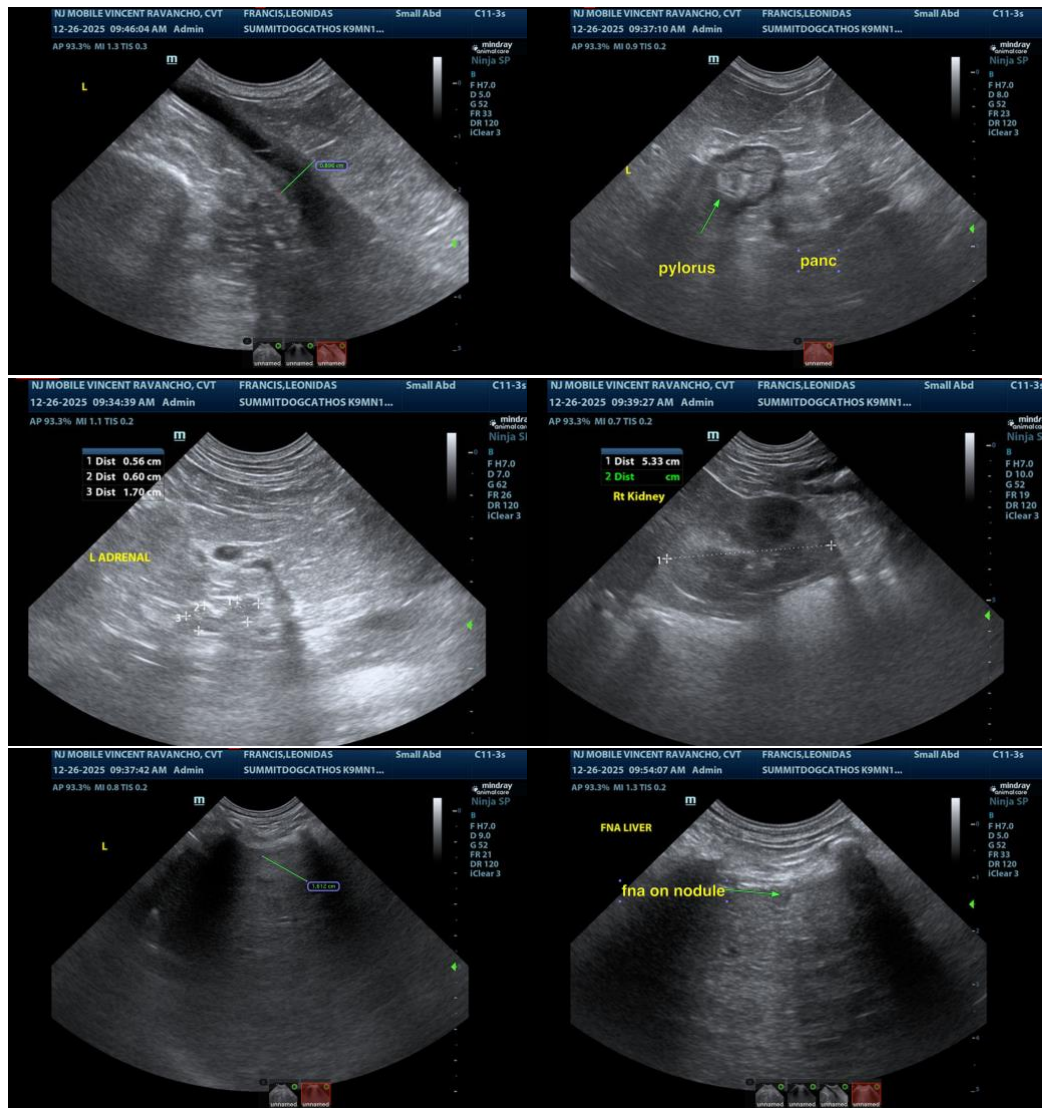
Dr. Baker

**INVOICE**

35088

**DATE**

12/26/25





**PATIENT**

Leonidas Francis

**SPECIES**

Canine

**BREED**

Cockapoo

**SEX**

Neutered Male

**AGE**

12 Years 4 Months

**WEIGHT**

29 Pounds

**INTERPRETED BY**

Eric Lindquist, DMV,  
 DABVP(CFM), Cert.  
 IVUSS

**IMAGING PERFORMED BY**

Vincent Ravancho, CVT

**HOSPITAL NAME**

Summit Dog and Cat  
 Hospital

**REFERRING VET**

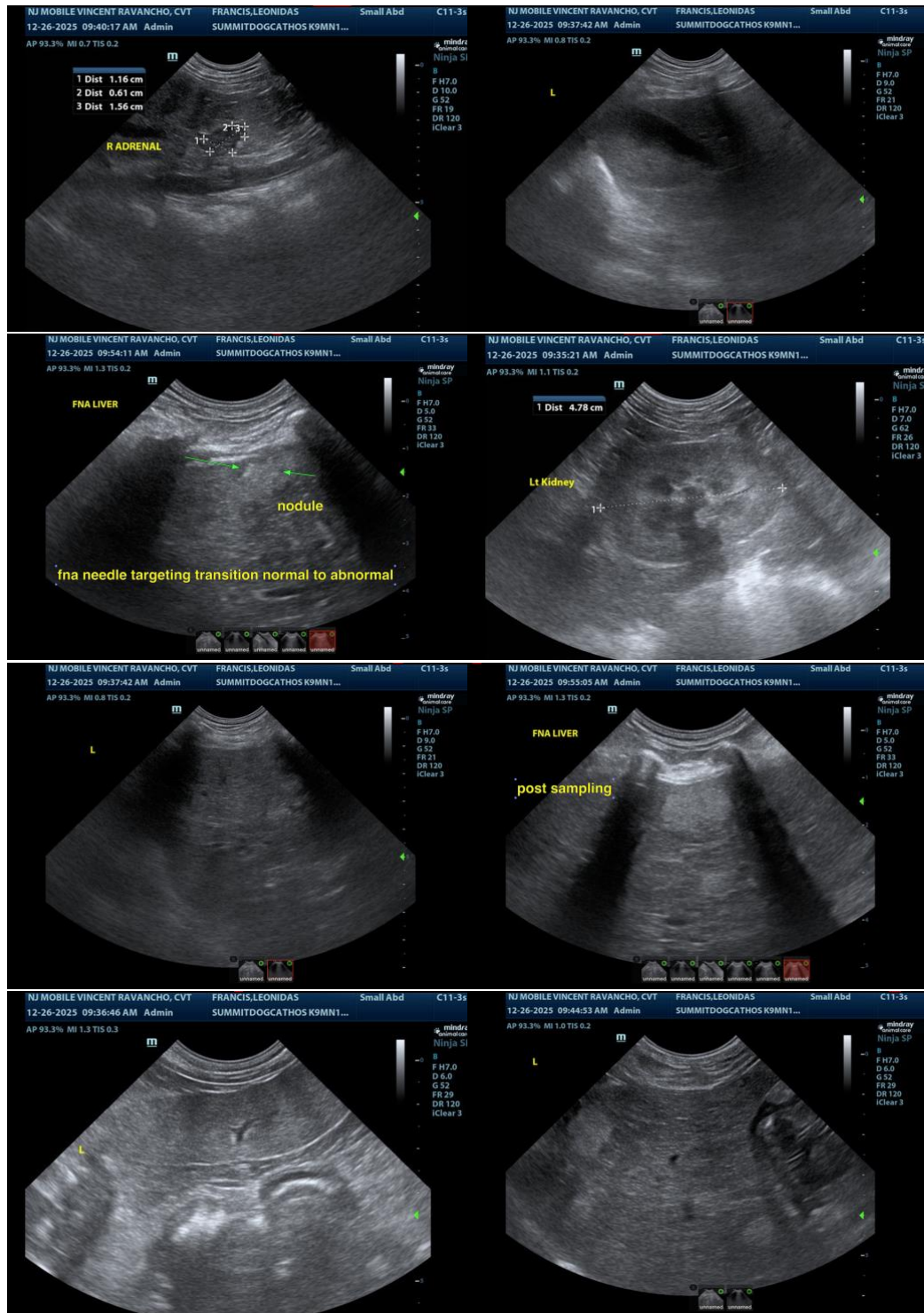
Dr. Baker

**INVOICE**

35088

**DATE**

12/26/25



The information and recommendations provided are based on the images presented by the



**PATIENT**

Leonidas Francis

**SPECIES**

Canine

**BREED**

Cockapoo

**SEX**

Neutered Male

**AGE**

12 Years 4 Months

**WEIGHT**

29 Pounds

**INTERPRETED BY**

Eric Lindquist, DMV,  
DABVP(CFM), Cert.  
IVUSS

**IMAGING  
PERFORMED BY**

Vincent Ravancho, CVT

**HOSPITAL NAME**

Summit Dog and Cat  
Hospital

**REFERRING VET**

Dr. Baker

**INVOICE**

35088

**DATE**

12/26/25

**referring veterinarian/sonographer. No evaluation can be communicated regarding pathology that was not visible in the image/video clips provided.**

Thank you for this referral. If the clinical or image interpretation does not parallel your findings or if I can be of any further assistance please contact me.

**Eric Lindquist**, DMV, DABVP(CFM), Cert. IVUSS,  
CEO, Owner, Founder -- SonoPath.com  
[info@SonoPath.com](mailto:info@SonoPath.com)