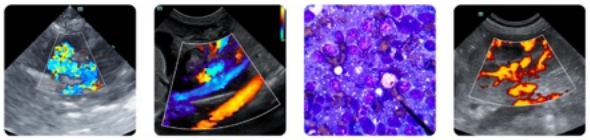

PATIENT
Sunny Hudak

SPECIES
Canine

BREED
Australian Shepherd

SEX
Male

AGE
8 years

WEIGHT
24.5 kg

INTERPRETED BY
Eric Lindquist, DMV DABVP, Cert. IVUSS

IMAGING PERFORMED BY
Kari Wilson, DVM

HOSPITAL NAME
Animal Emergency Hospital Deland

REFERRING VET
Dr. Wilson

INVOICE
69576

DATE
12/25/25

PRESENTING CLINICAL SIGNS

History: Pet presented at primary yesterday (12/24/25) for having an episode of 10 short dry coughs, then immediately after collapsed. Retained consciousness but did wobbly and tipped to his side. No medications. P presented today for vomiting 4x, diarrhea.
Abnormal PE/Chem/CBC/UA Results: rDVM Rad FINDINGS 12/24/25: • Cardiac silhouette: The cardiac silhouette is prominent in size mild rounding in the ventrodorsal projection (VHS = 11.6; reference: 8.7-10.7). There are no signs of left atrial enlargement. Great vessels: The aorta and caudal vena cava are within normal limits. Pulmonary vessels: The pulmonary vessels are within normal limits of size and are symmetric to one another. • Lungs: There is a mild diffuse bronchointerstitial pulmonary pattern present. The pulmonary parenchyma is otherwise normal with no evidence of abnormal pulmonary infiltrates, pulmonary masses, or nodules. Trachea/Bronchi: The trachea and large caliber airways are normal. rDVM BW- BUN 36mg/dL (7-27) RBC 5.18 (5.65-8.87) HCT 34.8% (37.3-61.7) HGB 12.4 (13.1-20.5)
Radiographic CONCLUSIONS:
1. The bronchointerstitial lung pattern can be due to age related changes, but chronic bronchitis (allergic/inflammatory, due to infectious etiologies or inhalation of irritants) cannot be excluded.
2. There is equivocal cardiomegaly, which can be an individual variation or due to underlying cardiac disease like valvular degeneration. However, there is no evidence of cardiac decompensation and this is likely an incidental finding. Cardiac arrhythmia is not ruled out.
3. There are signs of hepatomegaly, which can be benign (steroid hepatopathy, other vacuolopathies, benign hyperplasia) or less likely due to diffuse neoplastic infiltration.

ULTRASONOGRAPHIC EXAMINATION OF THE ABDOMEN

Urinary System

The **urinary bladder**, trigone, and pelvic urethra presented normal thicknesses and normal tone. The ureters were not visible which is normal. No uroliths or sediment were visualized and anechoic urine was present. No evidence of inflammatory or neoplastic changes was noted. Ureteral papillae were normal.

The **kidneys** revealed normal size and structure, corticomedullary definition and ratio for this age. The cortices presented largely uniform texture with normal echogenic relationship to liver and spleen. Medullary structure differed distinctly from the cortex and no evidence of pelvic dilation was present. The capsules were acceptably uniform without significant irregularities. The left and right kidney measured 6.0 cm.

The **prostate** was uniformly enlarged with lobar swelling appeared to impinge upon the urethra and mildly deviate the descending colon. The prostatic tissue was hyperechoic containing focal areas of decreased echogenicity. These changes are suggestive of either chronic inflammatory episodes, benign cystic pathology or both. Underlying neoplasia cannot be completely ruled-out but is lower on the differential list. This presentation is most consistent with benign prostatic hyperplasia with possible active prostatitis. Neutering or off-label Finasteride (Propecia) (0.1-0.5 mg/kg Sid) treatment is indicated +/- FNA or prostatic wash cytology and culture. The prostate measured 4.0 cm.

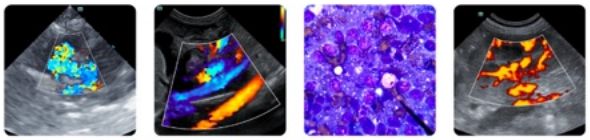

PATIENT
Sunny Hudak

SPECIES
Canine

BREED
Australian Shepherd

SEX
Male

AGE
8 years

WEIGHT
24.5 kg

INTERPRETED BY
Eric Lindquist, DMV
DABVP, Cert. IVUSS

IMAGING PERFORMED BY
Kari Wilson, DVM

HOSPITAL NAME
Animal Emergency Hospital Deland

REFERRING VET
Dr. Wilson

INVOICE
69576

DATE
12/25/25

Adrenal Glands

Both **adrenal glands** were visualized and recognized as having normal shape, size, position and echogenicity for this breed. The phrenic vasculature, glandular echogenicity and detail were unremarkable. Capsule, cortex, and medullary definition were normal for this age patient. The left adrenal gland measured 0.6 cm. The right adrenal gland measured 0.8 cm at the cranial pole and 0.6 cm at the caudal pole.

Spleen

The **spleen** presented a smooth homogeneous parenchyma hyperechoic to liver and renal cortical parenchyma. The capsule was smooth without noticeable expansion or deviation from within the spleen or adjacent pathology. The splenic vasculature demonstrated normal volume without signs of congestion or thrombosis. No sonographic evidence of acute or chronic inflammatory, neoplastic, or infarctual changes was noted.

Liver

The **liver** was mildly enlarged and uniform with no evidence of pathology. Hepatic vein dilation was noted in the liver. This is consistent with passive congestion owing to thoracic disease. The gallbladder was edematous with mild ascites.

Gastrointestinal

Examination of the **gastrointestinal tract** revealed a stomach and intestine free of stasis, of normal wall thickness, acceptable curvilinear mural detail, and peristaltic activity. Small and large intestine demonstrated normal luminal chyme and stool consistency respectively. Fluid filled colon was noted. No obstructive or overt infiltrative disease was noted. No associated abnormal lymphatic activity was noted.

Pancreas

The **pancreas** presented edematous contour owing to passive congestion.

Free Abdomen

Secondary ascites was noted.

PATIENT

Sunny Hudak

SPECIES

Canine

BREED

Australian Shepherd

SEX

Male

AGE

8 years

WEIGHT

24.5 kg

INTERPRETED BY

Eric Lindquist, DMV
DABVP, Cert. IVUSS

IMAGING PERFORMED BY

Kari Wilson, DVM

HOSPITAL NAME

Animal Emergency Hospital Deland

REFERRING VET

Dr. Wilson

INVOICE

69576

DATE

12/25/25

ULTRASONOGRAPHIC FINDINGS

Passive congestion liver pattern with secondary gallbladder edema and hepatic vein dilation.

Secondary ascites likely owing to primary thoracic disease such as right-sided heart failure or obstructive caval syndrome.

Fluid filled colon, resolving gastroenteritis with fluid filled colon.

INTERPRETATION OF THE FINDINGS & FURTHER RECOMMENDATIONS

I recommend palliative support of the GI tract with focus on the thoracic presentation based on echocardiogram results.

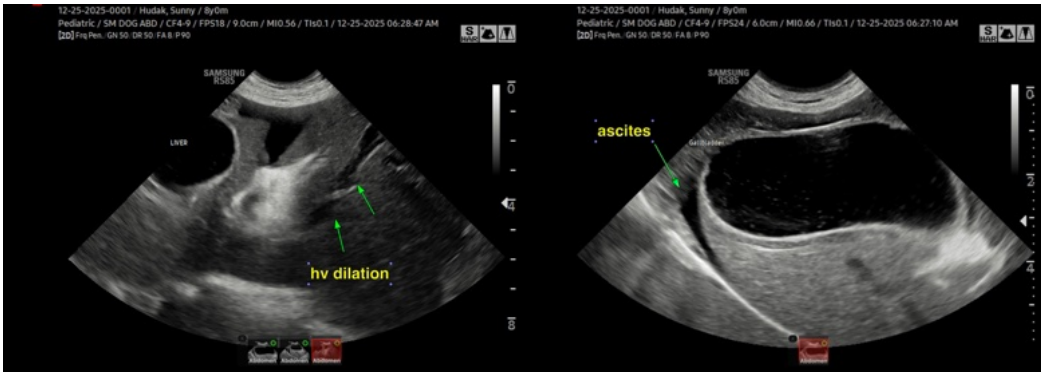

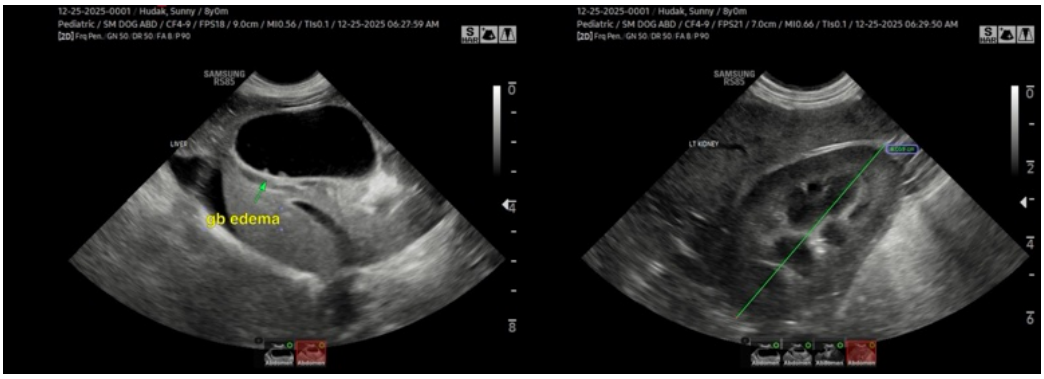

SonoPath
FOSTERING THE ART OF VETERINARY MEDICINE™

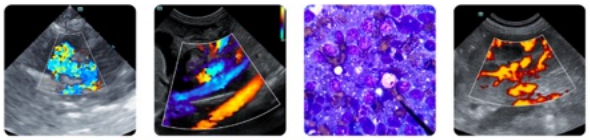

Clinical Sonography & Telecytology
Educational Teleconsultation Services™

SonoPath.com info@sonopath.com 1.800.838.4268

PATIENT

Sunny Hudak

SPECIES

Canine

BREED

Australian Shepherd

SEX

Male

AGE

8 years

WEIGHT

24.5 kg

INTERPRETED BY

Eric Lindquist, DMV
DABVP, Cert. IVUSS

IMAGING PERFORMED BY

Kari Wilson, DVM

HOSPITAL NAME

Animal Emergency Hospital Deland

REFERRING VET

Dr. Wilson

INVOICE

69576

DATE

12/25/25

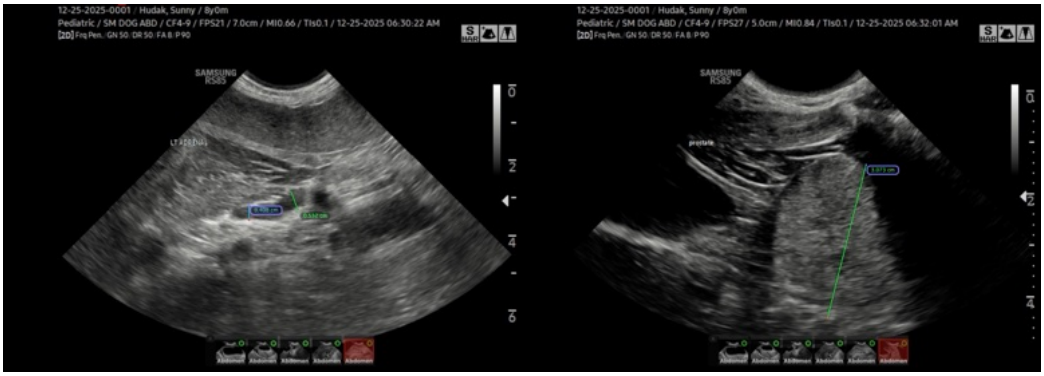

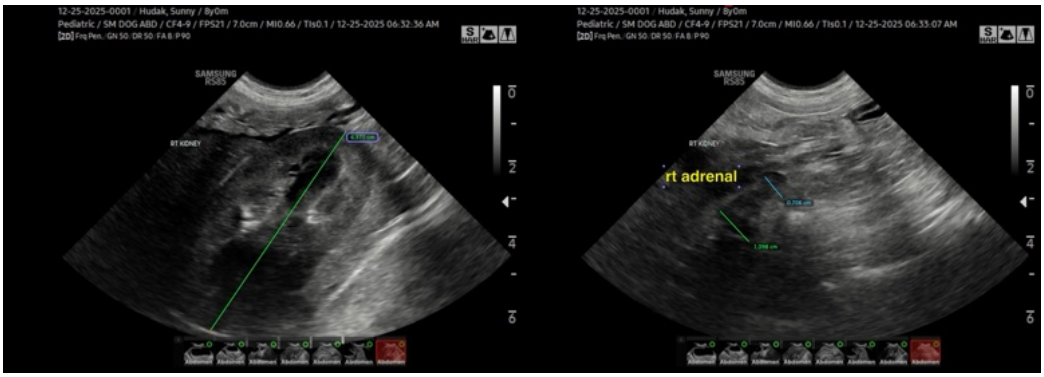

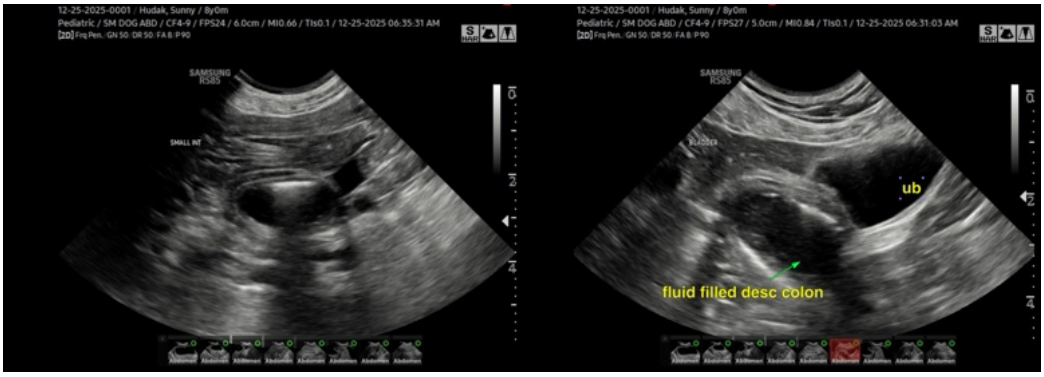

The information and recommendations provided are based on the images presented by the referring veterinarian/sonographer. No evaluation can be communicated regarding pathology that was not visible in the image/video clips provided.

Thank you for this referral. If the clinical or image interpretation does not parallel your findings or if I can be of any further assistance please contact me.

Eric Lindquist, DMV, DABVP (CFM), Cert. IVUSS, CEO of SonoPath.com

info@SonoPath.com