



PATIENT

Burt Recek

SPECIES

Canine

BREED

Pug

SEX

Neutered male

AGE

5 years

WEIGHT

24 lbs

INTERPRETED BY

Eric Lindquist, DMV
DABVP, Cert. IVUSS

IMAGING PERFORMED BY

Michael Wasserman

HOSPITAL NAME

Morningside AH

REFERRING VET

Dr. Wasserman

INVOICE

69590

DATE

12/24/25

PRESENTING CLINICAL SIGNS

History: This is an employee/technician's pet. Patient presented for sedated nail trim. Dexdomitor 0.5mg/ml 0.15ml IV for exam. Submitting for abdomen assessment/wellness screening. Full SDEP attempted. No concerns or abnormal noted at home. History of allergies and responds well to cytopoint. **Prevention:** Simparica Trio.
Abnormal PE/Chem/CBC/UA Results: None performed of clinical significance recently. Last BW performed two years prior.

ULTRASONOGRAPHIC EXAMINATION OF THE ABDOMEN

Urinary System

The **urinary bladder**, trigone, and pelvic urethra presented normal thicknesses and normal tone. The pelvic urethra was imaged 3.0 cm beyond the cystourethral junction and appeared normal. The ureters were not visible which is normal. No uroliths or sediment were visualized and anechoic urine was present. No evidence of inflammatory or neoplastic changes was noted. Ureteral papillae were normal.

The **kidneys** revealed normal size and structure, corticomedullary definition and ratio for this age. The cortices presented largely uniform texture with normal echogenic relationship to liver and spleen. Medullary structure differed distinctly from the cortex and no evidence of pelvic dilation was present. The capsules were acceptably uniform without significant irregularities. The right kidney measured 4.32 cm. The left kidney measured 4.3 cm.

The residual prostate measured 0.5 cm.

Adrenal Glands

Both **adrenal glands** were visualized and recognized as having normal shape, size, position and echogenicity for this breed. The phrenic vasculature, glandular echogenicity and detail were unremarkable. Capsule, cortex, and medullary definition were normal for this age patient. The left adrenal gland measured 1.5 x 0.7 cm at the caudal pole and 0.54 cm at the cranial pole. The right adrenal gland measured 2.0 x 0.49 cm at the caudal pole and 0.34 cm at the cranial pole.

Spleen

The **spleen** in this patient was mildly enlarged with uniform parenchyma and was folded upon itself cranially. This is a positional variant and is not pathological. There was no evidence of significant disease.

Liver

The **liver** images submitted revealed subjectively normal liver size, contour, and structure. Parenchymal echogenicity was naturally coarse and hypoechoic to the spleen. Vascular and biliary tracts were of normal volume with no evidence of congestion. The gallbladder presented acceptably thin walls with primarily anechoic content. The cystic and common bile ducts were normal. No pathological hepatic



PATIENT

lymphadenopathy was evident. No overt structural evidence of inflammatory, infiltrative or regenerative pathology was evident.

Burt Recek

SPECIES

Gastrointestinal

Canine

Examination of the **gastrointestinal tract** revealed a stomach and intestine free of stasis, of normal wall thickness, acceptable curvilinear mural detail, and peristaltic activity. Small and large intestine demonstrated normal luminal chyme and stool consistency respectively. No obstructive or overt infiltrative disease was noted. No associated abnormal lymphatic activity was noted.

BREED

Pug

SEX

Pancreas

Neutered male

The base and limbs of the **pancreas** were observed to be largely isoechoic to surrounding omental fat. Pancreatic duct and capsular contour were acceptably normal and parenchyma respected normal curvilinear patterns. No overt evidence of active inflammatory or neoplastic disease was noted.

AGE

5 years

WEIGHT

24 lbs

ULTRASONOGRAPHIC FINDINGS

Structurally unremarkable abdomen.

INTERPRETED BY

Eric Lindquist, DMV
DABVP, Cert. IVUSS

INTERPRETATION OF THE FINDINGS & FURTHER RECOMMENDATIONS

There was no evidence of pathology.

IMAGING PERFORMED BY

Michael Wasserman

HOSPITAL NAME

Morningside AH

REFERRING VET

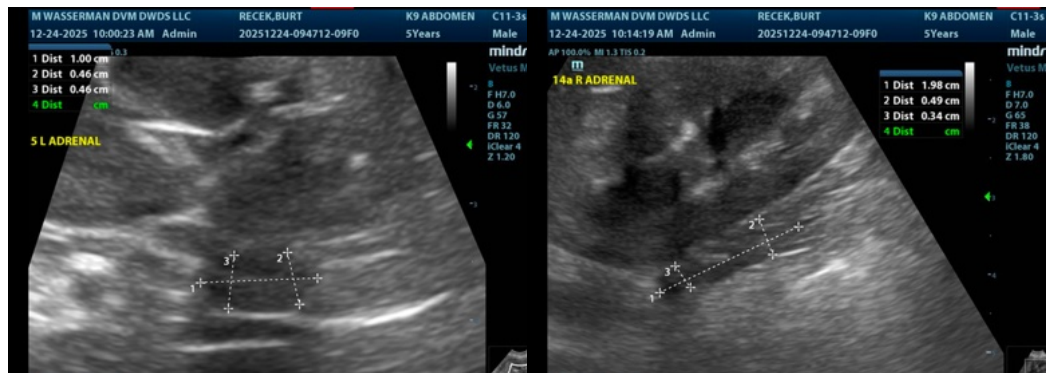
Dr. Wasserman

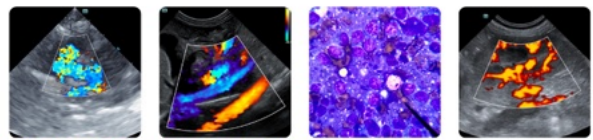
INVOICE

69590

DATE

12/24/25





PATIENT

Burt Recek

SPECIES

Canine

BREED

Pug

SEX

Neutered male

AGE

5 years

WEIGHT

24 lbs

INTERPRETED BY

Eric Lindquist, DMV
DABVP, Cert. IVUSS

IMAGING PERFORMED BY

Michael Wasserman

HOSPITAL NAME

Morningside AH

REFERRING VET

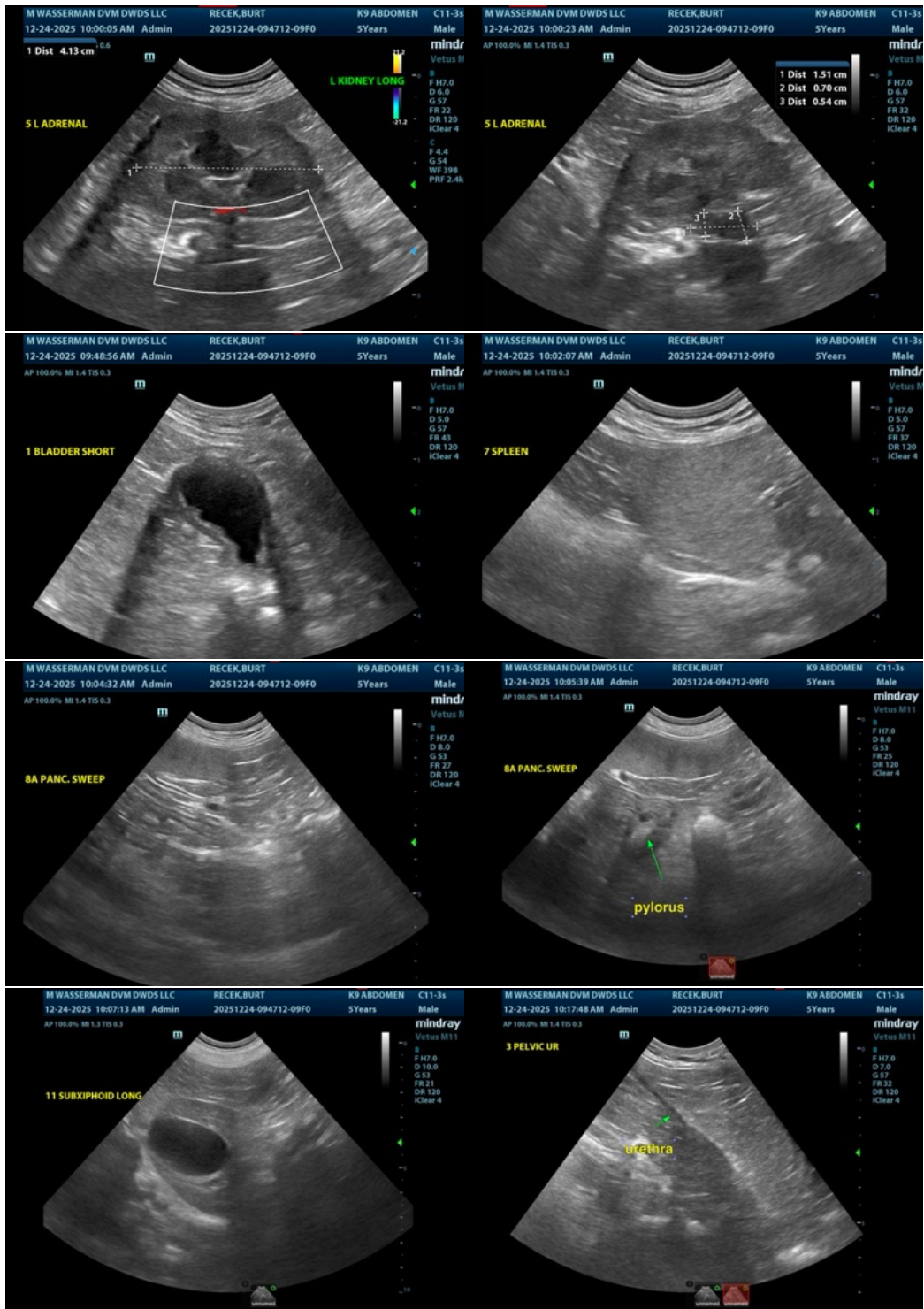
Dr. Wasserman

INVOICE

69590

DATE

12/24/25



The information and recommendations provided are based on the images presented by the referring veterinarian/sonographer. No evaluation can be communicated regarding pathology that was not visible in the image/video clips provided.



PATIENT

Burt Recek

SPECIES

Canine

BREED

Pug

SEX

Neutered male

AGE

5 years

WEIGHT

24 lbs

INTERPRETED BY

Eric Lindquist, DMV
DABVP, Cert. IVUSS

IMAGING PERFORMED BY

Michael Wasserman

HOSPITAL NAME

Morningside AH

REFERRING VET

Dr. Wasserman

INVOICE

69590

DATE

12/24/25

Thank you for this referral. If the clinical or image interpretation does not parallel your findings or if I can be of any further assistance please contact me.

Eric Lindquist, DMV, DABVP (CFM), Cert. IVUSS, CEO of SonoPath.com

info@SonoPath.com