



PATIENT PRESENTING CLINICAL SIGNS

Luna Safir Recheck for foreign body.

SPECIES ULTRASONOGRAPHIC EXAMINATION OF THE ABDOMEN

Canine **Urinary System**

BREED The **urinary bladder**, trigone, and pelvic urethra presented normal thicknesses and normal tone. The ureters were not visible which is normal. No uroliths or sediment were visualized and anechoic urine was present. No evidence of inflammatory or neoplastic changes was noted. Ureteral papillae were normal.

Chihuahua

SEX The **kidneys** revealed normal size and structure, corticomedullary definition and ratio for this age. The cortices presented largely uniform texture with normal echogenic relationship to liver and spleen. Medullary structure differed distinctly from the cortex and no evidence of pelvic dilation was present.

Spayed Female

AGE The capsules were acceptably uniform without significant irregularities. The left kidney measured 3.59 cm. The right kidney measured 3.63 cm.

10 years

INTERPRETED BY Adrenal Glands

Eric Lindquist, DMV DABVP, Cert. IVUSS Both **adrenal glands** were visualized and recognized as having normal shape, size, position and echogenicity for this breed. The phrenic vasculature, glandular echogenicity and detail were unremarkable. Capsule, cortex, and medullary definition were normal for this age patient. The left adrenal gland measured 1.29 x 0.4 cm. The right adrenal gland measured 1.62 x 0.89 cm at the cranial pole and 0.59 cm at the caudal pole.

IMAGING PERFORMED BY

Eric Lindquist, DMV DABVP, Cert. IVUSS

HOSPITAL NAME

Rockaway AH

Spleen

The **spleen** was normal size and relatively normal contour with multifocal hyperechoic areas of mineralization. This is a benign change; however, can be related to Cushing's disease or other endocrinopathies.

REFERRING VET

Dr. Maniar

Liver

The **liver** images submitted revealed subjectively normal liver size, contour, and structure. Parenchymal echogenicity was naturally coarse and hypoechoic to the spleen. Vascular and biliary tracts were of normal volume with no evidence of congestion. The gallbladder presented acceptably thin walls with primarily anechoic content. The cystic and common bile ducts were normal. No pathological hepatic lymphadenopathy was evident. No overt structural evidence of inflammatory, infiltrative or regenerative pathology was evident.

INVOICE

94916

DATE

12/24/21

Gastrointestinal

Examination of the **gastrointestinal tract** revealed a stomach and intestine free of stasis, of normal wall thickness, acceptable curvilinear mural detail, and peristaltic activity. Small and large intestine



PATIENT

Luna Safir

demonstrated normal luminal chyme and stool consistency respectively. No obstructive or overt infiltrative disease was noted. No associated abnormal lymphatic activity was noted.

SPECIES

Canine

Pancreas

The base and limbs of the **pancreas** were observed to be largely isoechoic to surrounding omental fat. Some parenchymal remodeling, however, with mild deviation from curvilinear normalcy was observed. Pancreatic duct and capsular irregularities were present consistent with age related changes. If pain upon imaging (+ Murphy sign) was present or if the patient is focally painful in subxiphoid palpation then low-grade smoldering chronic pancreatitis should be suspected.

BREED

Chihuahua

SEX

Spayed Female

ULTRASONOGRAPHIC FINDINGS

Normal geriatric abdomen.

AGE

10 years

INTERPRETATION OF THE FINDINGS & FURTHER RECOMMENDATIONS

The gastric material has resolved and the stomach was empty.

INTERPRETED BY

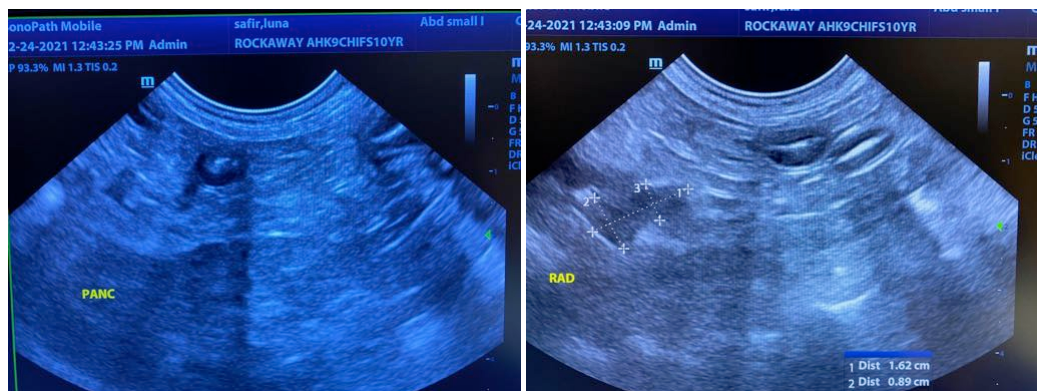
Eric Lindquist, DMV
DABVP, Cert. IVUSS

IMAGING PERFORMED BY

Eric Lindquist, DMV
DABVP, Cert. IVUSS

HOSPITAL NAME

Rockaway AH



REFERRING VET

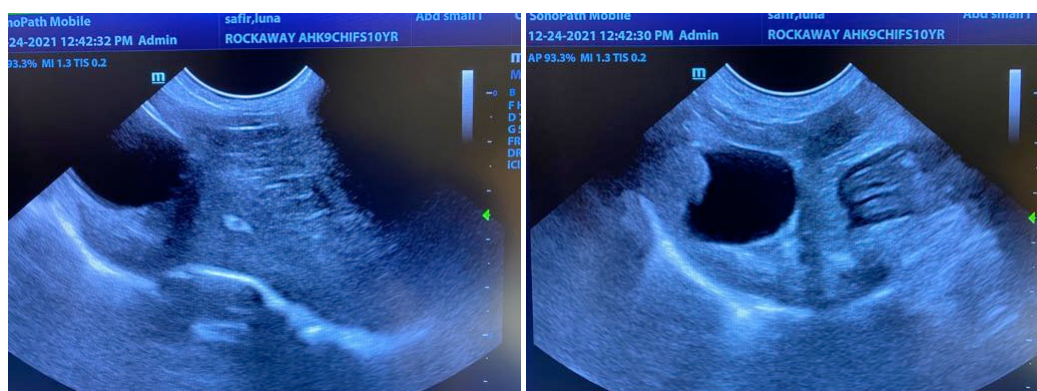
Dr. Maniar

INVOICE

94916

DATE

12/24/21





PATIENT

Luna Safir

SPECIES

Canine

BREED

Chihuahua

SEX

Spayed Female

AGE

10 years

INTERPRETED BY

Eric Lindquist, DMV
DABVP, Cert. IVUSS

IMAGING PERFORMED BY

Eric Lindquist, DMV
DABVP, Cert. IVUSS

HOSPITAL NAME

Rockaway AH

REFERRING VET

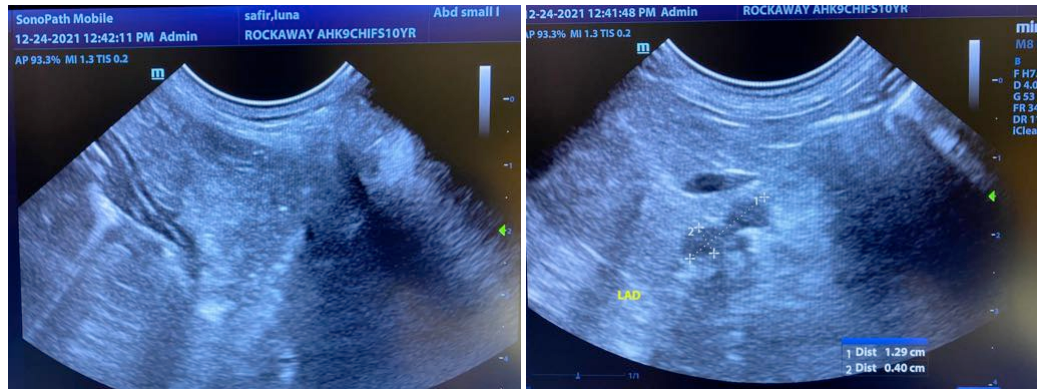
Dr. Maniar

INVOICE

94916

DATE

12/24/21



The information and recommendations provided are based on the images presented by the referring veterinarian. No evaluation can be communicated regarding pathology that was not visible in the image/video clips provided.

Thank you for this referral. If the clinical or image interpretation does not parallel your findings or if I can be of any further assistance please contact me.

Eric Lindquist, DMV, DABVP, Cert. IVUSS, CEO of SonoPath.com
Info@SonoPath.com