



**PATIENT**

Token Santiago

**SPECIES**

Canine

**BREED**

Mixed

**SEX**

Spayed Female

**AGE**

2 Years

**WEIGHT**

19 lbs

**INTERPRETED BY**

Eric Lindquist, DMV,  
DABVP (CFM), Cert.  
IVUSS

**IMAGING PERFORMED BY**

Vincent Ravancho, CVT

**HOSPITAL NAME**

All Creatures Great &  
Small (Denville)

**REFERRING VET**

Dr. Silas

**INVOICE**

72735

**DATE**

12/23/25

**PRESENTING CLINICAL SIGNS**

Hematemesis 3 times, hematochezia 2 times Clinical findings: Dog ate stuffing Sedated with Torb

**ULTRASONOGRAPHIC EXAMINATION OF THE ABDOMEN**

**Urinary System**

The **urinary bladder**, trigone, and pelvic urethra presented normal thicknesses and normal tone. The ureters were not visible which is normal. No uroliths or sediment were visualized and anechoic urine was present. No evidence of inflammatory or neoplastic changes were noted. Ureteral papillae were normal. The pelvic urethra was imaged 2.0 cm beyond the cystourethral junction.

The **kidneys** revealed normal size and structure, corticomedullary definition and ratio for this age. The cortices presented largely uniform texture with normal echogenic relationship to liver and spleen. Medullary structure differed distinctly from the cortex and no evidence of pelvic dilation was present. The capsules were acceptably uniform without significant irregularities. Right kidney measured 4.57 cm. Left kidney measured 4.55 cm.

**Adrenal Glands**

Both **adrenal glands** were visualized and recognized as having normal shape, size, position and echogenicity for this breed. The phrenic vasculature, glandular echogenicity and detail were unremarkable. Capsule, cortex, and medullary definition were normal for this age patient. Left measured 1.95 cm x 0.45 cm at the cranial pole and 0.32 cm at the caudal pole. Right measured 1.82 cm x 1.08 cm at the cranial pole and 0.43 cm at the caudal pole.

**Spleen**

The **spleen** presented a smooth homogeneous parenchyma hyperechoic to liver and renal cortical parenchyma. The capsule was smooth without noticeable expansion or deviation from within the spleen or adjacent pathology. The splenic vasculature demonstrated normal volume without signs of congestion or thrombosis. No sonographic evidence of acute or chronic inflammatory, neoplastic, or infarctual changes were noted.

**Liver**

The **liver** images submitted revealed subjectively normal liver size, contour, and structure. Parenchymal echogenicity was naturally coarse and hypoechoic to the spleen. Vascular and biliary tracts were of normal volume with no evidence of congestion. The gallbladder presented acceptably thin walls with primarily anechoic content. The cystic and common bile ducts were normal. No pathological hepatic lymphadenopathy was evident. No overt structural evidence of inflammatory, infiltrative or regenerative pathology was evident.

**Gastrointestinal**

The **stomach** presented echogenic mucosal hypertrophy and remodeling. Minor amount of excessive fluid and gas noted, consistent with non-specific gastritis. The small intestine and colon were unremarkable.



**PATIENT**

Token Santiago

**SPECIES**

Canine

**BREED**

Mixed

**SEX**

Spayed Female

**AGE**

2 Years

**WEIGHT**

19 lbs

**INTERPRETED BY**

Eric Lindquist, DMV,  
DABVP (CFM), Cert.  
IVUSS

**IMAGING PERFORMED BY**

Vincent Ravancho, CVT

**HOSPITAL NAME**

All Creatures Great &  
Small (Denville)

**REFERRING VET**

Dr. Silas

**INVOICE**

72735

**DATE**

12/23/25

**Pancreas**

The base and limbs of the **pancreas** were observed to be largely isoechoic to surrounding omental fat. Pancreatic duct and capsular contour were acceptably normal and parenchyma respected normal curvilinear patterns. No overt evidence of active inflammatory or neoplastic disease was noted.

**ULTRASONOGRAPHIC FINDINGS**

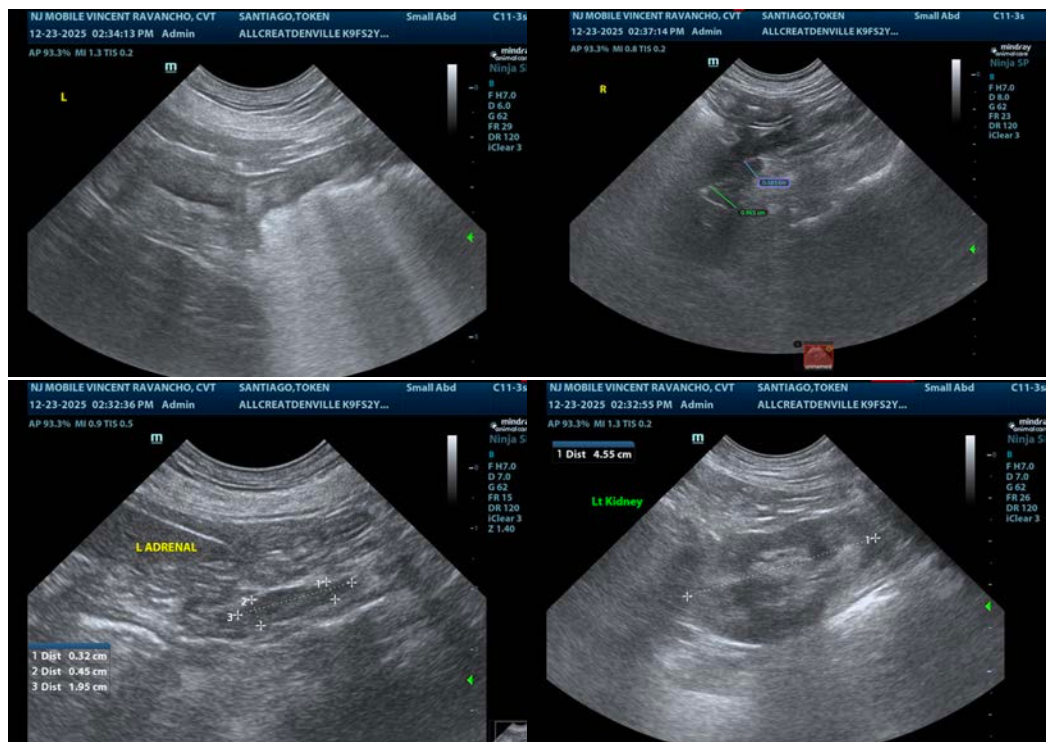
- Non-specific gastritis pattern.

**INTERPRETATION OF THE FINDINGS & FURTHER RECOMMENDATIONS**

No evidence of neoplasia or foreign bodies. A clinical trial of the following may prove effective. No overt macro ulcerative changes noted. However, I cannot rule out micro ulcerative disease.

**Helicobacter/Gastritis protocol**

A clinical trial of **Zithromax (Dogs: 5-10 mg/kg p.o. q24h. May increase dosing interval to q48h after 3-5 days of treatment), Metronidazole (10-20 mg/kg p.o. b.i.d.), Pepcid (0.5-1 mg/kg s.i.d.) and Sucralfate (0.5-2 g/dog PO) or Omeprazole (1 mg/kg p.o. s.i.d.)** over the next 3 weeks along with a **novel-protein or hydrolyzed diet** with slurry feeding b.i.d./t.i.d. over the next 2-4 days and then increase to canned diet bid. Dry food should be avoided over the next 4 weeks. A recheck sonogram to assess GI improvement or progression would be ideal in 4 weeks.





**PATIENT**

Token Santiago

**SPECIES**

Canine

**BREED**

Mixed

**SEX**

Spayed Female

**AGE**

2 Years

**WEIGHT**

19 lbs

**INTERPRETED BY**

Eric Lindquist, DMV,  
DABVP (CFM), Cert.  
IVUSS

**IMAGING PERFORMED BY**

Vincent Ravancho, CVT

**HOSPITAL NAME**

All Creatures Great &  
Small (Denville)

**REFERRING VET**

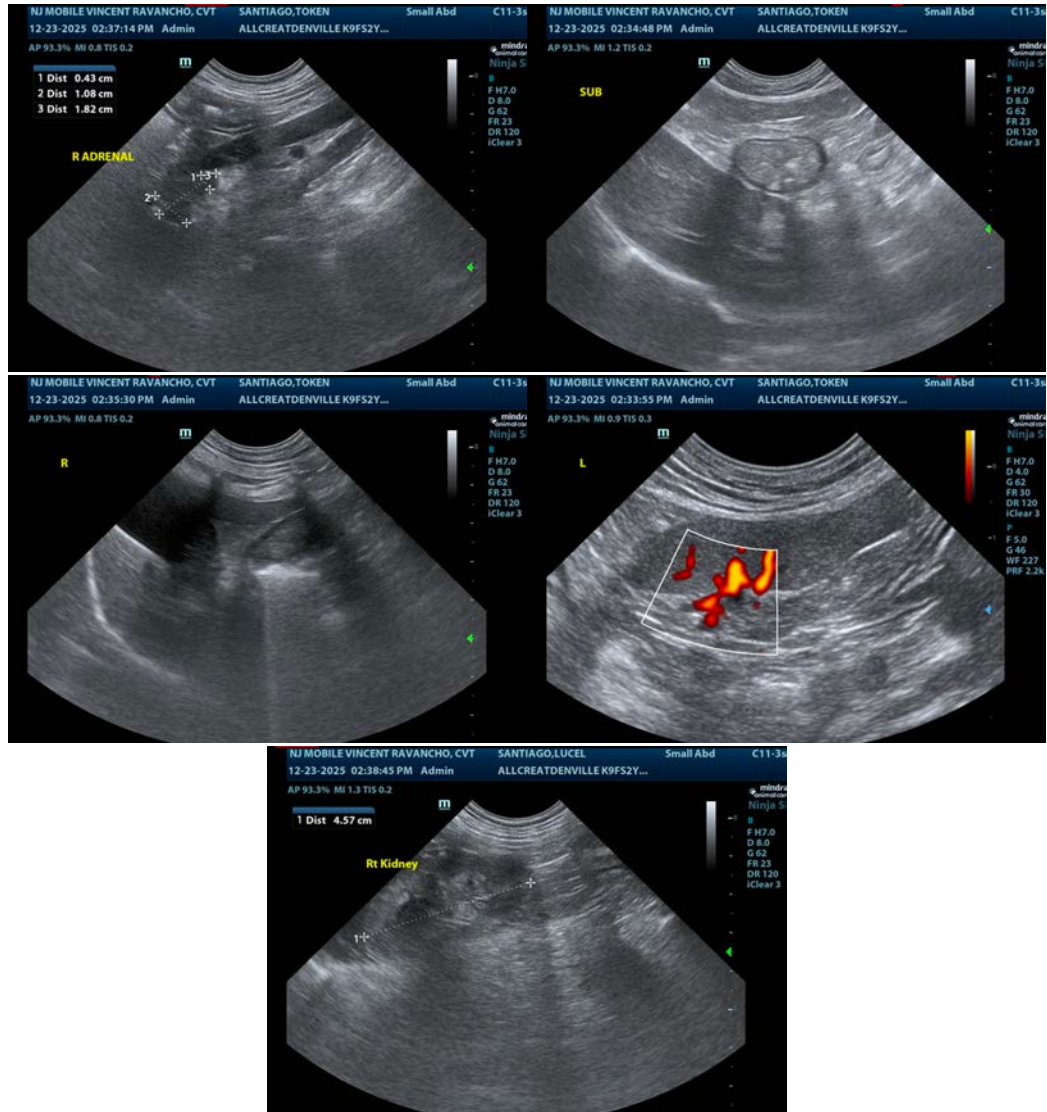
Dr. Silas

**INVOICE**

72735

**DATE**

12/23/25



The information and recommendations provided are based on the images presented by the referring veterinarian/sonographer. No evaluation can be communicated regarding pathology that was not visible in the image/video clips provided.

Thank you for this referral. If the clinical or image interpretation does not parallel your findings or if I can be of any further assistance please contact me.

**Eric Lindquist**, DMV, DABVP(CFM), Cert. IVUSS,  
CEO, Owner, Founder -- SonoPath.com  
[info@SonoPath.com](mailto:info@SonoPath.com)