



PATIENT

Skippy Hickey

SPECIES

Canine

BREED

Dachshund Mix

SEX

Neutered Male

AGE

14 Years

WEIGHT

9.8 Pounds

INTERPRETED BY

Eric Lindquist, DMV,
DABVP (Canine &
Feline), Cert. IVUSS

IMAGING

PERFORMED BY

Rebecca Hamilton

HOSPITAL NAME

Rockaway AH

REFERRING VET

Dr. Dubos

INVOICE

35059

DATE

12/23/25

PRESENTING CLINICAL SIGNS

History: Suspected HGE, hematemesis. Meds: Cerenia, Fluids, unasyn, dextrose, metro
Abnormal PE/Chem/CBC/UA Results: HCT 75, WBC 4K, Neutrophils 0.76, bands present, Creat 2.0,
BUN 40, Glucose 48, Phos 8.7, ALT241, ALP 247, TBili 2.5, CPL >2000

ULTRASONOGRAPHIC EXAMINATION OF THE HEART & ABDOMEN

CANINE CARDIAC PARAMETERS	MR VMAX (m/s)	TR VMAX (m/s)	LA/AO (M-Mode)	LA/AO (Heart Base; Swe)	FS (%)	EF (%)	EPSS (cm)
NORMAL PARAMETER	4.5-5.5	<2.7	1.3	Up to 1.6	28-40	40-100	<0.6
PATIENT	--	--	NM	--	40	--	0.1
CANINE CARDIAC PARAMETERS	HR (BPM)	AV VMAX (m/s)	PV MAX (m/s)	BODY WEIGHT (lbs)	LAD LA MAX 4 Chamber	LVIDd Avg; 2D and m-mode short axis (cm)	LVIDs Avg; 2D and m-mode short axis (cm)
NORMAL PARAMETER	50-100	0.7-1.7	0.7-1.6				
PATIENT	--	1.00	.90	9.8 lbs	2.0	1.8	--

Cardiac Presentation

The echocardiogram in this patient demonstrated normal **left atrial** size based on 3 separate methods of LA evaluation. The cranial and caudal **mitral** valve leaflets presented normal linear structure, extension in systole, and union in diastole with normal kinesis. The **left ventricle** presented thicknesses with linear contour and was not dilated nor restricted. The **myocardium** presented normal echogenicity without subjective evidence of significant fibrotic or ischemic disease.

Contractility of the ventricular walls was adequate and in normal range for this patient evidenced by the fractional shortening measurement and subjective evaluation of the different regions of the myocardium. The **left ventricular outflow** tract demonstrated normal laminar flow and subjective structural integrity. The **right atrium** and auricle revealed normal size, structure and content. No evidence of masses was noted. **Tricuspid** valvular assessment demonstrated adequate linear morphology and kinesis. The **right ventricle** was of normal size (1/3 diameter of LV), chordae structure, myocardial echogenicity and thickness. **Pulmonary outflow** tract assessment revealed normal valve structure, laminar flow, and diameter (approx.1:1 pa/ao ratio). No visible **pericardial** or free pleura fluid was noted. The cranial **mediastinum and pericardial and extra-cardiac regions** were free of masses in the visible window.

Urinary System



PATIENT

Skippy Hickey

SPECIES

Canine

BREED

Dachshund Mix

SEX

Neutered Male

AGE

14 Years

WEIGHT

9.8 Pounds

INTERPRETED BY

Eric Lindquist, DMV,
DABVP (Canine &
Feline), Cert. IVUSS

**IMAGING
PERFORMED BY**

Rebecca Hamilton

HOSPITAL NAME

Rockaway AH

REFERRING VET

Dr. Dubos

INVOICE

35059

DATE

12/23/25

The **urinary bladder**, trigone, and pelvic urethra presented normal thicknesses and normal tone. The ureters were not visible which is normal. No uroliths or sediment were visualized and anechoic urine was present. No evidence of inflammatory or neoplastic changes was noted. Ureteral papillae were normal. The pelvic urethra was imaged 2.0 cm beyond the cystourethral junction. The residual prostate measured 5.0 mm.

The **kidneys** revealed largely normal size and structure, corticomedullary definition and ratio (cortex 1/3 of medulla) were essentially maintained with some moderate age-related loss of curvilinear patterns regarding the capsule and C/M junction. The cortices presented largely uniform texture with some increased echogenicity expected for this age patient. Medullary structure differed distinctly from that of the cortex, and no evidence of pelvic dilation was present. The left kidney measured 3.9 cm. The right kidney measured 3.9 cm.

Adrenal Glands

Both **adrenal glands** were visualized and recognized as having normal shape, size, position and echogenicity for this breed. The phrenic vasculature, glandular echogenicity and detail were unremarkable. Capsule, cortex, and medullary definition were normal for this age patient. The right adrenal gland measured 1.72 cm x 0.76 cm at the cranial pole and 0.34 cm at the caudal pole. The left adrenal gland measured 2.5 cm x 0.5 cm at the cranial pole and 0.5 cm at the caudal pole.

Spleen

The **spleen** presented a smooth homogeneous parenchyma hyperechoic to liver and renal cortical parenchyma. The capsule was smooth without noticeable expansion or deviation from within the spleen or adjacent pathology. The splenic vasculature demonstrated normal volume without signs of congestion or thrombosis. No sonographic evidence of acute or chronic inflammatory, neoplastic, or infarctual changes were noted.

Liver

The **liver** images from right and left intercostal as well as subcostal views revealed subjectively normal liver size, contour, and structure. Some mild age-related parenchymal remodeling was noted but likely not clinically significant at this time. Vascular and biliary tracts were of normal volume, and no evidence of congestion was noted. The gallbladder presented some dependent debris with essentially normal contour. The cystic and common bile ducts were normal. No overt evidence of active inflammatory, infiltrative or regenerative pathology was noted but should be paired with current or past LE elevations regarding any clinical significance to this presentation. The hepatic lymph nodes were unremarkable.

Gastrointestinal

The **stomach** was overdistended with fluid. Gastric stasis was noted. The pylorus was patent. Some suspended hyperechoic structures were present with upper small intestinal linear structures; however, no accordion pleating was noted. Areas of small intestine appeared to be dilated, followed by empty small intestine, creating a partial obstructive pattern. However, I'm concerned for worm burden in this patient. Fecal test is indicated. The colon was unremarkable.

Pancreas



PATIENT

Skippy Hickey

SPECIES

Canine

BREED

Dachshund Mix

SEX

Neutered Male

AGE

14 Years

WEIGHT

9.8 Pounds

INTERPRETED BY

Eric Lindquist, DMV,
DABVP (Canine & Feline), Cert. IVUSS

IMAGING PERFORMED BY

Rebecca Hamilton

HOSPITAL NAME

Rockaway AH

REFERRING VET

Dr. Dubos

INVOICE

35059

DATE

12/23/25

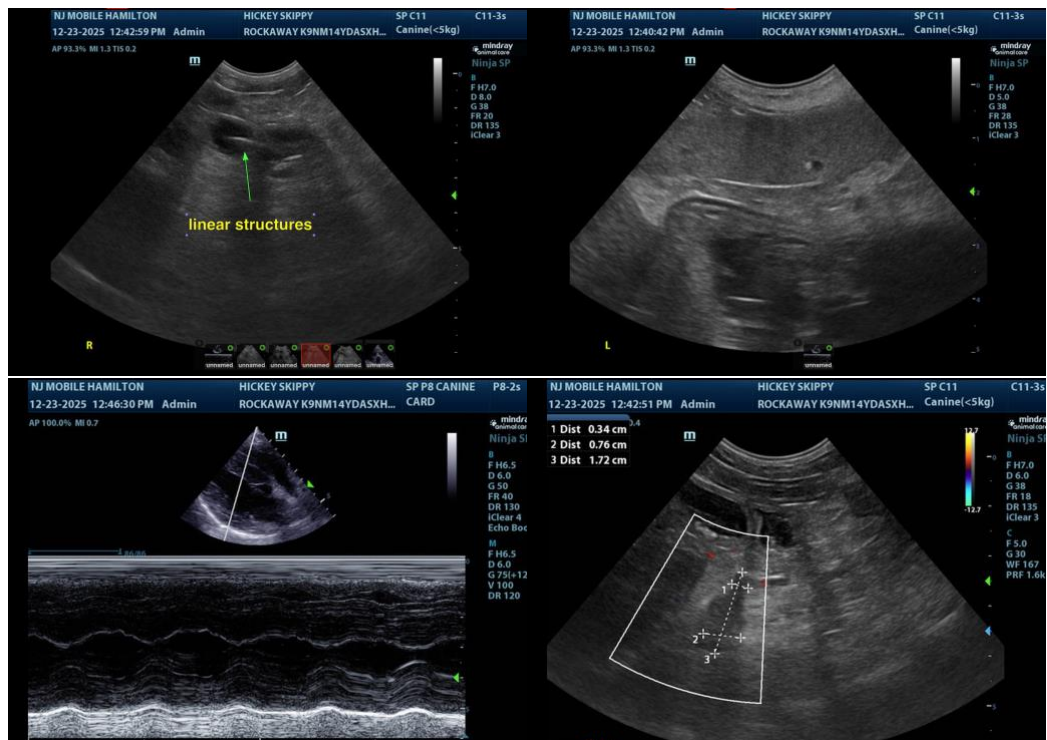
The base and limbs of the **pancreas** were observed to be largely isoechoic to surrounding omental fat. Some moderate parenchymal remodeling, however, with mild deviation from curvilinear normalcy was observed. Pancreatic duct and capsular irregularities were present consistent with age related changes. If pain upon imaging (+ Murphy sign) was present or if the patient is focally painful in subxiphoid palpation, then low-grade smoldering chronic pancreatitis should be suspected.

ULTRASONOGRAPHIC FINDINGS

- Acute insult on age related renal and hepatic changes
- Gastric stasis and partial obstructive pattern. No definitive foreign body was noted. Some worm burden or linear structures appear to be present yet not overtly tethering the GI tract. Therefore, these are not likely the problem.
- Age-related pancreatic changes
- Normal canine cardiac- no evidence of pathology.

INTERPRETATION OF THE FINDINGS & FURTHER RECOMMENDATIONS

I recommend a fresh fecal smear and fecal floatation analysis, IV fluid support, leptospirosis titers, IV ampicillin, and recheck sonogram in 24-48 hours. GI protectant protocol is also indicated.





PATIENT

Skippy Hickey

SPECIES

Canine

BREED

Dachshund Mix

SEX

Neutered Male

AGE

14 Years

WEIGHT

9.8 Pounds

INTERPRETED BY

Eric Lindquist, DMV,
 DABVP (Canine &
 Feline), Cert. IVUSS

**IMAGING
 PERFORMED BY**

Rebecca Hamilton

HOSPITAL NAME

Rockaway AH

REFERRING VET

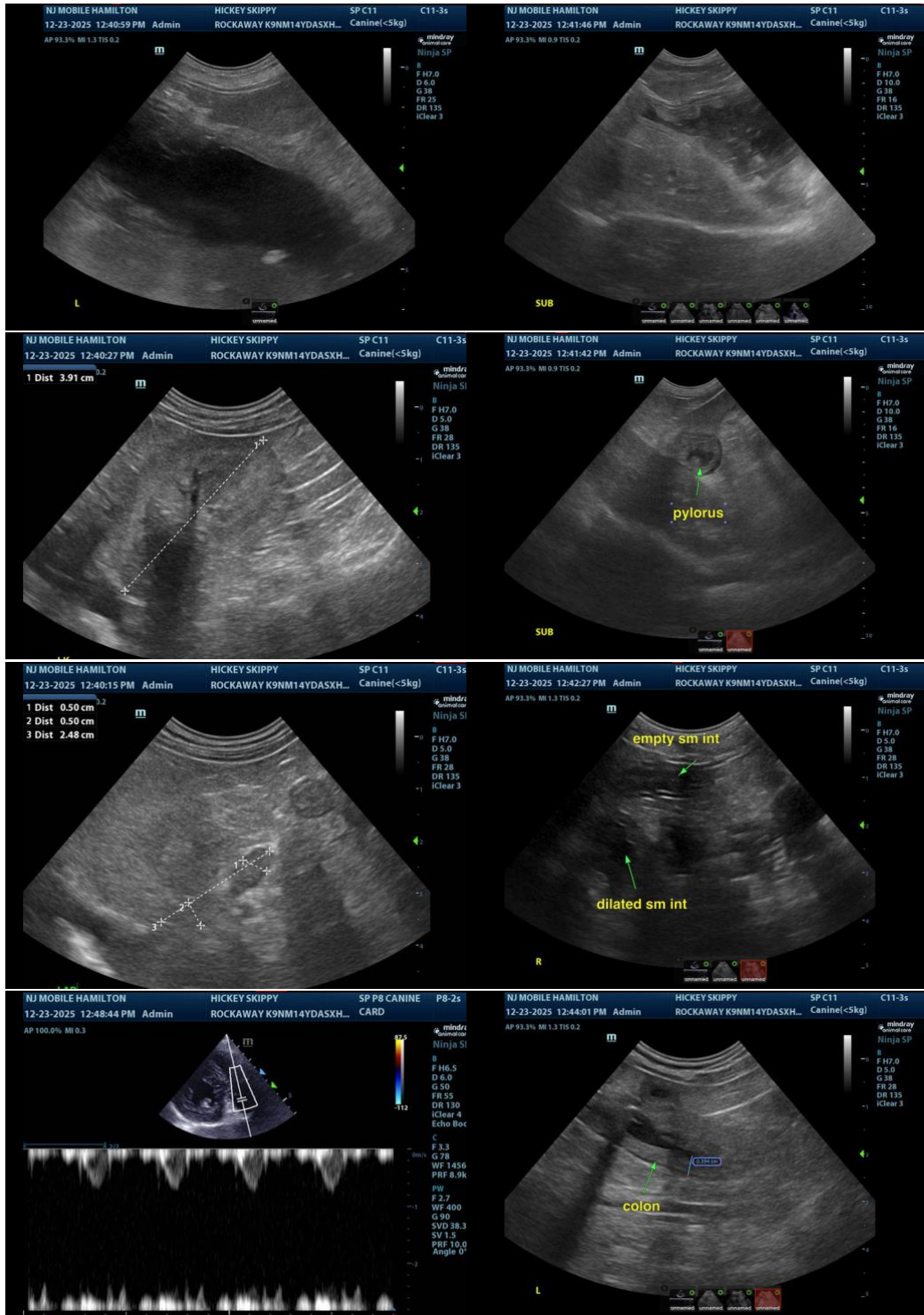
Dr. Dubos

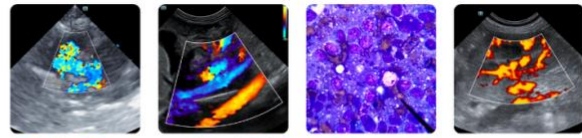
INVOICE

35059

DATE

12/23/25





PATIENT

Skippy Hickey

SPECIES

Canine

BREED

Dachshund Mix

SEX

Neutered Male

AGE

14 Years

WEIGHT

9.8 Pounds

INTERPRETED BY

Eric Lindquist, DMV,
 DABVP (Canine &
 Feline), Cert. IVUSS

IMAGING PERFORMED BY

Rebecca Hamilton

HOSPITAL NAME

Rockaway AH

REFERRING VET

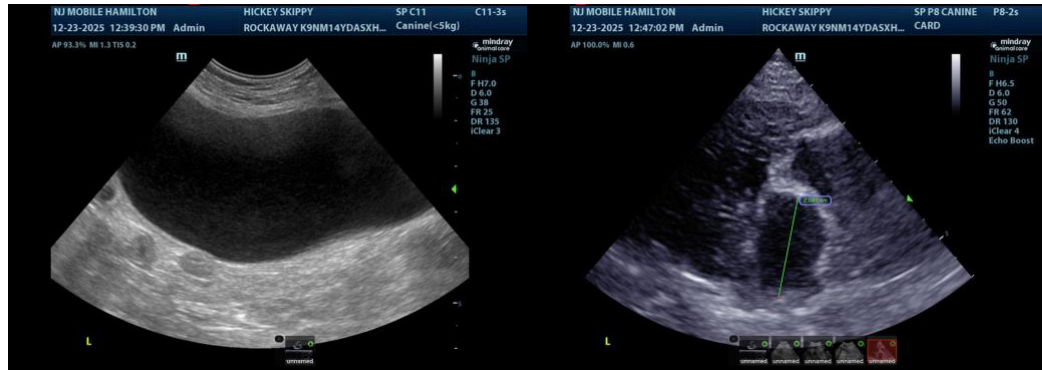
Dr. Dubos

INVOICE

35059

DATE

12/23/25



The information and recommendations provided are based on the images presented by the referring veterinarian/sonographer. No evaluation can be communicated regarding pathology that was not visible in the image/video clips provided.

Thank you for this referral. If the clinical or image interpretation does not parallel your findings or if I can be of any further assistance please contact me.

Eric Lindquist, DMV, DABVP(CFM), Cert. IVUSS,
 CEO, Owner, Founder -- SonoPath.com
info@SonoPath.com