

PATIENT

Princess Griffn

SPECIES

Feline

BREED

Domestic Shorthair

SEX

Spayed female

AGE

2021

WEIGHT

10 lbs

INTERPRETED BY

Eric Lindquist, DMV
 DABVP, Cert. IVUSS

IMAGING PERFORMED BY

Denise Bruno, LVT,
 RDMS

HOSPITAL NAME

Ideal Pet Vet

REFERRING VET

Dr. Kolta

INVOICE

69569

DATE

12/23/25

PRESENTING CLINICAL SIGNS

History: History of a large Mammary mass - cranial Left. Radiographs suggested imaging for possible lymph nodes vs mass. Mediastinal. Limited exam Chest only. Labs/X rays attached

ULTRASONOGRAPHIC EXAMINATION

Three videos and 9 still images were submitted

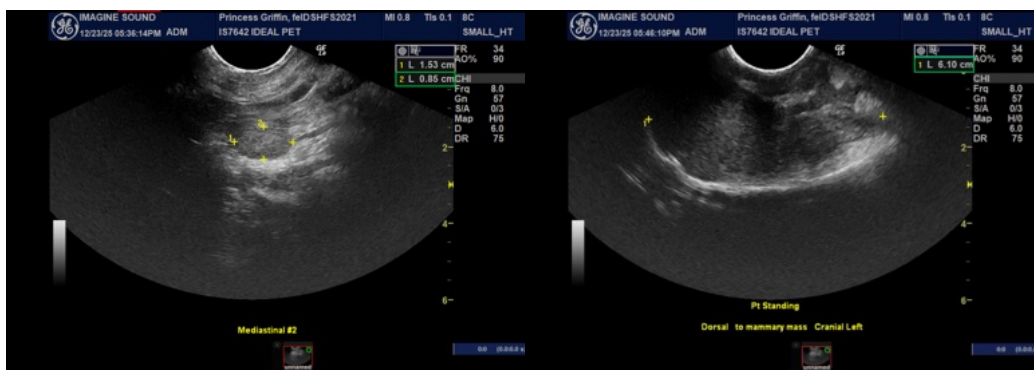
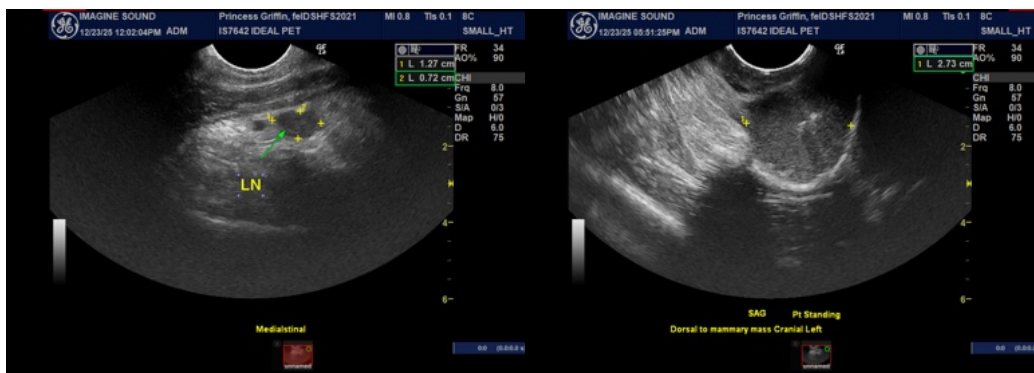
Multiple mammary masses were noted in this patient measuring up to 2.7 cm and 6.1 cm with mixed echogenic, ill-defined margins extending into the regional fascia and subcutaneous space. Cranial mediastinal lymph nodes were enlarged and measured up to 1.27 cm and 1.53 cm. They were rounded, hypoechoic and irregular. This is strongly suggestive for metastatic disease.

ULTRASONOGRAPHIC FINDINGS

- Aggressive mammary masses with cranial mediastinal lymphadenopathy.

INTERPRETATION OF THE FINDINGS & FURTHER RECOMMENDATIONS

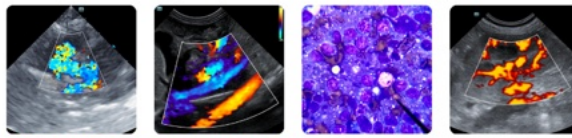
There is a strong concern for metastatic disease. Ultrasound-guided FNA of the cranial mediastinal masses would be ideal as well as the mammary masses for correlation of pathology.



Imaging
performed by



dbimaginesound@gmail.com
917-647-4318



Clinical Sonography & Telectology
Educational Teleconsultation Services™

SonoPath

FOSTERING THE ART OF VETERINARY MEDICINE™

SonoPath.com info@sonopath.com 1.800.838.4268

PATIENT

Princess Griffifn

The information and recommendations provided are based on the images presented by the referring veterinarian/sonographer. No evaluation can be communicated regarding pathology that was not visible in the image/video clips provided.

SPECIES

Feline

Thank you for this referral. If the clinical or image interpretation does not parallel your findings or if I can be of any further assistance please contact me.

Eric Lindquist, DMV, DABVP, Cert. IVUSS, CEO of SonoPath.com

BREED

Domestic Shorthair

info@SonoPath.com

SEX

Spayed female

AGE

2021

WEIGHT

10 lbs

INTERPRETED BY

Eric Lindquist, DMV
DABVP, Cert. IVUSS

**IMAGING
PERFORMED BY**

Denise Bruno, LVT,
RDMS

HOSPITAL NAME

Ideal Pet Vet

REFERRING VET

Dr. Kolta

INVOICE

69569

DATE

12/23/25