



## PATIENT

Honeypot Rundle

## SPECIES

Canine

## BREED

Pembroke Welsh Corgi

## SEX

Spayed female

## AGE

3 years

## WEIGHT

25.7 lbs

## INTERPRETED BY

Eric Lindquist, DMV  
DABVP, Cert. IVUSS

## IMAGING PERFORMED BY

Jill Rumachik

## HOSPITAL NAME

Clarity Imaging LLC

## REFERRING VET

Dr. Hoffman

## INVOICE

69560

## DATE

12/23/25

## PRESENTING CLINICAL SIGNS

History: Persistent on/off hematuria since July 2025. No outward urinary signs at home except for new aggression with other dogs when sniffing her hind end. Hematuria originally found on routine screening. Concern for renal casts in urine as well.

## ULTRASONOGRAPHIC EXAMINATION OF THE ABDOMEN

### *Urinary System*

The **urinary bladder**, trigone, and pelvic urethra presented normal thicknesses and normal tone. The pelvic urethra was imaged 3.0 cm beyond the cystourethral junction and appeared normal. The ureters were not visible which is normal. No uroliths or sediment were visualized and anechoic urine was present. No evidence of inflammatory or neoplastic changes was noted. Ureteral papillae were normal.

The **kidneys** revealed normal size and structure, corticomedullary definition and ratio for this age. The cortices presented largely uniform texture with normal echogenic relationship to liver and spleen. Medullary structure differed distinctly from the cortex and no evidence of pelvic dilation was present. The capsules were acceptably uniform without significant irregularities. The left kidney measured 5.08 cm and the right kidney measured 5.21 cm.

### *Adrenal Glands*

The **left adrenal gland** was visualized and recognized as having normal shape, size, position and echogenicity for this breed. The phrenic vasculature, glandular echogenicity and detail were unremarkable. Capsule, cortex, and medullary definition were normal for this age patient. The left adrenal gland measured 0.5 cm. The **right adrenal gland** was not overtly visualized; however, the region of the right adrenal gland appeared unremarkable.

### *Spleen*

The **spleen** presented a smooth homogeneous parenchyma hyperechoic to liver and renal cortical parenchyma. The capsule was smooth without noticeable expansion or deviation from within the spleen or adjacent pathology. The splenic vasculature demonstrated normal volume without signs of congestion or thrombosis. No sonographic evidence of acute or chronic inflammatory, neoplastic, or infarctual changes was noted.

### *Liver*

The **liver** images submitted revealed subjectively normal liver size, contour, and structure. Parenchymal echogenicity was naturally coarse and hypoechoic to the spleen. Vascular and biliary tracts were of normal volume with no evidence of congestion. The gallbladder presented acceptably thin walls with primarily anechoic content. The cystic and common bile ducts were normal. No pathological hepatic lymphadenopathy was evident. No overt structural evidence of inflammatory, infiltrative or regenerative pathology was evident.



## PATIENT

HoneyPot Rundle

## SPECIES

Canine

## BREED

Pembroke Welsh Corgi

## SEX

Spayed female

## AGE

3 years

## WEIGHT

25.7 lbs

## INTERPRETED BY

Eric Lindquist, DMV  
DABVP, Cert. IVUSS

## IMAGING PERFORMED BY

Jill Rumachik

## HOSPITAL NAME

Clarity Imaging LLC

## REFERRING VET

Dr. Hoffman

## INVOICE

69560

## DATE

12/23/25

## Gastrointestinal

There was some residual chyme and gas was noted in the **stomach**, yet not pathological. This is consistent with post prandial presentation. Transit of chyme into the small intestine was normal. Curvilinear patterns were maintained throughout the GI tract. No evidence of pathology. Small and large intestine demonstrated normal luminal chyme and stool consistency respectively. No obstructive or overt infiltrative disease was noted. No associated abnormal lymphatic activity was noted.

## Pancreas

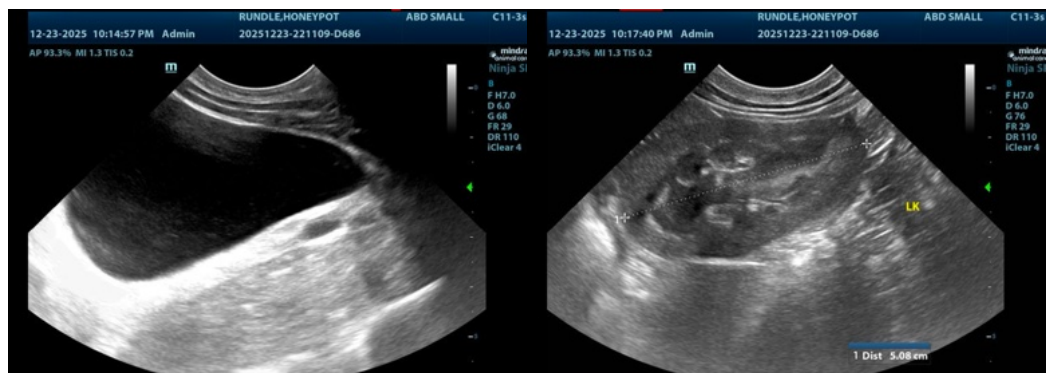
The base and limbs of the **pancreas** were observed to be largely isoechoic to surrounding omental fat. Pancreatic duct and capsular contour were acceptably normal and parenchyma respected normal curvilinear patterns. No overt evidence of active inflammatory or neoplastic disease was noted.

## ULTRASONOGRAPHIC FINDINGS

Structurally unremarkable abdomen.

## INTERPRETATION OF THE FINDINGS & FURTHER RECOMMENDATIONS

There was no evidence of the cause of hematuria. Occult UTI and occult coagulopathy is possible, yet structurally the kidneys and the remainder of the urinary tract appear normal.





**PATIENT**

Honeypot Rundle

**SPECIES**

Canine

**BREED**

Pembroke Welsh Corgi

**SEX**

Spayed female

**AGE**

3 years

**WEIGHT**

25.7 lbs

**INTERPRETED BY**

Eric Lindquist, DMV  
DABVP, Cert. IVUSS

**IMAGING PERFORMED BY**

Jill Rumachik

**HOSPITAL NAME**

Clarity Imaging LLC

**REFERRING VET**

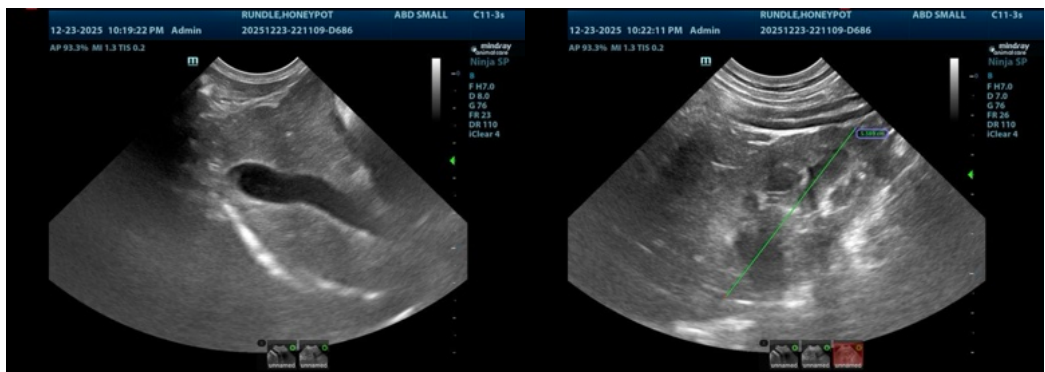
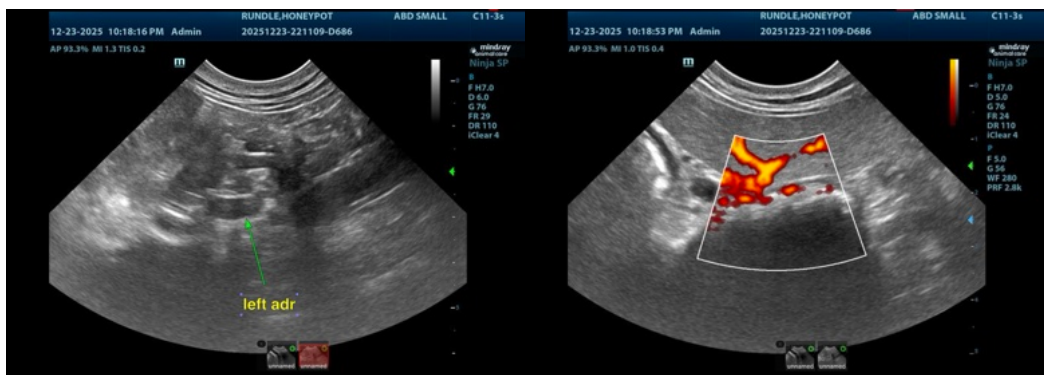
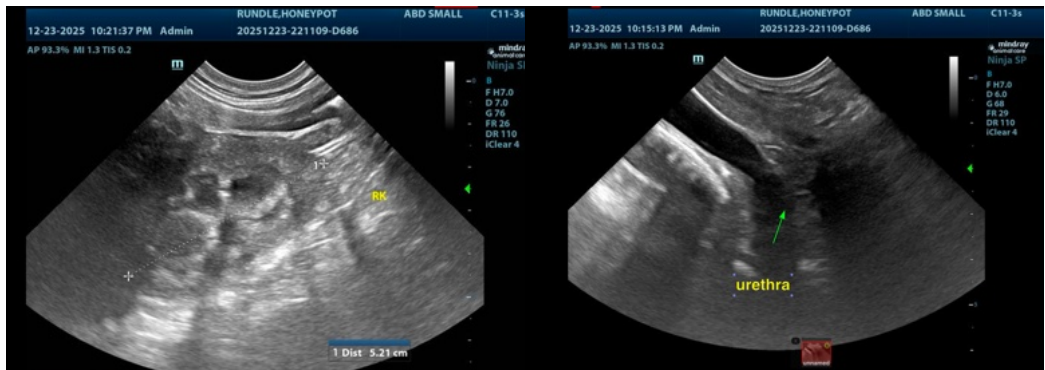
Dr. Hoffman

**INVOICE**

69560

**DATE**

12/23/25



The information and recommendations provided are based on the images presented by the referring veterinarian/sonographer. No evaluation can be communicated regarding pathology that was not visible in the image/video clips provided.

Thank you for this referral. If the clinical or image interpretation does not parallel your findings or if I can be of any further assistance please contact me.

Eric Lindquist, DMV, DABVP (CFM), Cert. IVUSS, CEO of SonoPath.com

[info@SonoPath.com](mailto:info@SonoPath.com)