



PATIENT

Riley Brown

SPECIES

Canine

BREED

French Bulldog

SEX

Spayed Female

AGE

10 Years

WEIGHT

21 Pounds

INTERPRETED BY

Eric Lindquist, DMV
DABVP, Cert. IVUSS

**IMAGING
PERFORMED BY**

Dr. Desen Ertunc

HOSPITAL NAME

Healing Spirit Animal
Wellness

REFERRING VET

Dr. Desen Ertunc

INVOICE

20238

DATE

12/23/22

PRESENTING CLINICAL SIGNS

History: Diagnosed high grade lymphoma based on cytology from unilaterally enlarged mandibular L/N. Clinically doing well, initiating CHOP protocol.

Abnormal PE/Chem/CBC/UA Results: PE- L mandibular L/N firm, enlarged, otherwise normal CBC/Chem WNL Cytology of L/N: High grade lymphoma Flow cytology pending U/A: RBC sin sediment, otherwise NSF. Urine culture pending

ULTRASONOGRAPHIC EXAMINATION OF THE ABDOMEN

Urinary System

The **urinary bladder**, trigone, and pelvic urethra presented normal thicknesses and normal tone. The ureters were not visible which is normal. No uroliths or sediment were visualized, and anechoic urine was present. No evidence of inflammatory or neoplastic changes were noted. Ureteral papillae were normal.

The **kidneys** revealed largely normal size and structure, corticomedullary definition and ratio (cortex 1/3 of medulla) were essentially maintained with some moderate age-related loss of curvilinear patterns regarding the capsule and C/M junction. The cortices presented largely uniform texture with some increased echogenicity expected for his age patient. Medullary structure differed distinctly from that of the cortex and no evidence of pelvic dilation was present. The right kidney measured 5.0 cm. The left kidney measured 5.0 cm.

Adrenal Glands

Both **adrenal glands** were visualized and recognized as having normal shape, size, position and echogenicity for this breed. The phrenic vasculature, glandular echogenicity and detail were unremarkable. Capsule, cortex, and medullary definition were normal for this age patient. The right adrenal gland measured 2.14 cm x 1.74 cm at the cranial pole and 0.53 cm at the caudal pole. The left adrenal gland measured 0.59 cm.

Spleen

The **spleen** presented a smooth homogeneous parenchyma hyperechoic to liver and renal cortical parenchyma. The capsule was smooth without noticeable expansion or deviation from within the spleen or adjacent pathology. The splenic vasculature demonstrated normal volume without signs of congestion or thrombosis. No sonographic evidence of acute or chronic inflammatory, neoplastic, or infarctual changes were noted.

Liver

The **liver** images from right and left intercostal as well as subcostal views revealed subjectively normal liver size, contour, and structure. Some mild age-related parenchymal remodeling was noted but likely not clinically significant at this time. Vascular and biliary tracts were of normal volume and no evidence of congestion was noted. The gallbladder presented some dependent debris with essentially normal contour. The cystic and common bile ducts were normal. No overt evidence of active inflammatory, infiltrative or regenerative pathology was noted but should be paired with current or past LE elevations regarding any clinical significance to this presentation. The hepatic lymph nodes were unremarkable.



PATIENT

Riley Brown

SPECIES

Canine

BREED

French Bulldog

SEX

Spayed Female

AGE

10 Years

WEIGHT

21 Pounds

INTERPRETED BY

Eric Lindquist, DMV
DABVP, Cert. IVUSS

IMAGING PERFORMED BY

Dr. Desen Ertunc

HOSPITAL NAME

Healing Spirit Animal
Wellness

REFERRING VET

Dr. Desen Ertunc

INVOICE

20238

DATE

12/23/22

Gastrointestinal

Examination of the **gastrointestinal tract** revealed a stomach and intestine free of stasis, of normal wall thickness, acceptable curvilinear mural detail, and peristaltic activity. Small and large intestine demonstrated normal luminal chyme and stool consistency respectively. No obstructive or overt infiltrative disease was noted. No associated abnormal lymphatic activity was noted.

Pancreas

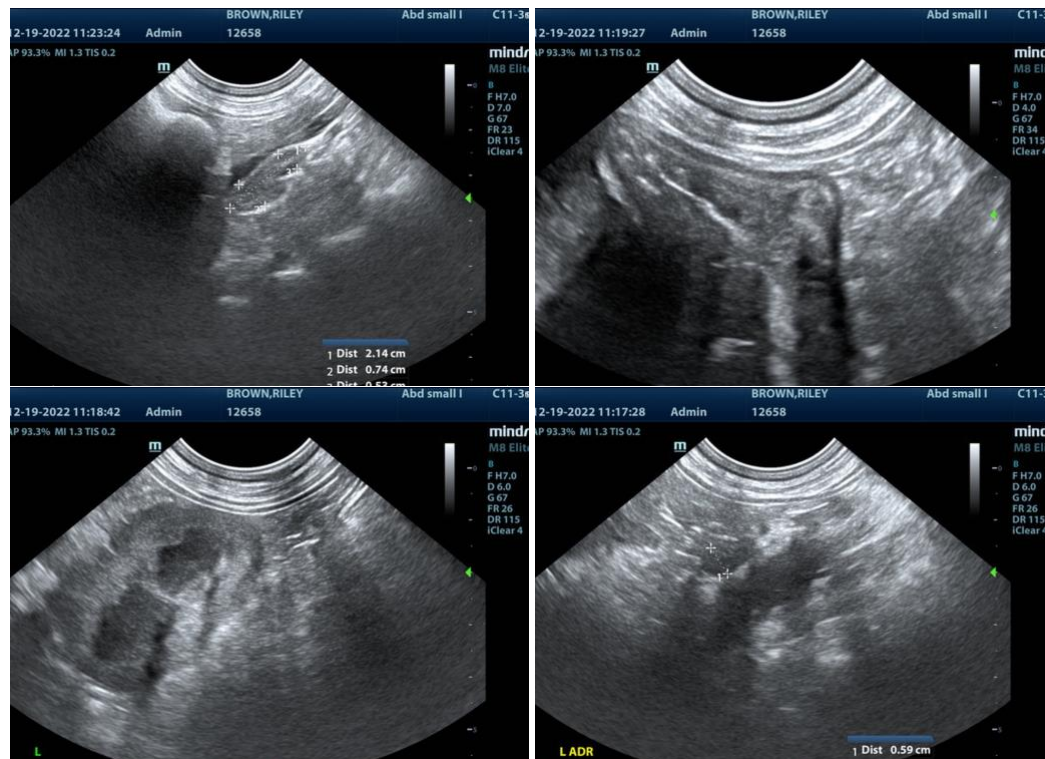
The base and limbs of the **pancreas** were observed to be largely isoechoic to surrounding omental fat. Some mild parenchymal remodeling, however, with mild deviation from curvilinear normalcy was observed. Pancreatic duct and capsular irregularities were present consistent with age related changes. If pain upon imaging (+ Murphy sign) was present or if the patient is focally painful in subxyphoid palpation then low-grade smoldering chronic pancreatitis should be suspected.

ULTRASONOGRAPHIC FINDINGS

- Structurally unremarkable abdomen with age related abdominal changes

INTERPRETATION OF THE FINDINGS & FURTHER RECOMMENDATIONS

No structural evidence of lymphoma or other pathology. These are expected changes for this age patient.





PATIENT

Riley Brown

SPECIES

Canine

BREED

French Bulldog

SEX

Spayed Female

AGE

10 Years

WEIGHT

21 Pounds

INTERPRETED BY

Eric Lindquist, DMV
DABVP, Cert. IVUSS

IMAGING PERFORMED BY

Dr. Desen Ertunc

HOSPITAL NAME

Healing Spirit Animal
Wellness

REFERRING VET

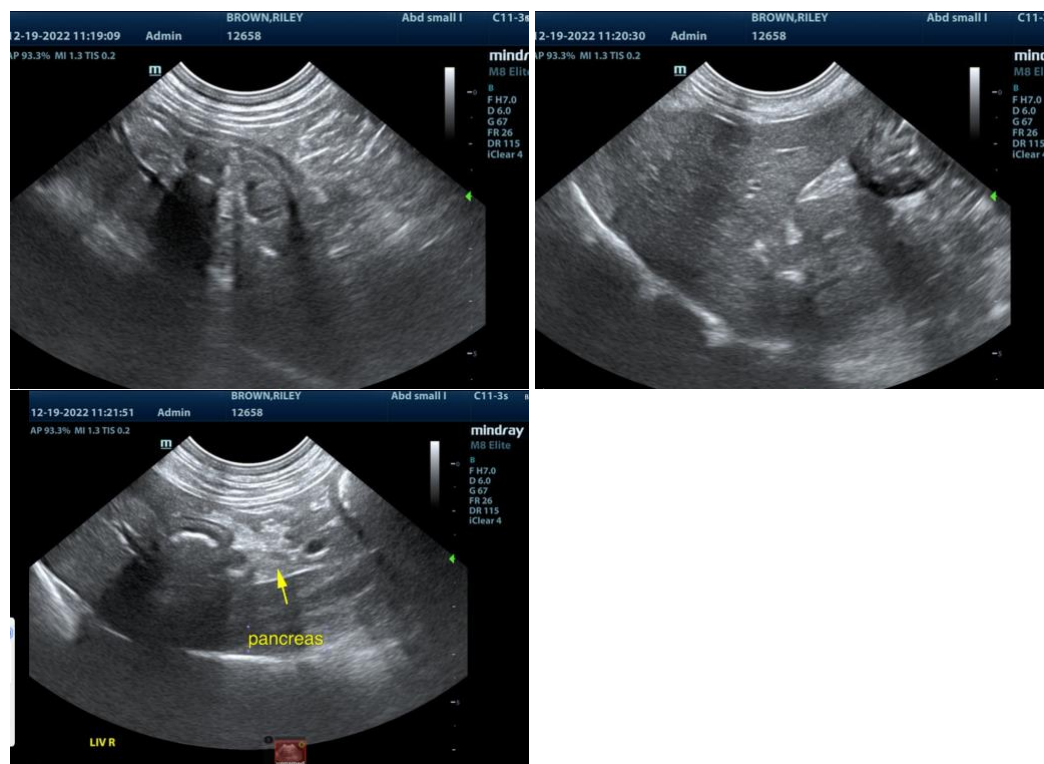
Dr. Desen Ertunc

INVOICE

20238

DATE

12/23/22



The information and recommendations provided are based on the images presented by the referring veterinarian. No evaluation can be communicated regarding pathology that was not visible in the image/video clips provided.

Thank you for this referral. If the clinical or image interpretation does not parallel your findings or if I can be of any further assistance please contact me.

Eric Lindquist, DMV, DABVP, Cert. IVUSS, CEO of SonoPath.com
info@SonoPath.com