



PATIENT

Pedro Duncan

SPECIES

Canine

BREED

Chihuahua

SEX

Neutered Male

AGE

10 Years

WEIGHT

4.9 kg

INTERPRETED BY

Eric Lindquist, DMV
DABVP, Cert. IVUSS

IMAGING PERFORMED BY

Dr. McFarlen

HOSPITAL NAME

Van Isle VH

REFERRING VET

Dr. McFarlen

INVOICE

20240

DATE

12/23/22

PRESENTING CLINICAL SIGNS

History: Practice scan, grade 3 HM systolic with some episodes of cyanosis after running (noted by tech at her home).

Abnormal PE/Chem/CBC/UA Results: PE: grade 3 HM alt alp mild elevations long standing. history of pancreatitis

ULTRASONOGRAPHIC EXAMINATION OF THE HEART

| CANINE CARDIAC PARAMETERS | MR VMAX (m/s) | TR VMAX (m/s) | LA/AO (Boon method) | LA/AO (Heart Base; Swe) | FS (%) | EF (%) | EPSS (cm) |
|---------------------------|---------------|---------------|---------------------|-------------------------|---------------------------------|--|--|
| NORMAL PARAMETER | 4.5-5.5 | <2.7 | 1.3 | <1.3 | 28-40 | 40-100 | <0.6 |
| PATIENT | 5.8 | 3.0 | 1.28 | 1.31 | 39 | 63 | NM |
| CANINE CARDIAC PARAMETERS | HR (BPM) | AV VMAX (m/s) | PV MAX (m/s) | BODY WEIGHT (kg) | LA 2D short axis Base view (cm) | LVIDd Avg; 2D and m-mode short axis (cm) | LVIDs Avg; 2D and m-mode short axis (cm) |
| NORMAL PARAMETER | 50-100 | 0.7-1.7 | 0.7-1.6 | | | | |
| PATIENT | -- | 1.30 | .60 | -- | 2.11 | 2.16 | -- |

Cardiac Presentation

The echocardiogram in this patient demonstrated normal **left atrial** size based on 3 different LA measurement methods. Chamber volumes and echogenicity were normal. The cranial and caudal **mitral** valve leaflets presented vegetative thickening consistent with endocardiosis. Doppler indicated minor centralized insufficiency. The **left ventricle** presented thicknesses with linear contour and was not dilated nor restricted. The **myocardium** presented normal echogenicity without subjective evidence of significant fibrotic or ischemic disease. **Contractility** of the ventricular walls was adequate and in normal range for this patient evidenced by the fractional shortening measurement and subjective evaluation of the different regions of the myocardium. The **left ventricular outflow** tract demonstrated normal laminar flow and subjective structural integrity. The **right atrium** was slightly enlarged in this patient (1:1 ration with the left atrium) given the appearance of right sided cardiomegaly on radiographs. **Tricuspid** insufficiency was noted. The **right ventricle** was of normal size (1/3 diameter of LV), chordae structure, myocardial echogenicity and thickness. **Pulmonic** tract assessment revealed normal valve structure, laminar flow, and diameter (approx. 1:1 pa/ao ratio). No visible **pericardial** or free pleura fluid was noted. No echographically detectable evidence of infiltrative disease was visible. The cranial **mediastinum and pericardial regions** were free of masses in the visible window. The hepatic veins were not dilated.

ULTRASONOGRAPHIC FINDINGS



PATIENT

- Mitral and tricuspid insufficiency

Pedro Duncan

INTERPRETATION OF THE FINDINGS & FURTHER RECOMMENDATIONS

SPECIES

Canine

Tricuspid insufficiency velocity is that of mild pulmonary hypertension. This is not likely a clinical issue, even given the clinical signs. I do not recommend Sildenafil at this point. Obstructive respiratory disease should be considered in this patient as the cause of the clinical signs. The tricuspid insufficiency/very early pulmonary hypertension should be monitored over the next 3-6 months, especially to assess any progressive hepatic vein dilation yet I believe this is consistent with nonclinical stage B-1 valvular disease.

BREED

Chihuahua

The heart is stable without clinical disease. No overt contraindication for anesthesia of brief to moderate duration. I suggest Torbutrol premed, Propofol induction, Isoflor maintenance or similar protocol if anesthesia is desired. Blood pressure recommended if not already performed and target white coat negative systolic pressure of < 160 mmHg. If higher than this ACE-inhibitor is suggested to reach this level. Recheck echocardiogram is recommended in 6 months, earlier if murmur grade increases or clinical signs initiate.

AGE

10 Years

WEIGHT

4.9 kg

INTERPRETED BY

Eric Lindquist, DMV
DABVP, Cert. IVUSS

IMAGING PERFORMED BY

Dr. McFarlen

HOSPITAL NAME

Van Isle VH

REFERRING VET

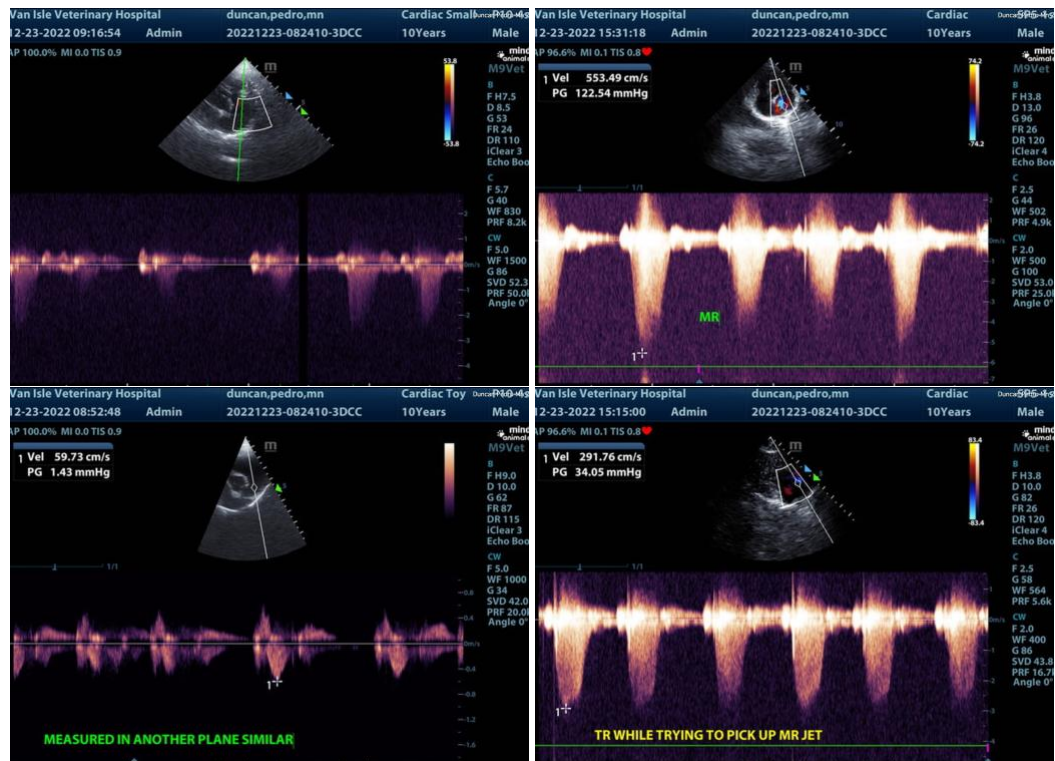
Dr. McFarlen

INVOICE

20240

DATE

12/23/22





PATIENT

Pedro Duncan

SPECIES

Canine

BREED

Chihuahua

SEX

Neutered Male

AGE

10 Years

WEIGHT

4.9 kg

INTERPRETED BY

Eric Lindquist, DMV
DABVP, Cert. IVUSS

IMAGING PERFORMED BY

Dr. McFarlen

HOSPITAL NAME

Van Isle VH

REFERRING VET

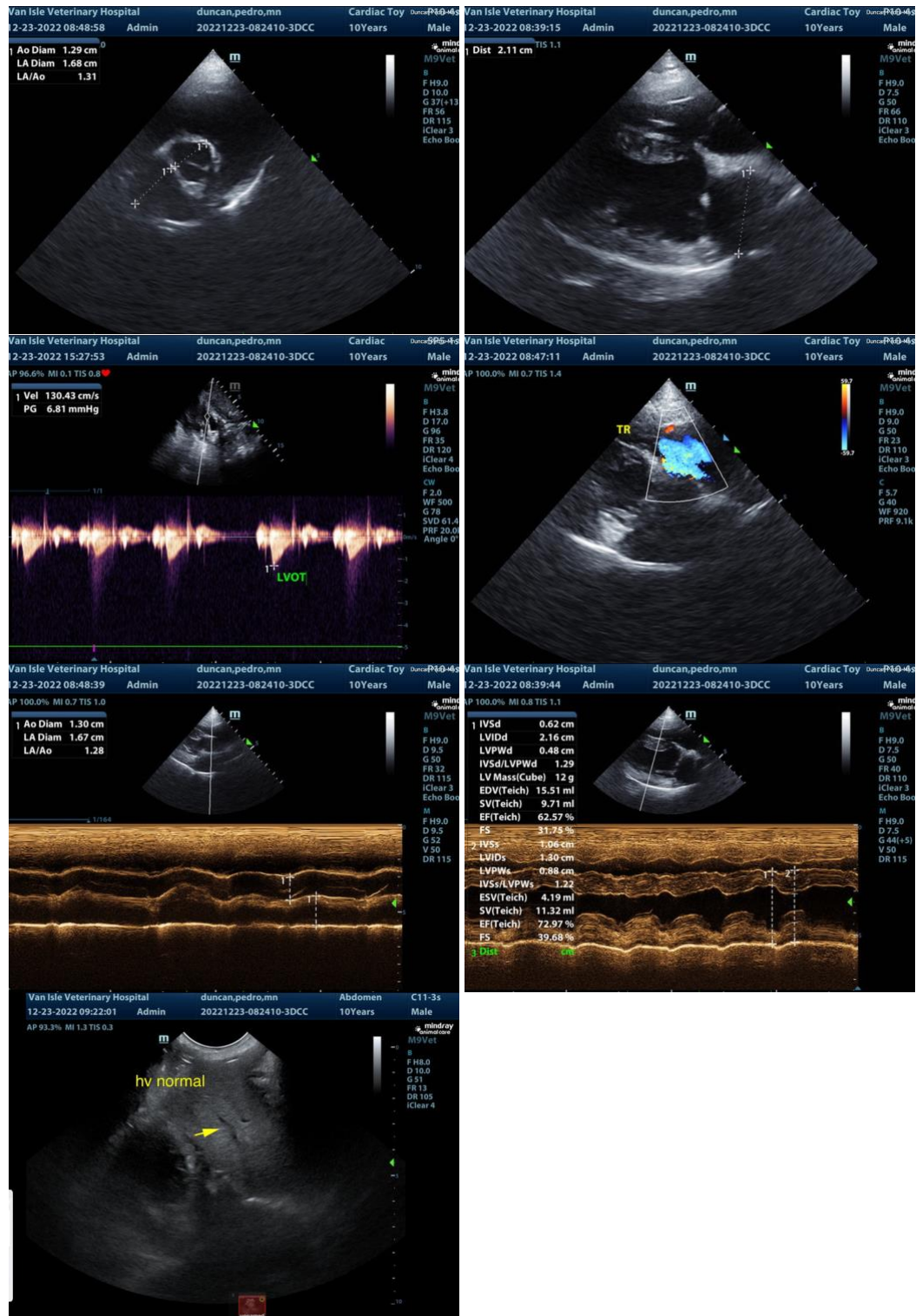
Dr. McFarlen

INVOICE

20240

DATE

12/23/22



The information and recommendations provided are based on the images presented by the referring veterinarian. No evaluation can be communicated regarding pathology that was not visible in the image/video clips provided.



PATIENT

Pedro Duncan

Thank you for this referral. If the clinical or image interpretation does not parallel your findings or if I can be of any further assistance please contact me.

SPECIES

Canine

Eric Lindquist, DMV, DABVP, Cert. IVUSS, CEO of SonoPath.com
info@SonoPath.com

BREED

Chihuahua

SEX

Neutered Male

AGE

10 Years

WEIGHT

4.9 kg

INTERPRETED BY

Eric Lindquist, DMV
DABVP, Cert. IVUSS

**IMAGING
PERFORMED BY**

Dr. McFarlen

HOSPITAL NAME

Van Isle VH

REFERRING VET

Dr. McFarlen

INVOICE

20240

DATE

12/23/22