


PATIENT

Kevin Lawlor

PRESENTING CLINICAL SIGNS

New heart murmur, R/O primary heart dz vs stress induced no clinical signs at home

SPECIES

Feline

Abnormal PE/Chem/CBC/UA Results: none

BREED

DSH

ULTRASONOGRAPHIC EXAMINATION OF THE HEART
SEX

MN

AGE

4

WEIGHT

13

FELINE CARDIAC PARAMETERS	BODY WEIGHT (kg)	HR (BPM)	IVSd (cm)	LVIDd (cm)	LVWd (cm)	FS (%)	EF (%)
NORMAL PARAMETER	-----	150-240	0.3-0.6	1.0-2.1	0.25-0.6	35-67	80-100
PATIENT		192	0.45	1.46	0.6	63	93
FELINE CARDIAC PARAMETERS	LA/AO (Boon)	LA/AO HEART BASE (Sisson)	LA 2D 4-chamber long axis AS to FW (Sisson) (cm)	LVOT VEL. (m/s)	RVOT VEL. (m/s)	IVRT (m/)	
NORMAL PARAMETER	<1.5	0.88-1.79	0.7-1.7	<1.6	<1.3	40-60	
PATIENT	1.3	1.1			1.0		

Adapted from June Boon, Veterinary Echocardiography, 1998
 Sisson D et al. JVIM 1991; 5: 232, Jacobs et al. Am J Vet Res 1985; 46:1705

INTERPRETED BY

 Eric Lindquist, DMV
 DABVP, Cert. IVUSS

Cardiac Presentation

The echocardiogram in this patient demonstrated normal left atrial size based on 3 separate LA measurements. The cranial and caudal mitral valve leaflets presented normal linear structure and kinetics. The left ventricle presented normal thicknesses with linear contour and was not dilated nor restricted. The myocardium presented normal echogenicity without subjective evidence of significant fibrotic or ischemic disease. Contractility of the ventricular walls was adequate and in normal range for this patient evidenced by the fractional shortening measurement and subjective evaluation of the different regions and angles of the myocardium. The left ventricular outflow tract demonstrated normal laminar flow and subjective structural integrity. The right atrium and auricle revealed normal size, structure and content. No evidence of masses was noted or chamber overload. Tricuspid valvular assessment demonstrated adequate linear morphology and kinetics. The right ventricle was of normal size (1/3 diameter of LV), chordae structure, myocardial echogenicity and thickness. Pulmonic tract assessment revealed normal valve structure, laminar flow, and diameter (approx. 1:1 pa/ao ratio). No visible pericardial or free pleura fluid was noted or extra cardiac pathology in the visible planes. The cranial mediastinum and pericardial regions were free of masses in the visible window.

IMAGING PERFORMED BY

Jenn

HOSPITAL NAME

 Rockaway Animal
 Hospital

REFERRING VET

Dr. Maniar

ULTRASONOGRAPHIC FINDINGS

- Normal echocardiogram

INVOICE

12524ag

INTERPRETATION OF THE FINDINGS & FURTHER RECOMMENDATIONS

No evidence of pathology was present in this study.

DATE

12/23/2022



PATIENT

Kevin Lawlor

SPECIES

Feline

BREED

DSH

SEX

MN

AGE

4

WEIGHT

13

INTERPRETED BY

Eric Lindquist, DMV
DABVP, Cert. IVUSS

IMAGING PERFORMED BY

Jenn

HOSPITAL NAME

Rockaway Animal
Hospital

REFERRING VET

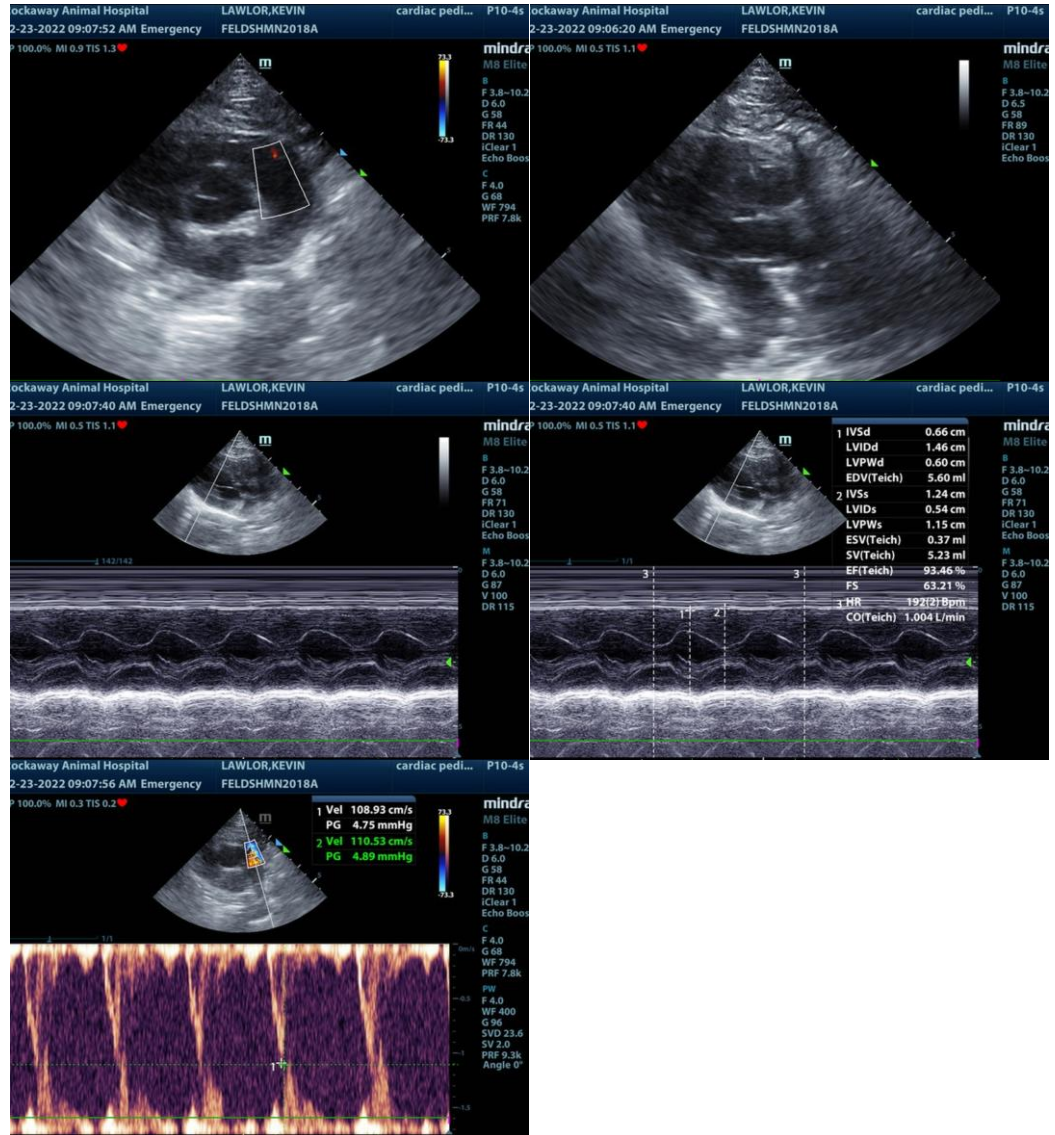
Dr. Maniar

INVOICE

12524ag

DATE

12/23/2022



The information and recommendations provided are based on the images presented by the referring veterinarian. No evaluation can be communicated regarding pathology that was not visible in the image/video clips provided.

Thank you for this referral. If the clinical or image interpretation does not parallel your findings or if I can be of any further assistance please contact me.

Eric Lindquist, DMV, DABVP, Cert. IVUSS, CEO of SonoPath.com
Eric.Lindquist@SonoPath.com



PATIENT

Kevin Lawlor

SPECIES

Feline

BREED

DSH

SEX

MN

AGE

4

WEIGHT

13

INTERPRETED BY

Eric Lindquist, DMV
DABVP, Cert. IVUSS

**IMAGING
PERFORMED BY**

Jenn

HOSPITAL NAME

Rockaway Animal
Hospital

REFERRING VET

Dr. Maniar

INVOICE

12524ag

DATE

12/23/2022