



**PATIENT**

Colbert Ostrem

**SPECIES**

Canine

**BREED**

Australian Cattle

**SEX**

Neutered Male

**AGE**

8 Years 1 Month

**WEIGHT**

35.9 Pounds

**INTERPRETED BY**

Eric Lindquist, DMV  
DABVP, Cert. IVUSS

**IMAGING PERFORMED BY**

Agnes Rupley, DVM

**HOSPITAL NAME**

All Pets Medical Center

**REFERRING VET**

Agnes Rupley, DVM

**INVOICE**

20239

**DATE**

12/23/22

**PRESENTING CLINICAL SIGNS**

History: PRESENTED FOR: annual wellness, testing, and vaccines. REPORTED SYMPTOM: None. VITALS: 35.9 pounds Temperature: 104.0 (normal range is 99.5 F- 102.0 F) Heart Rate: 72 bpm (normal is 70-80) Respiratory Rate: 42 bpm (normal is 15-25) Mucous Membrane Color: pink Capillary Refill Time: <2 CURRENT MEDICATIONS: ProHeart and Bravecto EXAM FINDINGS: Ultrasound guided cystocentesis performed to obtain urine sample. Thickened bladder wall (concentric), with a suspected 1.0 x 0.5cm mass on the left ventral lateral bladder wall. Iris atrophy (lacks pupillary light reflexes). Nuclear sclerosis. LAB RESULTS: Heartworm, Lyme disease, Anaplasma, and Ehrlichia disease tests did not show evidence of infection. Intestinal Parasite Screen (Fecal Float) reveals no evidence of intestinal parasites. Chemistry panel results reveal elevated albumin and slightly low globulins. CBC results indicate elevated PCV, leukopenia resulting from lymphopenia and monocytopenia however an eosinophilia is present. Urinalysis results reveal uro 2/4, protein neg/15, low numbers of red and white blood cells, calcium oxalate crystals, pH 5-6, and Specific Gravity: 1.041. ASSESSMENT AND PLAN: Abdominal ultrasound with specialist interpretation and chest x-rays are recommended.

**ULTRASONOGRAPHIC EXAMINATION OF THE ABDOMEN**

**Urinary System**

The **urinary bladder** presented a minor mucosal remodeling with slight polypoid changes. The ventral caudal bladder wall revealed a 1.03 cm x 0.41 cm polyp, appears stable and resectable. Slight mineralization was noted in the bladder polyp. The urethra was not visualized.

The **kidneys** revealed largely normal size and structure, corticomedullary definition and ratio (cortex 1/3 of medulla) were essentially maintained with some mild age-related loss of curvilinear patterns regarding the capsule and C/M junction. The cortices presented largely uniform texture with some increased echogenicity expected for his age patient. Medullary structure differed distinctly from that of the cortex and no evidence of pelvic dilation was present. The left kidney measured 5.97 cm. The right kidney measured 5.0 cm.

**Adrenal Glands**

Both **adrenal glands** were visualized and recognized as having normal shape, size, position and echogenicity for this breed. The phrenic vasculature, glandular echogenicity and detail were unremarkable. Capsule, cortex, and medullary definition were normal for this age patient. The left adrenal gland measured 2.2 cm x 0.83 cm at the cranial pole and 0.6 cm at the caudal pole. The right adrenal gland measured 0.5 cm.

**Spleen**

The **spleen** presented a smooth homogeneous parenchyma hyperechoic to liver and renal cortical parenchyma. The capsule was smooth without noticeable expansion or deviation from within the spleen or adjacent pathology. The splenic vasculature demonstrated normal volume without signs of congestion or thrombosis. No sonographic evidence of acute or chronic inflammatory, neoplastic, or infarctual changes were noted.

**Liver**

The **liver** images submitted revealed subjectively normal liver size, contour, and structure. Parenchymal echogenicity was naturally coarse and hypoechoic to the spleen. Vascular and biliary



## PATIENT

Colbert Ostrem

tracts were of normal volume with no evidence of congestion. The gallbladder presented acceptably thin walls with primarily anechoic content. The cystic and common bile ducts were normal. No pathological hepatic lymphadenopathy was evident. No overt structural evidence of inflammatory, infiltrative or regenerative pathology was evident.

## SPECIES

Canine

## Gastrointestinal

A minor amount of ingesta was noted in the **stomach**. The small intestine and colon were unremarkable.

## BREED

Australian Cattle

## Pancreas

The base and limbs of the **pancreas** were observed to be largely isoechoic to surrounding omental fat. Pancreatic duct and capsular contour were acceptably normal and parenchyma respected normal curvilinear patterns. No overt evidence of active inflammatory or neoplastic disease was noted.

## SEX

Neutered Male

## ULTRASONOGRAPHIC FINDINGS

- Urinary bladder polyp, appears resectable, strong potential for early transitional cell carcinoma. Polypoid hyperplasia is possible.
- Age-related renal changes
- Unremarkable abdomen otherwise

## AGE

8 Years 1 Month

## WEIGHT

35.9 Pounds

## INTERPRETATION OF THE FINDINGS & FURTHER RECOMMENDATIONS

The cause of fever is unclear. Traumatic catheterization could be attempted upon the bladder wall, however, direct resection would be ideal, yet it is an exceedingly small lesion.

## INTERPRETED BY

Eric Lindquist, DMV  
DABVP, Cert. IVUSS

## IMAGING PERFORMED BY

Agnes Rupley, DVM

## HOSPITAL NAME

All Pets Medical Center

## REFERRING VET

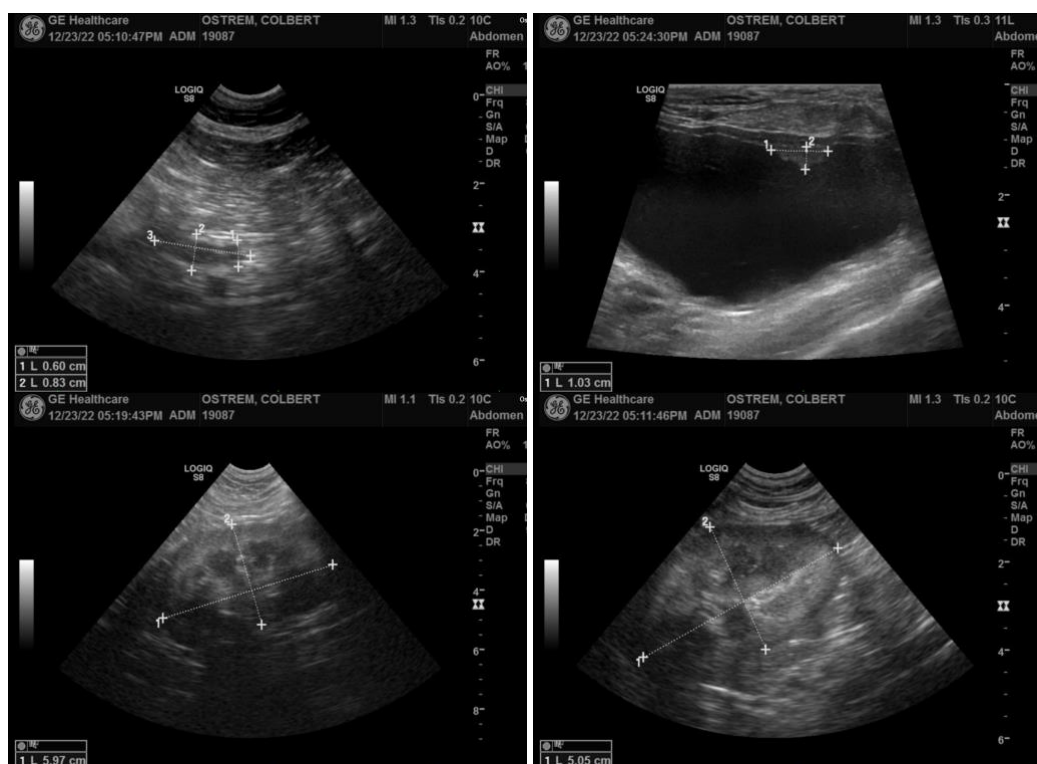
Agnes Rupley, DVM

## INVOICE

20239

## DATE

12/23/22





**PATIENT**

Colbert Ostrem

**SPECIES**

Canine

**BREED**

Australian Cattle

**SEX**

Neutered Male

**AGE**

8 Years 1 Month

**WEIGHT**

35.9 Pounds

**INTERPRETED BY**

Eric Lindquist, DMV  
DABVP, Cert. IVUSS

**IMAGING PERFORMED BY**

Agnes Rupley, DVM

**HOSPITAL NAME**

All Pets Medical Center

**REFERRING VET**

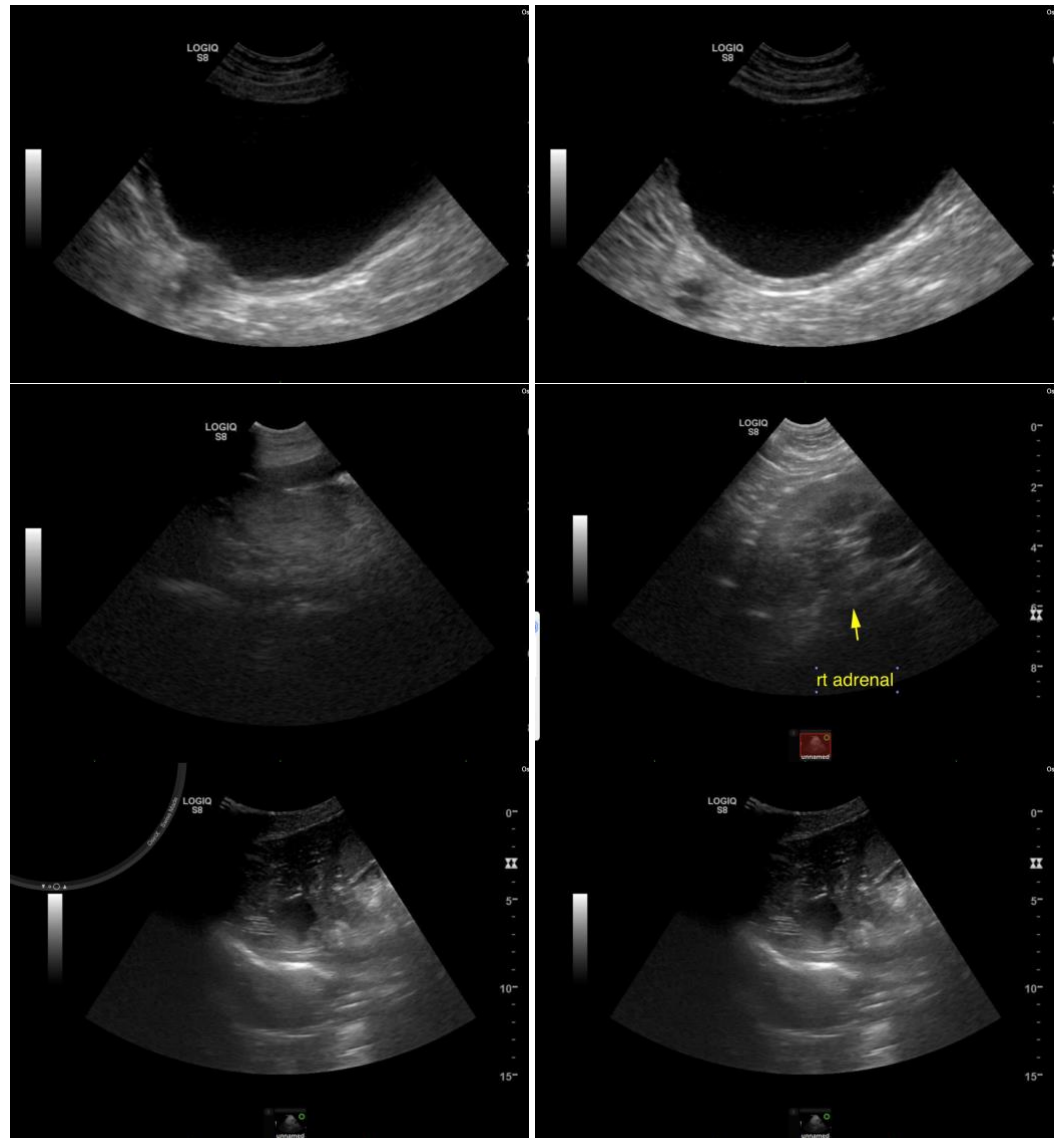
Agnes Rupley, DVM

**INVOICE**

20239

**DATE**

12/23/22



The information and recommendations provided are based on the images presented by the referring veterinarian. No evaluation can be communicated regarding pathology that was not visible in the image/video clips provided.

Thank you for this referral. If the clinical or image interpretation does not parallel your findings or if I can be of any further assistance please contact me.

**Eric Lindquist**, DMV, DABVP, Cert. IVUSS, CEO of SonoPath.com  
info@SonoPath.com

**Fever of Unknown Origin**



**PATIENT**

<http://www.sonopath.com/FUO>

Colbert Ostrem

**SPECIES**

Canine

**BREED**

Australian Cattle

**SEX**

Neutered Male

**AGE**

8 Years 1 Month

**WEIGHT**

35.9 Pounds

**INTERPRETED BY**

Eric Lindquist, DMV  
DABVP, Cert. IVUSS

**IMAGING PERFORMED BY**

Agnes Rupley, DVM

**HOSPITAL NAME**

All Pets Medical Center

**REFERRING VET**

Agnes Rupley, DVM

**INVOICE**

20239

**DATE**

12/23/22

**Description:** The definition of a fever of unknown origin (FUO) has not been clearly defined for animals. Currently, it is either understood to be a fever that does not resolve within the period one would expect for a “self-limiting infection” being treated with appropriate antimicrobial therapy, or that for which an underlying diagnosis has not been determined despite considerable diagnostic effort. The common causes of FUO were summarized concisely in a presentation at the American College of Veterinary Internal Medicine 2004 Forum. The presenters synthesized information from three veterinary papers on the subject, which suggested the following:

Final Diagnosis	Bennett (dogs & cats)	Dunn and Dunn (dogs only)	Lunn (dogs & one cat)	Total
Infection	21	16	10	47
Immune	18	22	6	46
Bone marrow disease	4	22	2	28
Neoplasia (outside marrow)	0	10	2	12
Miscellaneous	2	12	2	16
No diagnosis	0	19	2	21
<b>TOTALS</b>	<b>45</b>	<b>101</b>	<b>24</b>	<b>170</b>

The types of infection diagnosed in this case series were varied, ranging from discospondylitis (8 cases), blastomycosis (6), and bacterial endocarditis (4), to leishmaniasis (1), prostatitis (1), and *Ehrlichia canis* infection (1); a multitude of other infectious causes also fell within the spectrum. Of the cases in which immune-mediated disease was found, 44% had immune-mediated polyarthritis. Bone marrow diseases included myeloproliferative disease, myelodysplasia (8), lymphocytic leukemia (8), myeloma (3), chronic granulocytic leukemia (3), lymphoblastic leukemia, and malignant histiocytosis. The types of neoplasia located outside the bone marrow included lymphoma (6), metastatic disease (2), and neoplasms of the lung, spleen, and stomach. Finally, miscellaneous diseases included hypertrophic osteodystrophy (6), meningitis (3), portosystemic shunt (3), lymphadenitis (2), panosteitis, and intervertebral disc disease. Overall, the most common causes across all cases were polyarthritis (44), lymphoid neoplasia (15), discospondylitis (8), myelodysplasia (8), hypertrophic osteodystrophy (6), and blastomycosis (6).



**PATIENT**

Colbert Ostrem

**Clinical Signs:** Animals usually present with either persistent or waxing and waning fevers ranging from 103°F to 106°F. Other clinical signs depend on the underlying cause of the fever. Careful and thorough physical examination is required to assess potential causes.

**SPECIES**

Canine

**Diagnostics:** FUI etiologies are partly related to geography, and thus locale or travel history should factor into a practitioner's diagnostic approach. A patient's lifestyle may also provide clues regarding exposure to certain etiologic agents. Therefore, conducting a thorough history can unveil important pieces of the diagnostic puzzle. Physical examination is especially important and should include an inspection of all accessible lymph nodes, palpation and movement of the joints, a fundic examination, a neurological evaluation, spinal and limb palpation and range of motion tests, and a rectal examination.

**BREED**

Australian Cattle

**SEX**

Neutered Male

A minimum database should include a CBC reviewed by a clinical pathologist, as well as a biochemical profile and urinalysis. Retroviral testing should also be considered in cats. In areas where tick-borne disease is prevalent, in-house testing should be performed early. Advanced laboratory work can include: urine culture, blood culture, and infectious disease panels (PCR and/or serology). In dogs, one may screen for the following infectious agents: *Ehrlichia* spp., *Borrelia burgdorferi*, Rock Mountain Spotted Fever, *Bartonella* spp. (culture and PCR), and *Leptospira* spp. in cases of hepatic or renal involvement. In cats, one should evaluate for FeLV, FIV, feline infectious peritonitis (FIP) virus, toxoplasmosis, *Hemoplasma* spp. (*Mycoplasma*), and *Bartonella* spp. (culture and PCR). Testing for *Ehrlichia* spp., *Rickettsia* spp., and *Anaplasma phagocytophilum* can also be considered. A fungal assay is indicated if the patient lives in or has had exposure to a region with a higher incidence of fungal disease. Other infectious disease tests may be performed depending on the geographical location of the pet. Screening for *Brucella* should be done in breeding dogs. Immune-mediated disease screening can include a Coomb's test, a slide agglutination test (if the patient is anemic), and an antinuclear antibody (ANA) test. Immune disease is often a diagnosis of exclusion.

**AGE**

8 Years 1 Month

**WEIGHT**

35.9 Pounds

**INTERPRETED BY**

Eric Lindquist, DMV  
DABVP, Cert. IVUSS

**IMAGING PERFORMED BY**

Agnes Rupley, DVM

**HOSPITAL NAME**

All Pets Medical Center

**REFERRING VET**

Agnes Rupley, DVM

Imaging should include thoracic radiographs, abdominal ultrasound, and/or abdominal radiographs. Ultrasound can be very useful for assessing evidence of cholangiohepatitis, pyelonephritis, chronic urinary tract infection, abscess formation, peritonitis, and neoplasia; it also permits an examination of the intra-abdominal lymph nodes. An echocardiogram can offer assessment for vegetative endocarditis, whereas spinal radiographs offer assessment for discospondylitis. In cases where all other testing has proven negative and the patient has not responded to broad-spectrum antibiotics and supportive care, arthrocentesis should be considered to evaluate for septic joint disease, immune-mediated polyarthritis, and infectious disease. Finally, one can consider assessing the cerebrospinal fluid for meningoencephalitis, GME, and meningitis/arteritis. A bone marrow exam should be performed if blood dyscrasias are noted on the CBC.

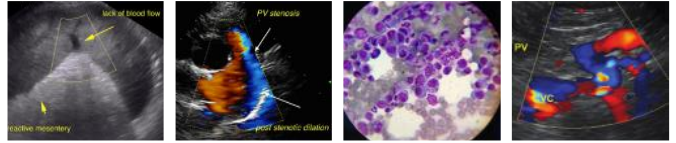
**INVOICE**

20239

**DATE**

12/23/22

**Treatment:** Treatment of the fever depends entirely on the underlying cause. Ideally, a thorough diagnostic plan will yield a diagnosis that will guide the appropriate therapeutic course. However, if an exhaustive approach has not produced a definitive diagnosis and there is no response to broad-spectrum antibiotics, trial therapy with immunosuppressive agents such as prednisolone can be considered to treat presumed immune-mediated diseases. Given the potential for negative sequelae should an underlying infection be present, one must be certain that the investigation is thorough and monitor the patient's response carefully.



**PATIENT**

Colbert Ostrem

**SPECIES**

Canine

**BREED**

Australian Cattle

**SEX**

Neutered Male

**AGE**

8 Years 1 Month

**WEIGHT**

35.9 Pounds

**INTERPRETED BY**

Eric Lindquist, DMV  
DABVP, Cert. IVUSS

**IMAGING  
PERFORMED BY**

Agnes Rupley, DVM

**HOSPITAL NAME**

All Pets Medical Center

**REFERRING VET**

Agnes Rupley, DVM

**INVOICE**

20239

**DATE**

12/23/22

**Conclusion:** If a documented fever has not responded to antibiotics, antipyretics, or general nursing care, it is important to obtain a diagnosis to guide more specific treatment. A systematic physical examination and thorough history-taking will help inform further diagnostics in addition to what is revealed by the minimum database.

**References:**

Bennet D. Diagnosis of pyrexia of unknown origin. *In Practice* 1995;17(10):470-81.

Dunn KJ, Dunn JK. Diagnostic investigations in 101 dogs with pyrexia of unknown origin. *J Sm Anim Pract* 1998;39(12):574-80.

Flood J. The diagnostic approach to fever of unknown origin in cats. *Compend Contin Educ Vet* 2009;31(1):26-31.

Flood J. The diagnostic approach to fever of unknown origin in dogs. *Compend Contin Educ Vet* 2009;31(1):14-21.

Lappin MR. The role of blood borne pathogens in feline fever of unknown origin. Proceedings from the American College of Veterinary Internal Medicine, Denver, CO, June 15-18, 2011.

Lunn KF. Fever of unknown origin: a systematic approach to diagnosis. *Compend Contin Educ Vet* 2001;23(11):976-92.

Lunn KF. Fever of unknown origin: appropriate choice of diagnostic tests. Proceedings from the American College of Veterinary Internal Medicine, Minneapolis, MN, June 9-12, 2004.