



**PATIENT PRESENTING CLINICAL SIGNS**

Chiki Rodriguez Nauseous, licking lips, weight loss Holosystolic mitral murmur 3/6 -not on any medications 1 lb weight loss over last 90 days historical allergies - improved on cytopoint

**SPECIES** Abnormal PE/Chem/CBC/UA Results: Mild elevation of ALP , BUN, CK mild proteinuria- USG normal  
Canine

**ULTRASONOGRAPHIC EXAMINATION OF THE ABDOMEN**

**BREED** *Urinary System*

Maltese The urinary bladder, trigone, and pelvic urethra presented normal thicknesses and normal tone. The ureters were not visible which is normal. No uroliths or sediment were visualized, and anechoic urine was present. No evidence of inflammatory or neoplastic changes were noted. Ureteral papillae were normal.

**SEX**

FS

**AGE**

14

The kidneys revealed normal size and structure, corticomedullary definition and ratio for this age. The cortices presented largely uniform texture with normal echogenic relationship to liver and spleen. Medullary structure differed distinctly from the cortex and no evidence of pelvic dilation was present. The capsules were acceptably uniform without significant irregularities. The left kidney measured 3.57 cm in length. The right kidney measured 3.29 cm in length.

*Adrenal Glands*

**WEIGHT**

4.8

Both adrenal glands were visualized exhibiting subnormal left adrenal size with bilateral flattening and isoechoic parenchyma. The left adrenal gland measured 0.16 cm. The right adrenal gland measured 0.49 cm.

**INTERPRETED BY**

Eric Lindquist, DMV  
DABVP, Cert. IVUSS

*Spleen*

The spleen presented a smooth homogeneous parenchyma hyperechoic to liver and renal cortical parenchyma. A focal non-disruptive hypoechoic nodule was present measuring 4 mm. The capsule was smooth without noticeable expansion or deviation from within the spleen or adjacent pathology. The splenic vasculature demonstrated normal volume without signs of congestion or thrombosis.

**IMAGING PERFORMED BY**  
Dr. Gordon

*Liver*

The liver images submitted revealed subjectively normal liver size, contour, and structure. Parenchymal echogenicity was naturally coarse and hypoechoic to the spleen. Vascular and biliary tracts were of normal volume with no evidence of congestion. The gallbladder presented acceptably thin walls with primarily anechoic content. The cystic and common bile ducts were normal. No pathological hepatic lymphadenopathy was evident. No overt structural evidence of inflammatory, infiltrative or regenerative pathology was evident.

**HOSPITAL NAME**

Coral Ridge Animal  
Hospital

**REFERRING VET**

Dr. Gordon

*Gastrointestinal*

Examination of the gastrointestinal tract revealed a thickened stomach with a hypertrophied muscularis and remodeled mucosa. No overt ulcerative changes were noted, however microulceration cannot be definitively excluded.

**INVOICE**

12529ag

*Pancreas*

**DATE**

12/23/2022



**PATIENT**

Chiki Rodriguez

The base and limbs of the pancreas were observed to be largely isoechoic to surrounding omental fat. Pancreatic duct and capsular contour were acceptably normal, and parenchyma respected normal curvilinear patterns. No overt evidence of active inflammatory or neoplastic disease was noted.

**SPECIES**

Canine

**ULTRASONOGRAPHIC FINDINGS**

- Gastric hypertrophy-suspect gastritis
- Flattened bilateral adrenal glands-possible underlying Addison's disease
- Subnormal left adrenal size

**BREED**

Maltese

**INTERPRETATION OF THE FINDINGS & FURTHER RECOMMENDATIONS**

**SEX**

A GI protectant protocol and ACTH stim warranted to assess for underlying Addison's disease as gastritis is often secondary.

**FS**

Some or all of the follow protocol or similar may be considered with assessment of clinical response. A clinical trial of **Zithromax (Dogs: 5-10 mg/kg PO q24h. May increase dosing interval to q48h after 3-5 days of treatment), Metronidazole (10-20 mg/kg PO BID), Pepcid (0.5-1 mg/kg PO SID.) and Sucralfate (0.5-2 g/dog PO) or Omeprazole (1 mg/kg PO SID.)** over the next 3 weeks along with a **novel-protein or hydrolyzed diet** with slurry feeding BID/TID. over the next 2-4 days and then increase to canned diet bid. Dry food should be avoided over the next 4 weeks. A recheck sonogram to assess GI improvement or progression would be ideal in 4 weeks.

**AGE**

14

**WEIGHT**

4.8

**INTERPRETED BY**

Eric Lindquist, DMV  
DABVP, Cert. IVUSS

**IMAGING PERFORMED BY**

Dr. Gordon

**HOSPITAL NAME**

Coral Ridge Animal Hospital

**REFERRING VET**

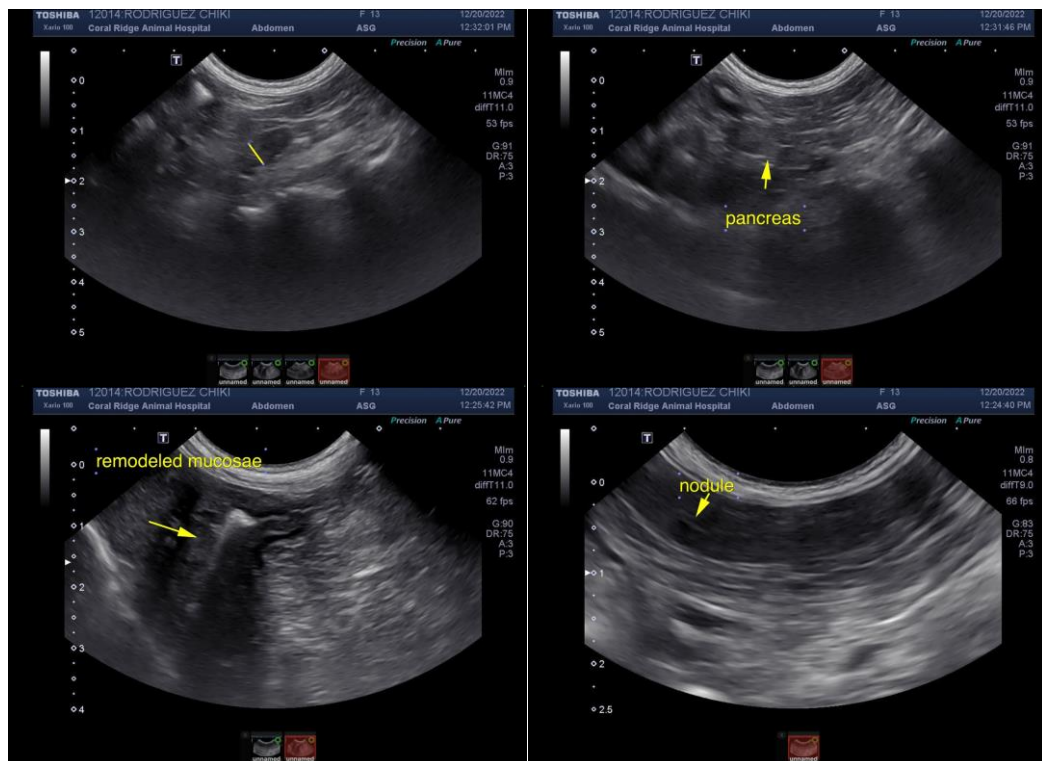
Dr. Gordon

**INVOICE**

12529ag

**DATE**

12/23/2022





**PATIENT**

Chiki Rodriguez

**SPECIES**

Canine

**BREED**

Maltese

**SEX**

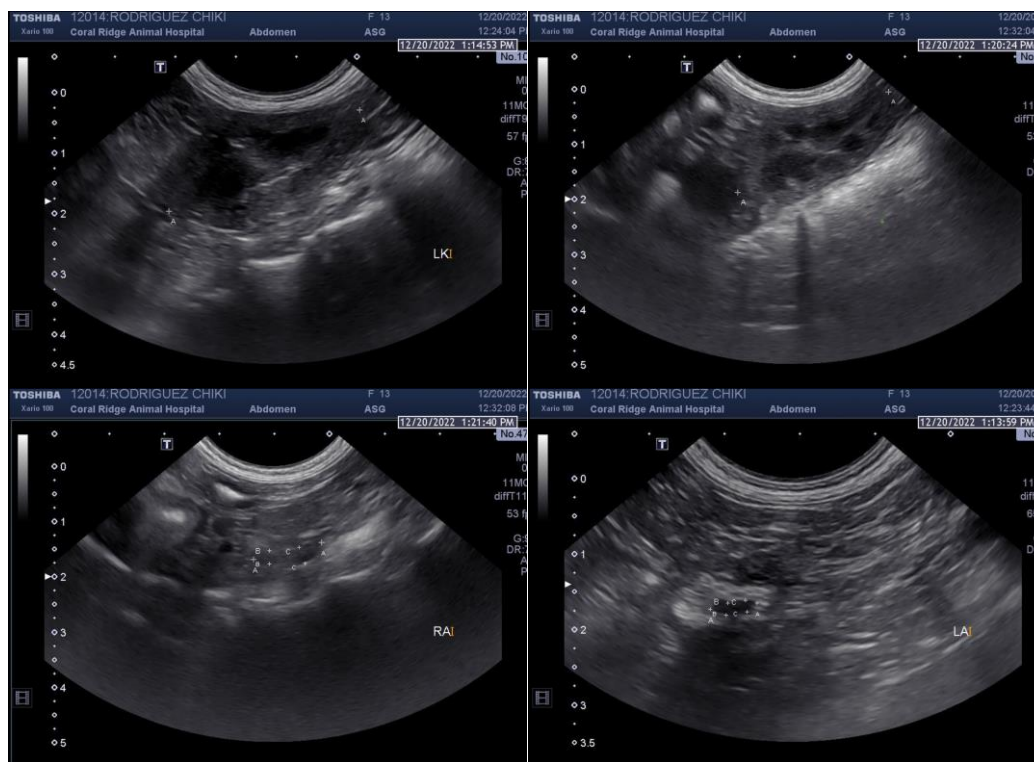
FS

**AGE**

14

**WEIGHT**

4.8



**INTERPRETED BY**

Eric Lindquist, DMV  
DABVP, Cert. IVUSS

**IMAGING PERFORMED BY**  
Dr. Gordon

**HOSPITAL NAME**

Coral Ridge Animal  
Hospital

**REFERRING VET**

Dr. Gordon

**INVOICE**

12529ag

**DATE**

12/23/2022

The information and recommendations provided are based on the images presented by the referring veterinarian. No evaluation can be communicated regarding pathology that was not visible in the image/video clips provided.

Thank you for this referral. If the clinical or image interpretation does not parallel your findings or if I can be of any further assistance please contact me.

Eric Lindquist, DMV, DABVP, Cert. IVUSS, CEO of SonoPath.com  
Eric.Lindquist@SonoPath.com