

PATIENT PRESENTING CLINICAL SIGNS

Lucy Wolf Unsure but may have tied early November. Pregnant?

SPECIES LIMITED ULTRASONOGRAPHIC EXAMINATION

Canine

The **urinary bladder**, trigone, and pelvic urethra presented normal thicknesses and normal tone. The ureters were not visible which is normal. No uroliths or sediment were visualized and anechoic urine was present. No evidence of inflammatory or neoplastic changes were noted. Ureteral papillae were normal.

BREED

Rottie X

Examination of the **gastrointestinal tract** revealed a stomach and intestine free of stasis, of normal wall thickness, acceptable curvilinear mural detail, and peristaltic activity. Small and large intestine demonstrated normal luminal chyme and stool consistency respectively. No obstructive or overt infiltrative disease was noted. No associated abnormal lymphatic activity was noted.

SEX

Intact Female

The **uterus** was empty.

ULTRASONOGRAPHIC FINDINGS

AGE

2 Years

- Empty uterus

INTERPRETATION OF THE FINDINGS & FURTHER RECOMMENDATIONS

No evidence of positive pregnancy.

WEIGHT

49.8 kg

INTERPRETED BY

Eric Lindquist, DMV
DABVP, Cert. IVUSS

IMAGING PERFORMED BY

Crystal Hill

HOSPITAL NAME

Simcoe AH

REFERRING VET

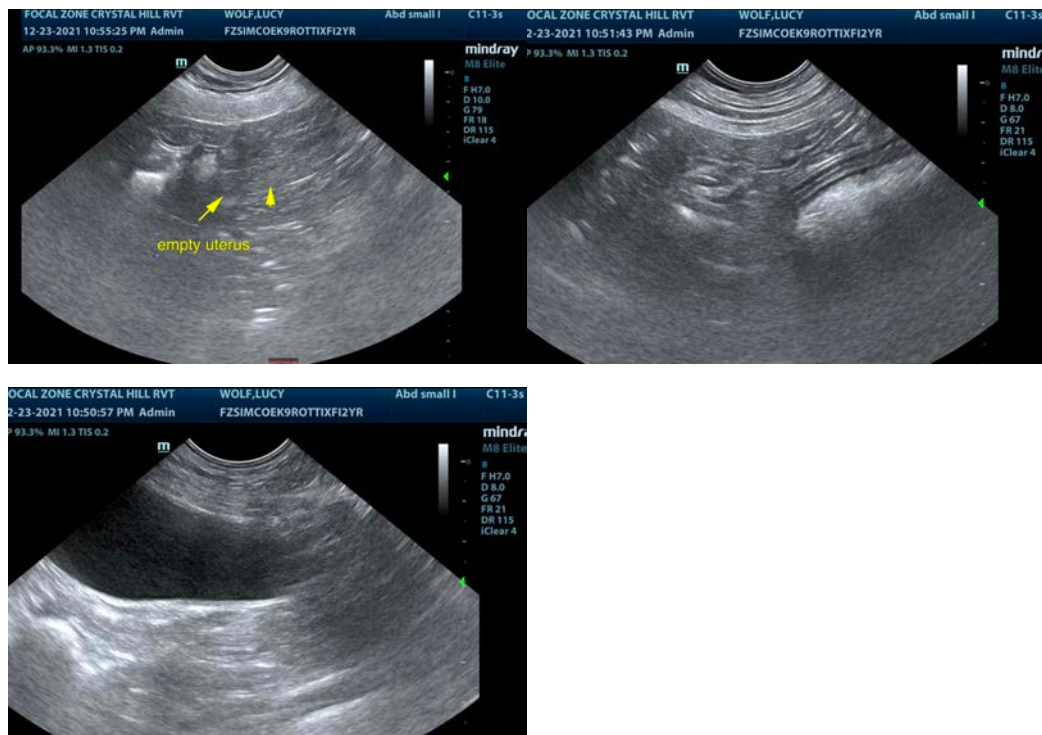
Dr. Kennedy

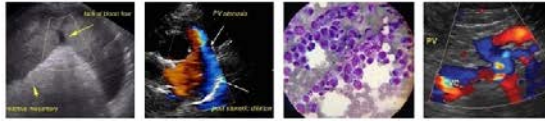
INVOICE

33699

DATE

12/23/21





PATIENT

Lucy Wolf

The information and recommendations provided are based on the images presented by the referring veterinarian. No evaluation can be communicated regarding pathology that was not visible in the image/video clips provided.

SPECIES

Canine

Thank you for this referral. If the clinical or image interpretation does not parallel your findings or if I can be of any further assistance please contact me.

BREED

Rottie X

Eric Lindquist, DMV, DABVP, Cert. IVUSS, CEO of SonoPath.com
Eric.Lindquist@SonoPath.com

SEX

Intact Female

AGE

2 Years

WEIGHT

49.8 kg

INTERPRETED BY

Eric Lindquist, DMV
DABVP, Cert. IVUSS

**IMAGING
PERFORMED BY**

Crystal Hill

HOSPITAL NAME

Simcoe AH

REFERRING VET

Dr. Kennedy

INVOICE

33699

DATE

12/23/21