



PATIENT

Eleanor Flute

PRESENTING CLINICAL SIGNS

inappetent for 5 days, vomiting
Abnormal PE/Chem/CBC/UA Results: WNC 23,000, CPL neg

SPECIES

Canine

ULTRASONOGRAPHIC EXAMINATION OF THE ABDOMEN

Urinary System

BREED

Bloodhound

The **urinary bladder**, trigone, and pelvic urethra presented normal thicknesses and normal tone. The ureters were not visible which is normal. No uroliths or sediment were visualized and anechoic urine was present. No evidence of inflammatory or neoplastic changes were noted. Ureteral papillae were normal. The pelvic urethra was imaged 2.0 cm beyond the cystourethral junction.

SEX

Intact Female

The **kidneys** revealed normal size and structure, corticomedullary definition and ratio for this age. The cortices presented largely uniform texture with normal echogenic relationship to liver and spleen. Medullary structure differed distinctly from the cortex and no evidence of pelvic dilation was present. The capsules were acceptably uniform without significant irregularities. The right kidney measured 6.78 cm. The left kidney measured 6.2 cm.

AGE

10 Months

Adrenal Glands

WEIGHT

73 Pounds

Both **adrenal glands** were visualized and recognized as having normal shape, size, position and echogenicity for this breed. The phrenic vasculature, glandular echogenicity and detail were unremarkable. Capsule, cortex, and medullary definition were normal for this age patient. The left adrenal gland measured 2.4 cm x 0.32 cm at the caudal pole and 0.34 cm at the cranial pole. The right adrenal gland measured 2.05 cm x 1.24 cm at the cranial pole and 0.37 cm at the caudal pole.

INTERPRETED BY

Eric Lindquist, DMV
DABVP, Cert. IVUSS

Spleen

The **spleen** presented a smooth homogeneous parenchyma hyperechoic to liver and renal cortical parenchyma. The capsule was smooth without noticeable expansion or deviation from within the spleen or adjacent pathology. The splenic vasculature demonstrated normal volume without signs of congestion or thrombosis. No sonographic evidence of acute or chronic inflammatory, neoplastic, or infarctual changes were noted.

IMAGING PERFORMED BY

Diane McFadden

Liver

HOSPITAL NAME

North Warren AH

The **liver** images submitted revealed subjectively normal liver size, contour, and structure. Parenchymal echogenicity was naturally coarse and hypoechoic to the spleen. Vascular and biliary tracts were of normal volume with no evidence of congestion. The gallbladder presented acceptably thin walls with primarily anechoic content. The cystic and common bile ducts were normal. No pathological hepatic lymphadenopathy was evident. No overt structural evidence of inflammatory, infiltrative or regenerative pathology was evident.

REFERRING VET

Dr. Corrado

Gastrointestinal

INVOICE

33684

The **stomach** itself was unremarkable. The mid small intestine revealed tortuous contour with a subtle linear foreign body and obstructive pattern attached to soft foreign matter. Recommend immediate exploratory surgery.

Pancreas

DATE

12/23/21

The base and limbs of the **pancreas** were observed to be largely isoechoic to surrounding omental fat. Pancreatic duct and capsular contour were acceptably normal and parenchyma respected normal curvilinear patterns. No overt evidence of active inflammatory or neoplastic disease was noted.



PATIENT

Eleanor Flute

ULTRASONOGRAPHIC FINDINGS

- Small intestinal linear foreign body with full obstruction

SPECIES

Canine

INTERPRETATION OF THE FINDINGS & FURTHER RECOMMENDATIONS

Surgical intervention recommended.

BREED

Bloodhound

SEX

Intact Female

AGE

10 Months

WEIGHT

73 Pounds

INTERPRETED BY

Eric Lindquist, DMV
DABVP, Cert. IVUSS

IMAGING PERFORMED BY

Diane McFadden

HOSPITAL NAME

North Warren AH

REFERRING VET

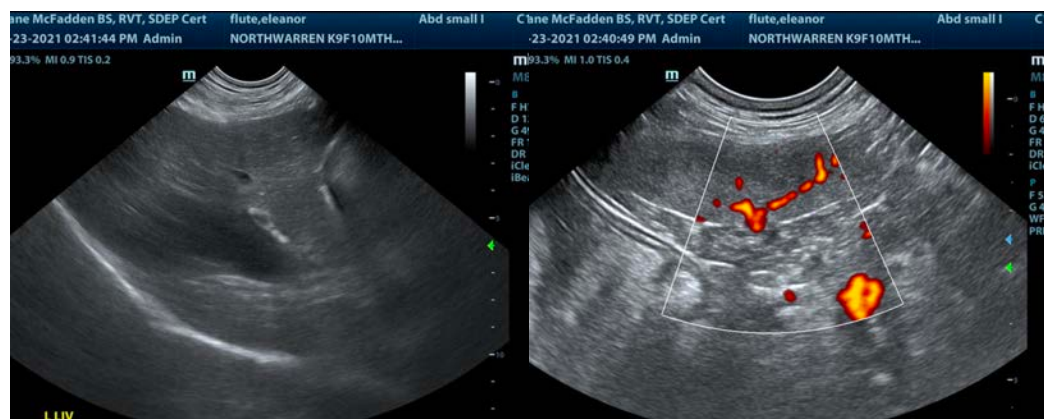
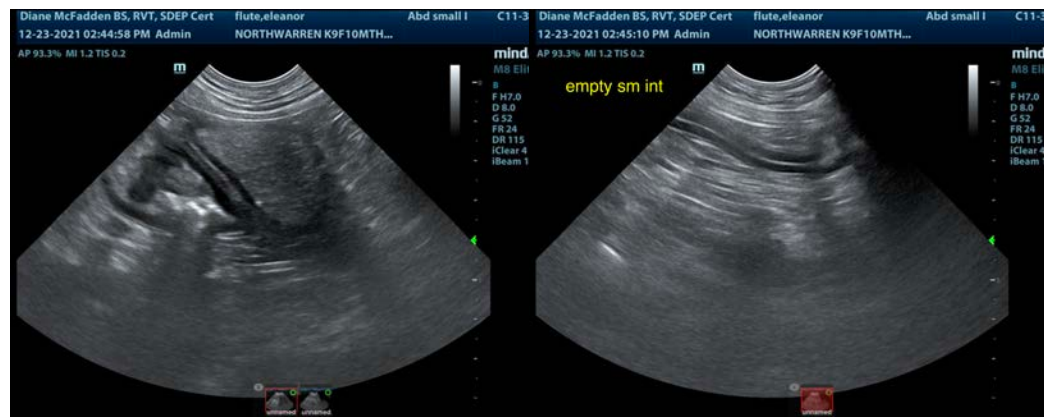
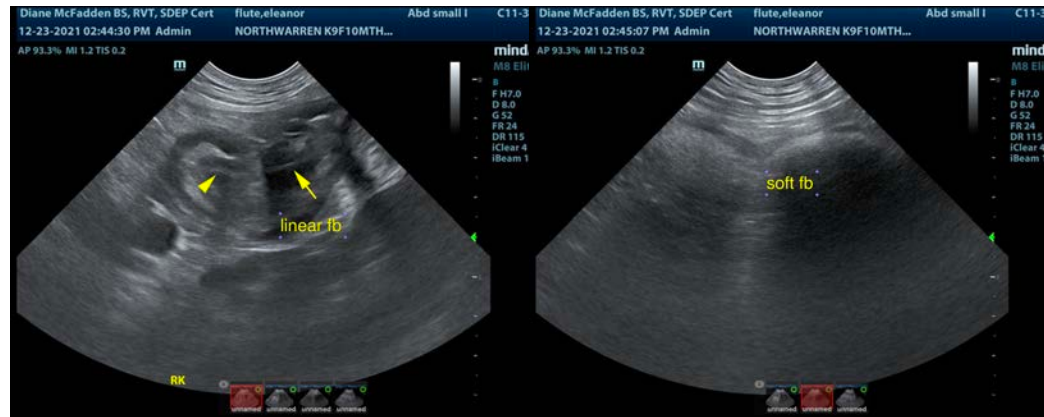
Dr. Corrado

INVOICE

33684

DATE

12/23/21





PATIENT

Eleanor Flute

SPECIES

Canine

BREED

Bloodhound

SEX

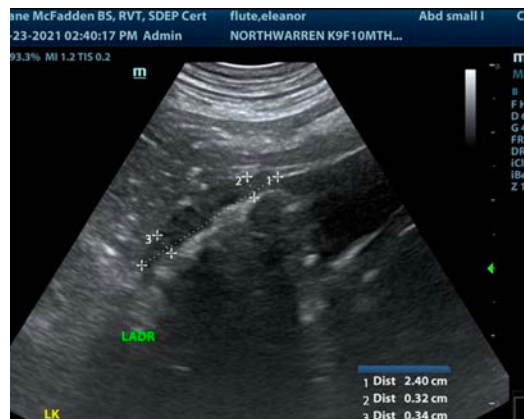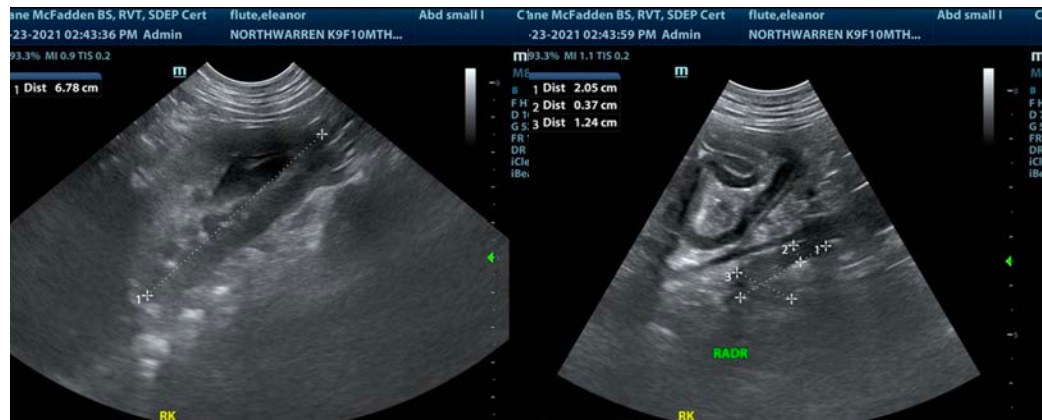
Intact Female

AGE

10 Months

WEIGHT

73 Pounds



INTERPRETED BY

Eric Lindquist, DMV
DABVP, Cert. IVUSS

IMAGING PERFORMED BY

Diane McFadden

HOSPITAL NAME

North Warren AH

REFERRING VET

Dr. Corrado

INVOICE

33684

DATE

12/23/21

The information and recommendations provided are based on the images presented by the referring veterinarian. No evaluation can be communicated regarding pathology that was not visible in the image/video clips provided.

Thank you for this referral. If the clinical or image interpretation does not parallel your findings or if I can be of any further assistance please contact me.

Eric Lindquist, DMV, DABVP, Cert. IVUSS, CEO of SonoPath.com
info@SonoPath.com