



PATIENT PRESENTING CLINICAL SIGNS

Barkley Zarama gastroenteritis , vomiting

SPECIES ULTRASONOGRAPHIC EXAMINATION OF THE ABDOMEN

Canine Urinary System

The **urinary bladder**, trigone, and pelvic urethra presented normal thicknesses and normal tone. The ureters were not visible which is normal. No uroliths or sediment were visualized and anechoic urine was present. No evidence of inflammatory or neoplastic changes were noted. Ureteral papillae were normal.

BREED

Lab X

SEX

Neutered Male

The **kidneys** revealed normal size and structure, corticomedullary definition and ratio for this age. The cortices presented largely uniform texture with normal echogenic relationship to liver and spleen. Medullary structure differed distinctly from the cortex and no evidence of pelvic dilation was present. The capsules were acceptably uniform without significant irregularities. The left kidney measured 6.0 cm.

AGE

1 Year

Adrenal Glands

Both **adrenal glands** were visualized and recognized as having normal shape, size, position and echogenicity for this breed. The phrenic vasculature, glandular echogenicity and detail were unremarkable. Capsule, cortex, and medullary definition were normal for this age patient. The left adrenal gland measured 0.4 cm.

WEIGHT

27 Pounds

Spleen

The **spleen** presented a smooth homogeneous parenchyma hyperechoic to liver and renal cortical parenchyma. The capsule was smooth without noticeable expansion or deviation from within the spleen or adjacent pathology. The splenic vasculature demonstrated normal volume without signs of congestion or thrombosis. No sonographic evidence of acute or chronic inflammatory, neoplastic, or infarctual changes were noted.

INTERPRETED BY

Eric Lindquist, DMV
DABVP, Cert. IVUSS

IMAGING PERFORMED BY

Jenn

Liver

The **liver** images submitted revealed subjectively normal liver size, contour, and structure. Parenchymal echogenicity was naturally coarse and hypoechoic to the spleen. Vascular and biliary tracts were of normal volume with no evidence of congestion. The gallbladder presented acceptably thin walls with primarily anechoic content. The cystic and common bile ducts were normal. No pathological hepatic lymphadenopathy was evident. No overt structural evidence of inflammatory, infiltrative or regenerative pathology was evident.

HOSPITAL NAME

Rockaway AH

Gastrointestinal

REFERRING VET

Dr. Maniar

The upper **gastrointestinal tract** in this patient revealed minor, edematous wall. Retained ingesta noted in the stomach. There was no evidence of foreign bodies. Minor areas of fluctuant fluid accumulation were noted within the lumen with hyperperistalsis. This pattern continued to the ileocecal valve. The colon revealed a fluid filled lumen. This presentation is most consistent with gastrointestinal irritation/inflammation without obstruction.

INVOICE

33693

Pancreas

DATE

12/23/21

The base and limbs of the **pancreas** were observed to be largely isoechoic to surrounding omental fat. Pancreatic duct and capsular contour were acceptably normal and parenchyma respected normal curvilinear patterns. No overt evidence of active inflammatory or neoplastic disease was noted.



PATIENT

Barkley Zarama

ULTRASONOGRAPHIC FINDINGS

- Gastroenteritis with retained ingesta in stomach

SPECIES

Canine

INTERPRETATION OF THE FINDINGS & FURTHER RECOMMENDATIONS

No obvious foreign matter. However, depending on when the patient ate, soft foreign matter could be present in the stomach, yet transit of chyme appeared to be present. Recheck sonogram at full NPO status if the patient was not NPO. Otherwise, this would be consistent with a post-prandial presentation.

BREED

Lab X

SEX

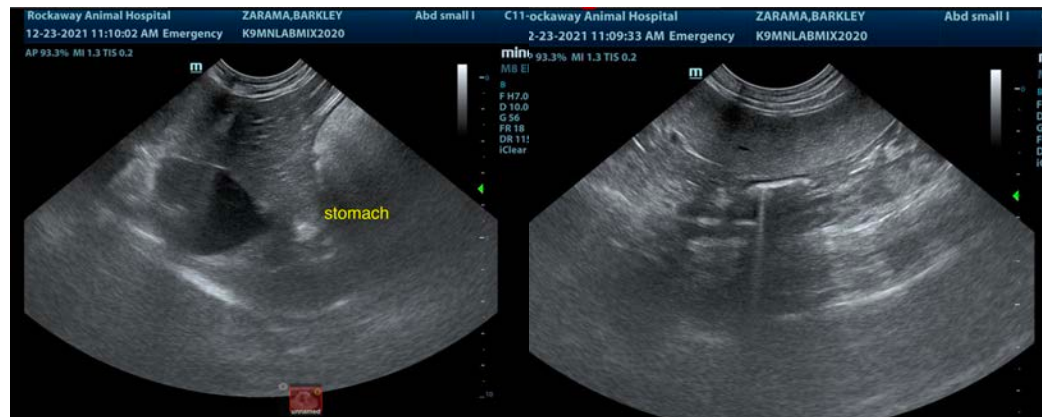
Neutered Male

AGE

1 Year

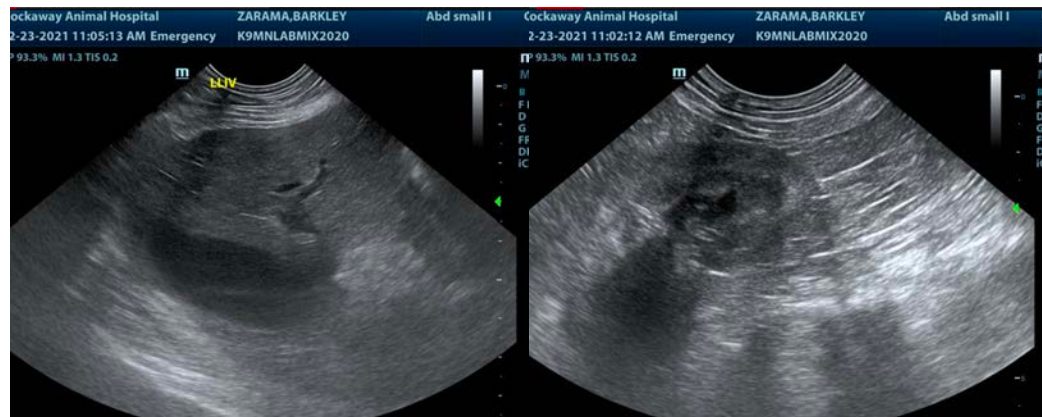
WEIGHT

27 Pounds



INTERPRETED BY

Eric Lindquist, DMV
DABVP, Cert. IVUSS



IMAGING PERFORMED BY

Jenn

HOSPITAL NAME

Rockaway AH

The information and recommendations provided are based on the images presented by the referring veterinarian. No evaluation can be communicated regarding pathology that was not visible in the image/video clips provided.

REFERRING VET

Dr. Maniar

Thank you for this referral. If the clinical or image interpretation does not parallel your findings or if I can be of any further assistance please contact me.

INVOICE

33693

Eric Lindquist, DMV, DABVP, Cert. IVUSS, CEO of SonoPath.com
info@SonoPath.com

DATE

12/23/21