



PATIENT

Benji Ocampo

SPECIES

Canine

BREED

Golden Retriever Mix

SEX

Neutered Male

AGE

4 Years

WEIGHT

16 Pounds

INTERPRETED BY

Eric Lindquist, DMV,
DABVP(CFM), Cert.
IVUSS

IMAGING PERFORMED BY

Shari Reffi, CVT

HOSPITAL NAME

Rockaway AH

REFERRING VET

Dr. Maniar

INVOICE

35018

DATE

12/22/25

PRESENTING CLINICAL SIGNS

History: Significant V/D.
Abnormal PE/Chem/CBC/UA Results: NSF

ULTRASONOGRAPHIC EXAMINATION OF THE ABDOMEN

Urinary System

The **urinary bladder**, trigone, and pelvic urethra presented normal thicknesses and normal tone. The ureters were not visible which is normal. No uroliths or sediment were visualized and anechoic urine was present. No evidence of inflammatory or neoplastic changes was noted. Ureteral papillae were normal. The residual prostate measured 0.92 cm.

The **kidneys** revealed normal size and structure, corticomedullary definition and ratio for this age. The cortices presented largely uniform texture with normal echogenic relationship to liver and spleen. Medullary structure differed distinctly from the cortex, and no evidence of pelvic dilation was present. The capsules were acceptably uniform without significant irregularities. The right kidney measured 4.43 cm. The left kidney measured 4.23 cm.

Adrenal Glands

Both **adrenal glands** were visualized and recognized as having normal shape, size, position and echogenicity for this breed. The phrenic vasculature, glandular echogenicity and detail were unremarkable. Capsule, cortex, and medullary definition were normal for this age patient. The right adrenal gland measured 0.43 cm at the caudal pole and 0.41 cm at the cranial pole. The left adrenal gland measured 0.54 cm at the caudal pole and 0.43 cm at the cranial pole.

Spleen

The **spleen** presented a smooth homogeneous parenchyma hyperechoic to liver and renal cortical parenchyma. The capsule was smooth without noticeable expansion or deviation from within the spleen or adjacent pathology. The splenic vasculature demonstrated normal volume without signs of congestion or thrombosis. No sonographic evidence of acute or chronic inflammatory, neoplastic, or infarctual changes were noted.

Liver

The **liver** images submitted revealed subjectively normal liver size, contour, and structure. Parenchymal echogenicity was naturally coarse and hypoechoic to the spleen. Vascular and biliary tracts were of normal volume with no evidence of congestion. The gallbladder presented acceptably thin walls with primarily anechoic content. The cystic and common bile ducts were normal. No pathological hepatic lymphadenopathy was evident. No overt structural evidence of inflammatory, infiltrative or regenerative pathology was evident.

Gastrointestinal

Examination of the **gastrointestinal tract** revealed a stomach and intestine free of stasis, of normal wall thickness, acceptable curvilinear mural detail, and peristaltic activity. Small and large intestine



PATIENT

demonstrated normal luminal chyme and stool consistency respectively. No obstructive or overt infiltrative disease was noted. No associated abnormal lymphatic activity was noted.

Benji Ocampo

Pancreas

SPECIES

The base and limbs of the **pancreas** were observed to be largely isoechoic to surrounding omental fat. Pancreatic duct and capsular contour were acceptably normal and parenchyma respected normal curvilinear patterns. No overt evidence of active inflammatory or neoplastic disease was noted.

Canine

BREED

ULTRASONOGRAPHIC FINDINGS

Golden Retriever Mix

- Structurally unremarkable abdomen

SEX

INTERPRETATION OF THE FINDINGS & FURTHER RECOMMENDATIONS

Neutered Male

No evidence of pathology. Dietary indiscretion, food intolerance, structurally insignificant inflammatory bowel or occult parasitism and occult Addison's are all potentials.

AGE

4 Years

WEIGHT

16 Pounds

INTERPRETED BY

Eric Lindquist, DMV,
DABVP(CFM), Cert.
IVUSS

IMAGING PERFORMED BY

Shari Reffi, CVT

HOSPITAL NAME

Rockaway AH

REFERRING VET

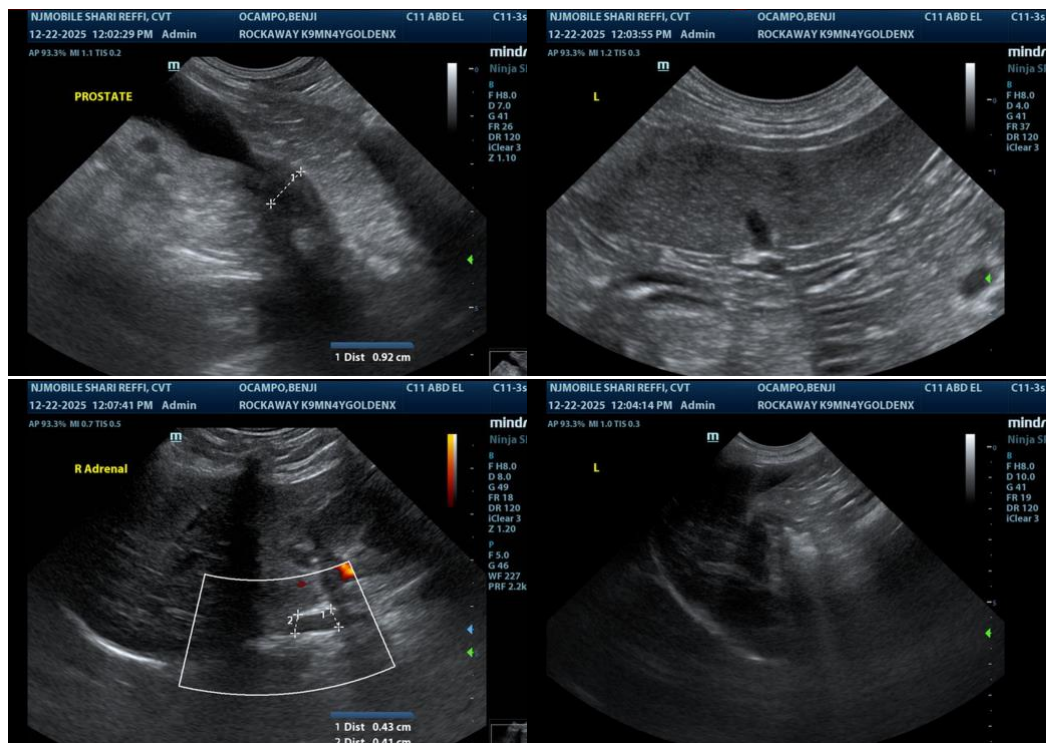
Dr. Maniar

INVOICE

35018

DATE

12/22/25





PATIENT

Benji Ocampo

SPECIES

Canine

BREED

Golden Retriever Mix

SEX

Neutered Male

AGE

4 Years

WEIGHT

16 Pounds

INTERPRETED BY

Eric Lindquist, DMV,
DABVP(CFM), Cert.
IVUSS

IMAGING PERFORMED BY

Shari Reffi, CVT

HOSPITAL NAME

Rockaway AH

REFERRING VET

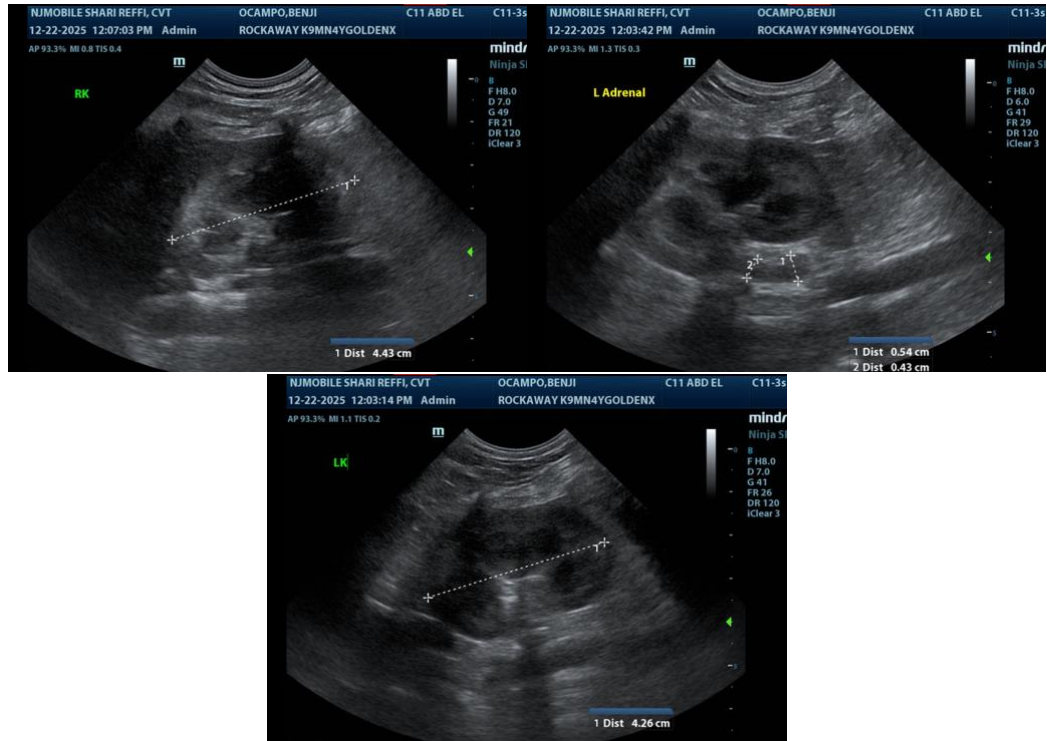
Dr. Maniar

INVOICE

35018

DATE

12/22/25



The information and recommendations provided are based on the images presented by the referring veterinarian/sonographer. No evaluation can be communicated regarding pathology that was not visible in the image/video clips provided.

Thank you for this referral. If the clinical or image interpretation does not parallel your findings or if I can be of any further assistance please contact me.

Eric Lindquist, DMV, DABVP(CFM), Cert. IVUSS,
CEO, Owner, Founder -- SonoPath.com
info@SonoPath.com