



PATIENT

Bernie Berger

PRESENTING CLINICAL SIGNS

re check previous u/s on 12/20 showed full stomach dog has been NPO for 24 hours except for a couple of pills given this am.

SPECIES

Canine

LIMITED ULTRASONOGRAPHIC EXAMINATION

The stomach was overdistended with fluid and chyme. The distal small intestine was empty, as was the colon. Significant gastric stasis noted and delayed outflow pattern. The proximal duodenum revealed thickening and some soft shadowing material, may be in ingesta.

BREED

Boston Terrier

INTERPRETATION OF THE FINDINGS & FURTHER RECOMMENDATIONS

I'm concerned for a stricturing tissue pattern in the upper duodenum, which may be neoplastic or chronic inflammatory. Exploratory surgery indicated, or endoscopy with post-pyloric inspection and sampling.

SEX

Spayed Female

AGE

7 Years

WEIGHT

19.5 Pounds

INTERPRETED BY

Eric Lindquist, DMV

DABVP, Cert. IVUSS

IMAGING PERFORMED BY

Jenn

HOSPITAL NAME

Rockaway AH

REFERRING VET

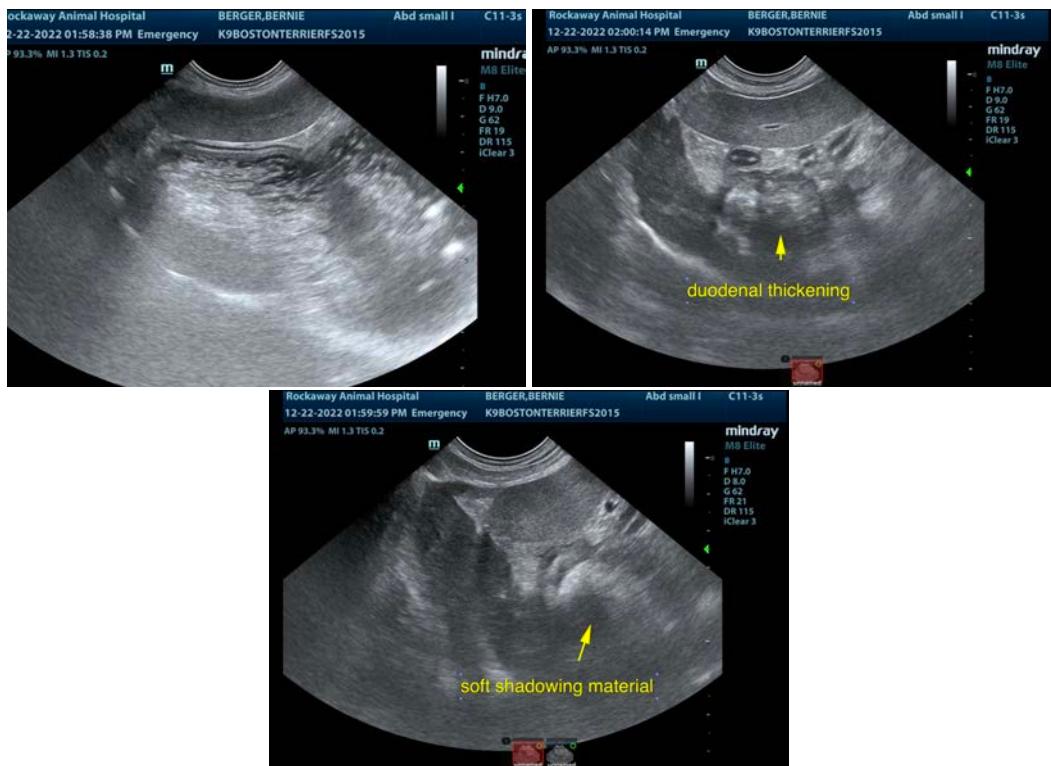
Dr. Maniar

INVOICE

43646

DATE

12/22/22



The information and recommendations provided are based on the images presented by the referring veterinarian/sonographer. No evaluation can be communicated regarding pathology that was not visible in the image/video clips provided.

Thank you for this referral. If the clinical or image interpretation does not parallel your findings or if I can be of any further assistance please contact me.

Eric Lindquist, DMV, DABVP, Cert. IVUSS, CEO of SonoPath.com

info@SonoPath.com