

PATIENT

Bernie Berger

SPECIES

Canine

BREED

Boston Terrier

SEX

FS

AGE

7

WEIGHT

19.5

INTERPRETED BY

Eric Lindquist, DMV
DABVP, Cert. IVUSS

IMAGING PERFORMED BY

Jenn

HOSPITAL NAME

Rockaway Animal
Hospital

REFERRING VET

Dr. Maniar

INVOICE

12523ag

DATE

12/22/2022

PRESENTING CLINICAL SIGNS

re check , yesterdays u/s showed overdistended stomach with fluid and chyme and significant gastric stasis, duodenum had some soft shadowing material maybe ingesta

LIMITED ULTRASONOGRAPHIC RECHECK EXAMINATION OF THE GI TRACT

Gastrointestinal

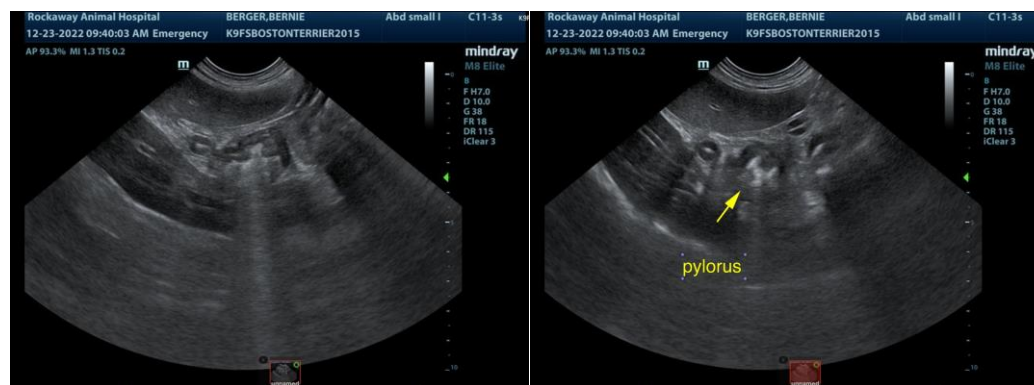
Examination of the gastrointestinal tract revealed a stomach and intestine free of stasis, of normal wall thickness, acceptable curvilinear mural detail, and peristaltic activity. Small and large intestine demonstrated normal luminal chyme and stool consistency respectively. No obstructive or overt infiltrative disease was noted. No associated abnormal lymphatic activity was noted.

ULTRASONOGRAPHIC FINDINGS

- Normal gastrointestinal tract

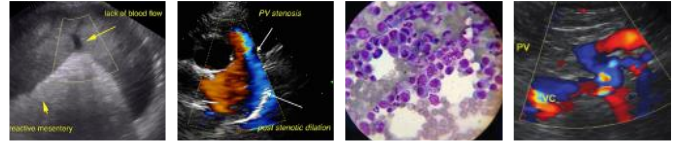
INTERPRETATION OF THE FINDINGS & FURTHER RECOMMENDATIONS

The gastric stasis noted on the prior sonogram is no longer present. The patient has been medically managed into normalcy. The patient should respond to supportive care.



The information and recommendations provided are based on the images presented by the referring veterinarian. No evaluation can be communicated regarding pathology that was not visible in the image/video clips provided.

Thank you for this referral. If the clinical or image interpretation does not parallel your findings or if I can be of any further assistance please contact me.



PATIENT

Eric Lindquist, DMV, DABVP, Cert. IVUSS, CEO of SonoPath.com
Eric.Lindquist@SonoPath.com

Bernie Berger

SPECIES

Canine

BREED

Boston Terrier

SEX

FS

AGE

7

WEIGHT

19.5

INTERPRETED BY

Eric Lindquist, DMV
DABVP, Cert. IVUSS

**IMAGING
PERFORMED BY**

Jenn

HOSPITAL NAME

Rockaway Animal
Hospital

REFERRING VET

Dr. Maniar

INVOICE

12523ag

DATE

12/22/2022