
PATIENT PRESENTING CLINICAL SIGNS

Zara Taylor Bruin

SPECIES

Canine

BREED

Pit Bull

Started what O thought was the first heat cycle 2-3 weeks ago. Only produced a few drops of blood at the time. Started bleeding again and is now bleeding a lot more. I off-colored and smells different than other normal female heat cycles. O states that she was told P has an actively bleeding mass in the uterus and to spay her. O does not want to spay her if she does not have to and wants a second opinion. Also has II-III/VI heart murmur -added on after abdomen study Amoxi/clav 250BID, Yunnan Baiyo TID, (Also Tranexamic acid 650TID but hasn't started yet due to not picking up at pharmacy)

Abnormal PE/Chem/CBC/UA Results: WBC - 21,000 with a neutrophilia; chem WNL

ULTRASONOGRAPHIC EXAMINATION OF THE HEART
SEX

Intact Female

AGE

9 Months

WEIGHT

43.8 Lbs

INTERPRETED BY

Eric Lindquist, DMV

DABVP, Cert. IVUSS

CANINE CARDIAC PARAMETERS	MR VMAX (m/s)	TR VMAX (m/s)	LA/AO (Boon method)	LA/AO (Heart Base; Swe)	FS (%)	EF (%)	EPSS (cm)
NORMAL PARAMETER	4.5-5.5	<2.7	1.3	<1.6	28-40	40-100	<0.6
PATIENT	2.0	1.4	1.1		35		0.1
CANINE CARDIAC PARAMETERS	HR (BPM)	AV VMAX (m/s)	PV MAX (m/s)	BODY WEIGHT (kg)	LA 2D short axis Base view (cm)	LVIDd Avg; 2D and m-mode short axis (cm)	LVIDs Avg; 2D and m-mode short axis (cm)
NORMAL PARAMETER	50-100	0.7-1.7	0.7-1.6				
PATIENT		4.0	1.3		3.4	3.4	

Cardiac Presentation

The echocardiogram in this patient demonstrated normal **left atrial** size based on 3 separate methods of LA evaluation. Trivial **mitral** insufficiency noted. The **left ventricle** presented thicknesses with linear contour and was not dilated nor restricted. The **myocardium** presented normal echogenicity without subjective evidence of significant fibrotic or ischemic disease. **Contractility** of the ventricular walls was adequate and in normal range for this patient evidenced by the fractional shortening measurement and subjective evaluation of the different regions of the myocardium. The **aortic** valve was thickened in this patient. The **right atrial** size was slightly excessive, 1:1 ratio with the left atrium. Minor **tricuspid** insufficiency noted at 1.4 m/sec. The tricuspid valve appeared to be elongated in the free wall leaflet, and shortened septal leaflet with vegetative changes. The **right ventricle** was of normal size (1/3 diameter of LV), chordae structure, myocardial echogenicity and thickness. **Pulmonary outflow** tract assessment revealed normal valve structure, laminar flow, and diameter (approx. 1:1 pa/ao ratio). No visible **pericardial** or free pleura fluid was noted. The cranial **mediastinum** and **pericardial** and **extra-cardiac** regions were free of masses in the visible window.

ULTRASONOGRAPHIC FINDINGS

- Subaortic stenosis (moderate) with tricuspid dysplasia and concurrent mitral insufficiency – all compensated at this time.

INVOICE

33650

DATE

12/22/21

IMAGING PERFORMED BY

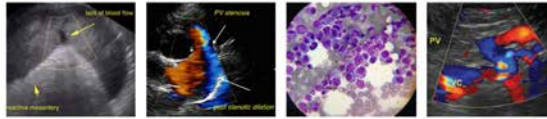
 Andrea Nicastro, DVM,
 Diplomate ACVIM
 (Small Animal Internal
 Medicine)

HOSPITAL NAME

Southside AH

REFERRING VET

Dr. Jamie Carroll



PATIENT **INTERPRETATION OF THE FINDINGS & FURTHER RECOMMENDATIONS**

Zara Taylor Bruin

If anesthesia is to be performed in this patient, then prophylactic antibiotics prior to surgery and 7 days post surgery recommended. Torbutrol premed, Propofol induction, Isoflurane maintenance. Recheck echo in 6 months, earlier if murmur grade increases or clinical signs initiate.

SPECIES

Canine

BREED

Pit Bull

SEX

Intact Female

AGE

9 Months

WEIGHT

43.8 Lbs

INTERPRETED BY

Eric Lindquist, DMV

DABVP, Cert. IVUSS

IMAGING PERFORMED BY

Andrea Nicastro, DVM,
Diplomate ACVIM
(Small Animal Internal
Medicine)

HOSPITAL NAME

Southside AH

REFERRING VET

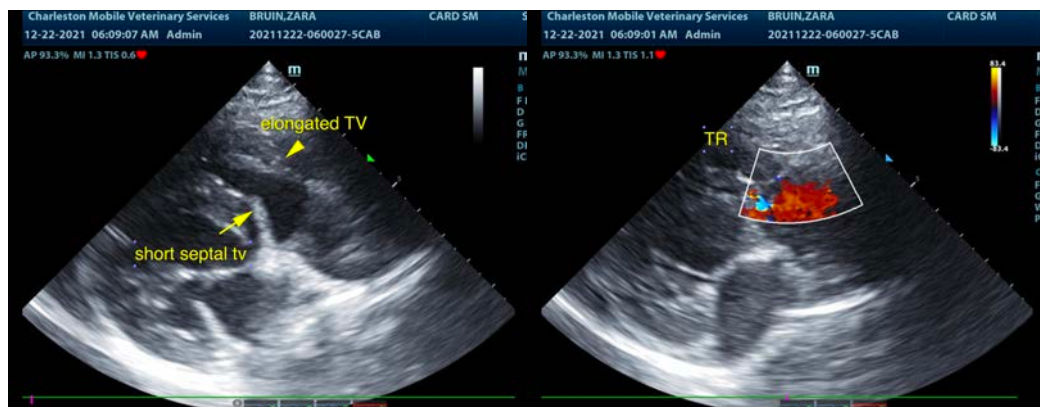
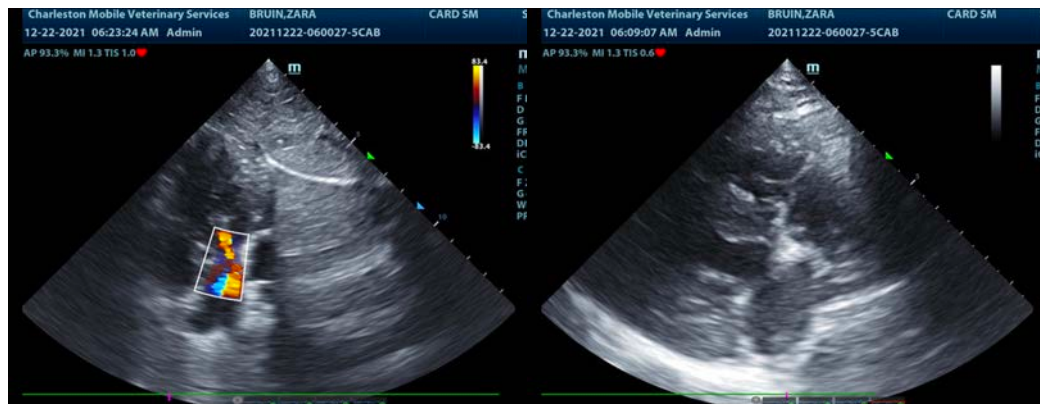
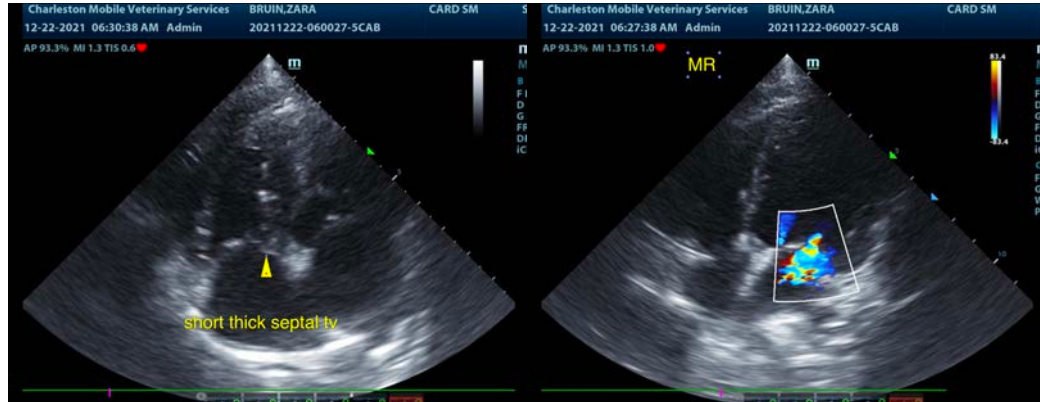
Dr. Jamie Carroll

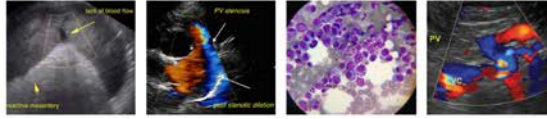
INVOICE

33650

DATE

12/22/21





PATIENT

Zara Taylor Bruin

SPECIES

Canine

BREED

Pit Bull

SEX

Intact Female

AGE

9 Months

WEIGHT

43.8 Lbs

INTERPRETED BY

Eric Lindquist, DMV

DABVP, Cert. IVUSS

IMAGING PERFORMED BY

Andrea Nicastro, DVM,
Diplomate ACVIM
(Small Animal Internal
Medicine)

HOSPITAL NAME

Southside AH

REFERRING VET

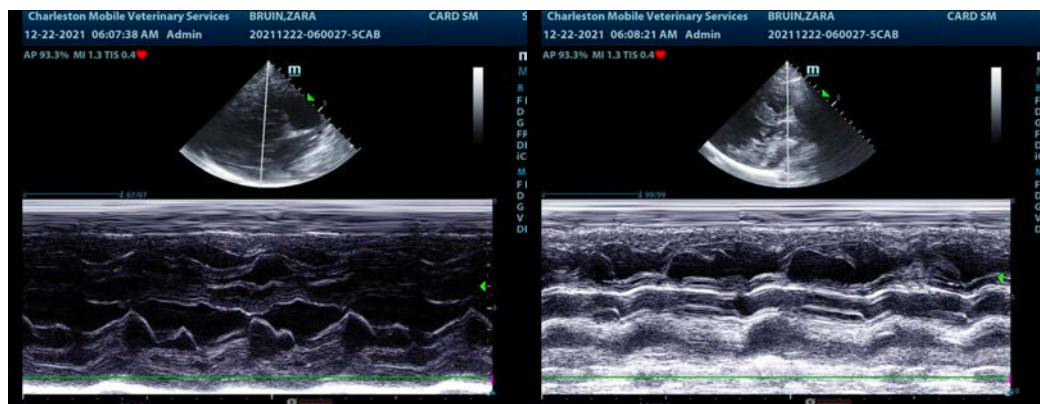
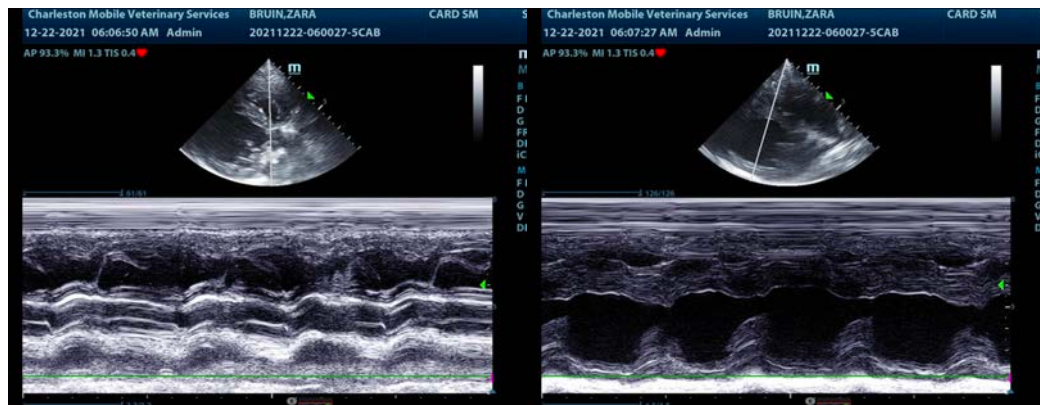
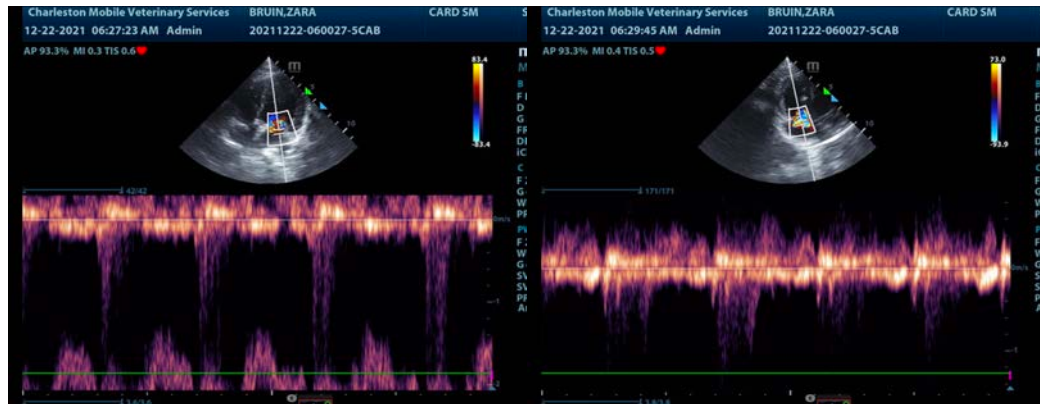
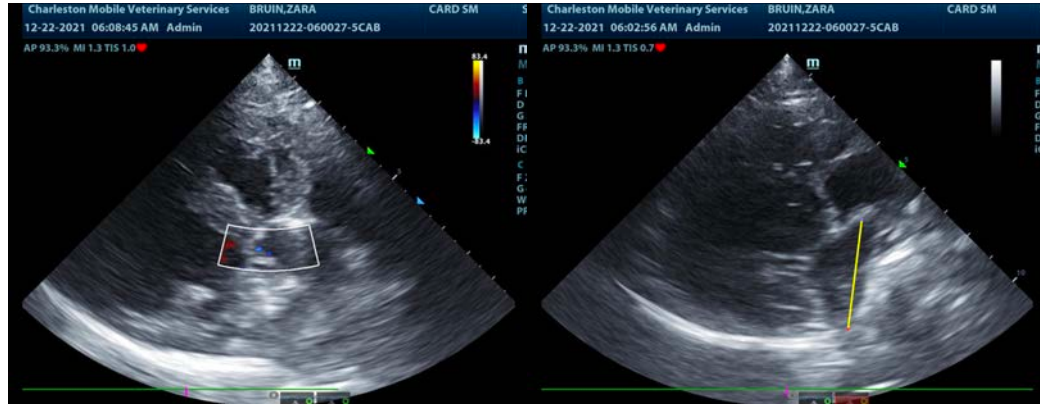
Dr. Jamie Carroll

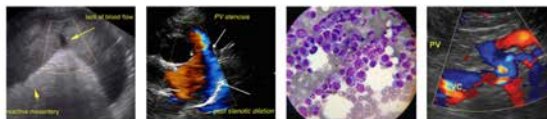
INVOICE

33650

DATE

12/22/21





PATIENT

Zara Taylor Bruin

SPECIES

Canine

BREED

Pit Bull

SEX

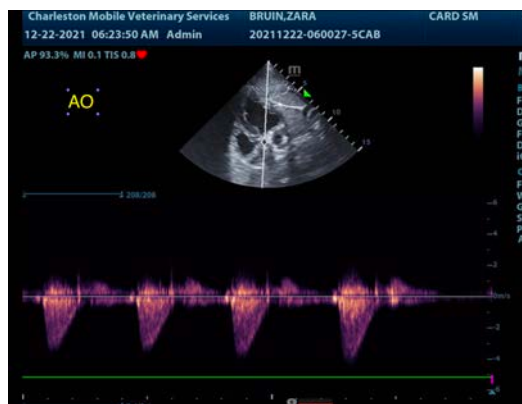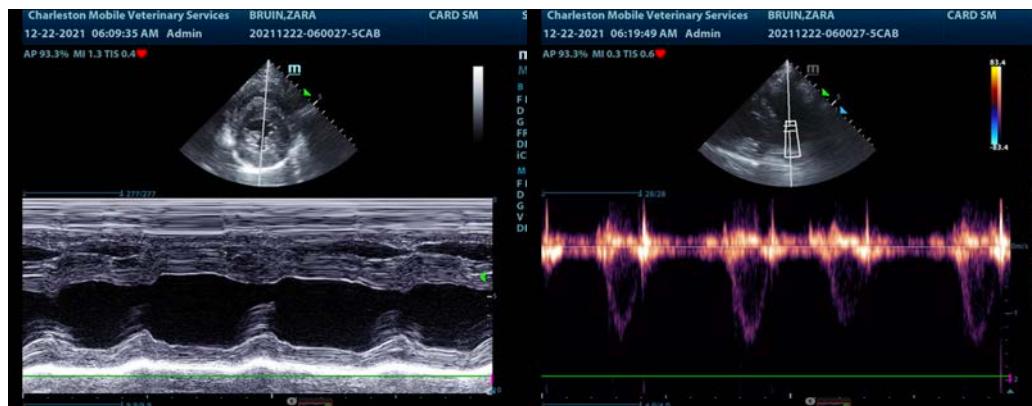
Intact Female

AGE

9 Months

WEIGHT

43.8 Lbs



INTERPRETED BY

Eric Lindquist, DMV

DABVP, Cert. IVUSS

The information and recommendations provided are based on the images presented by the referring veterinarian. No evaluation can be communicated regarding pathology that was not visible in the image/video clips provided.

Thank you for this referral. If the clinical or image interpretation does not parallel your findings or if I can be of any further assistance please contact me.

IMAGING PERFORMED BY

Andrea Nicastro, DVM,
Diplomate ACVIM
(Small Animal Internal
Medicine)

Eric Lindquist, DMV, DABVP, Cert. IVUSS, CEO of SonoPath.com

info@SonoPath.com

HOSPITAL NAME

Southside AH

REFERRING VET

Dr. Jamie Carroll

INVOICE

33650

DATE

12/22/21