



**PATIENT**

Minnie Brophy

**SPECIES**

Canine

**BREED**

Boxer

**SEX**

Spayed Female

**AGE**

6 years

**WEIGHT**

46 lbs

**INTERPRETED BY**

Eric Lindquist, DMV  
DABVP, Cert. IVUSS

**IMAGING  
PERFORMED BY**

Shari Reffi, CVT

**HOSPITAL NAME**

Long Valley AH

**REFERRING VET**

Dr. Earl

**INVOICE**

94832

**DATE**

12/22/21

**PRESENTING CLINICAL SIGNS**

Gagging /vomiting and weight loss. Vomiting mostly at night (holds down breakfast), V daily x 10 days. Hx of MCT. Current meds: Famotidine 20mg sid, ID diet, Cerenia recently 2 24mg sid. SDMA 19, USG 1.040, PH 8.5, dark yellow, turbid. 3+ struvite.

**ULTRASONOGRAPHIC EXAMINATION OF THE ABDOMEN**

**Urinary System**

The **urinary bladder**, trigone, and pelvic urethra presented normal thicknesses and normal tone. The pelvic urethra was imaged 2.0 cm beyond the cystourethral junction. The ureters were not visible which is normal. No uroliths or sediment were visualized and anechoic urine was present. No evidence of inflammatory or neoplastic changes was noted. Ureteral papillae were normal.

The **kidneys** revealed normal size and structure, corticomedullary definition and ratio for this age. The cortices presented largely uniform texture with normal echogenic relationship to liver and spleen. Medullary structure differed distinctly from the cortex and no evidence of pelvic dilation was present. The capsules were acceptably uniform without significant irregularities. The left kidney measured 5.9 cm. The right kidney measured 5.55 cm.

**Adrenal Glands**

Both **adrenal glands** were visualized and recognized as having normal shape, size, position and echogenicity for this breed. The phrenic vasculature, glandular echogenicity and detail were unremarkable. Capsule, cortex, and medullary definition were normal for this age patient. The left adrenal gland measured 2.66 x 0.47 cm at the cranial pole and 0.44 cm at the caudal pole. The right adrenal gland measured 1.99 x 1.42 cm at the cranial pole and 0.61 cm at the caudal pole.

**Spleen**

The **spleen** revealed minor, heterogenous parenchymal changes with scalloping contour. This is a progressive presentation compared to the prior sonogram. Variable swelling was noted with micronodular changes.

**Liver**

The **liver** images submitted revealed subjectively normal liver size, contour, and structure. Parenchymal echogenicity was naturally coarse and hypoechoic to the spleen. Vascular and biliary tracts were of normal volume with no evidence of congestion. The gallbladder presented acceptably thin walls with primarily anechoic content. The cystic and common bile ducts were normal. No pathological hepatic lymphadenopathy was evident. No overt structural evidence of inflammatory, infiltrative or regenerative pathology was evident.



**PATIENT**

**Gastrointestinal**

Minnie Brophy

Examination of the **gastrointestinal tract** revealed a stomach and intestine free of stasis, of normal wall thickness, acceptable curvilinear mural detail, and peristaltic activity. Small and large intestine demonstrated normal luminal chyme and stool consistency respectively. No obstructive or overt infiltrative disease was noted. No associated abnormal lymphatic activity was noted.

**SPECIES**

Canine

**BREED**

Boxer

**Pancreas**

The base and limbs of the **pancreas** were observed to be largely isoechoic to surrounding omental fat. Pancreatic duct and capsular contour were acceptably normal and parenchyma respected normal curvilinear patterns. No overt evidence of active inflammatory or neoplastic disease was noted.

**SEX**

Spayed Female

**Heart**

Rapid view of the heart revealed no evidence of pathology.

**AGE**

6 years

**ULTRASONOGRAPHIC FINDINGS**

**WEIGHT**

46 lbs

Heterogenous spleen with mild irregular contour and mild splenomegaly. Reactive spleen versus mast cell or splenitis.

**INTERPRETED BY**

Eric Lindquist, DMV  
DABVP, Cert. IVUSS

**INTERPRETATION OF THE FINDINGS & FURTHER RECOMMENDATIONS**

Given the patient's history Benadryl injection followed by FNA of the spleen is warranted.

**IMAGING PERFORMED BY**

Shari Reffi, CVT

**HOSPITAL NAME**

Long Valley AH

**REFERRING VET**

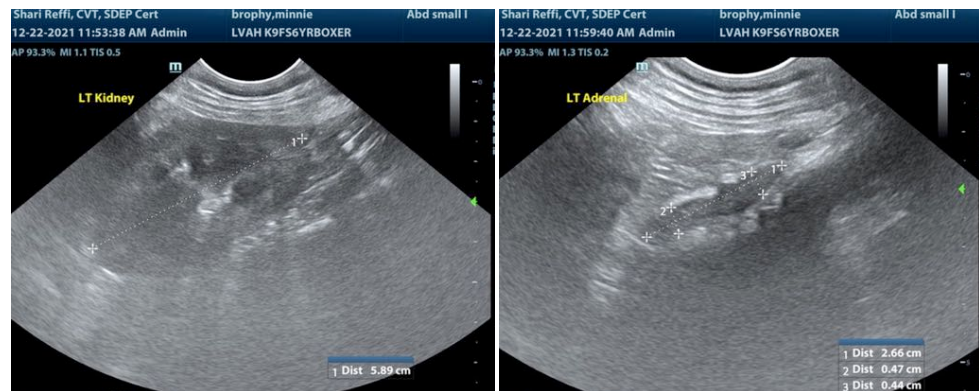
Dr. Earl

**INVOICE**

94832

**DATE**

12/22/21





**PATIENT**

Minnie Brophy

**SPECIES**

Canine

**BREED**

Boxer

**SEX**

Spayed Female

**AGE**

6 years

**WEIGHT**

46 lbs

**INTERPRETED BY**

Eric Lindquist, DMV  
DABVP, Cert. IVUSS

**IMAGING PERFORMED BY**

Shari Reffi, CVT

**HOSPITAL NAME**

Long Valley AH

**REFERRING VET**

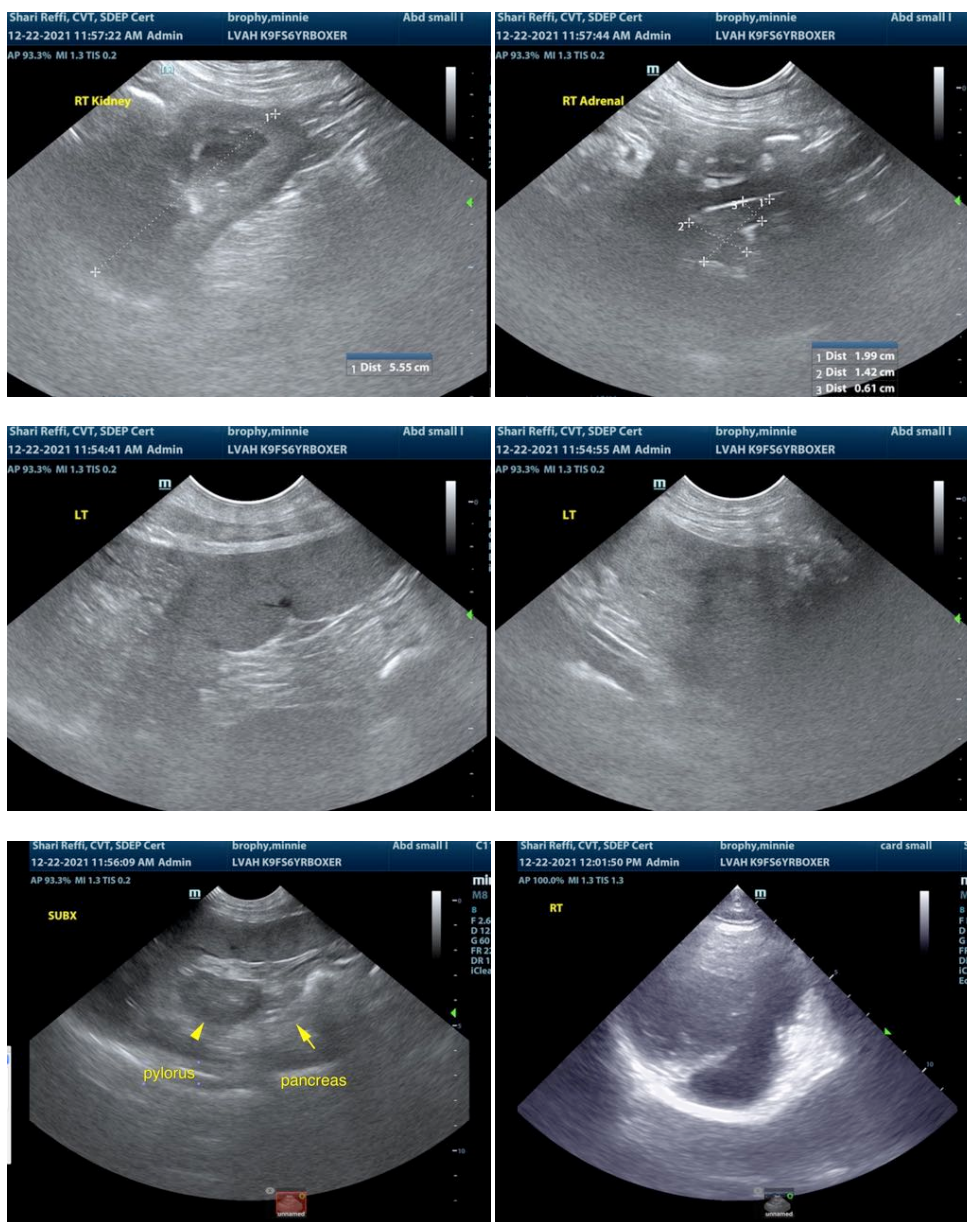
Dr. Earl

**INVOICE**

94832

**DATE**

12/22/21



The information and recommendations provided are based on the images presented by the referring veterinarian. No evaluation can be communicated regarding pathology that was not visible in the image/video clips provided.

Thank you for this referral. If the clinical or image interpretation does not parallel your findings or if I can be of any further assistance please contact me.

Eric Lindquist, DMV, DABVP, Cert. IVUSS, CEO of SonoPath.com  
Info@SonoPath.com