



PATIENT

Mia Jordan

SPECIES

Canine

BREED

West Highland White Terrier

SEX

Spayed Female

AGE

10 Years 10 Months

WEIGHT

23.8 Pounds

INTERPRETED BY

Eric Lindquist, DMV
DABVP, Cert. IVUSS

IMAGING PERFORMED BY

Dr. Ebersole

HOSPITAL NAME

Scanvet

REFERRING VET

Dr. Chadbourne

INVOICE

33679

DATE

12/22/21

PRESENTING CLINICAL SIGNS

Presented for annual exam with complaint of diarrhea x 2 weeks, decreased activity and progressive DJD. Vomited twice. Started Cerenia. On Galliprant.

Abnormal PE/Chem/CBC/UA Results: PE: distended abdomen with pot-bellied appearance. Bilateral carpal valgus with crepitus. PD Grade3. BUN 47, ALT 186, AST 57, ALP 2,086. Chol 527, CK 451. Mild monocytosis and mild reticulocytosis.

ULTRASONOGRAPHIC EXAMINATION OF THE ABDOMEN

Urinary System

The **bladder** in this patient was mildly thickened with slight echogenic mural changes. No calculi or masses were noted. Slight micropolypoid changes were noted. This is a frequent finding in older animals and may be linked to a history of chronic urinary tract infection or active urinary tract infection. Urinalysis would be recommended with culture if any evidence of inflammatory sediment is present. The region of the trigone and visible pelvic urethra were normal. The pelvic urethra was imaged 2.0 cm beyond the cystourethral junction.

The **kidneys** revealed largely normal size and structure, corticomedullary definition and ratio (cortex 1/3 of medulla) were essentially maintained with some age-related loss of curvilinear patterns regarding the capsule and C/M junction. The cortices presented largely uniform texture with some increased echogenicity expected for his age patient. Medullary structure differed distinctly from that of the cortex. The right kidney measured 5.5 cm with slight pyelectasia. The left kidney measured 5.12 cm.

Adrenal Glands

Both **adrenal glands** were visualized and recognized as having normal shape, size, position and echogenicity for this breed. The phrenic vasculature, glandular echogenicity and detail were unremarkable. Capsule, cortex, and medullary definition were normal for this age patient. The right adrenal gland measured 1.06 cm at the cranial pole and 0.48 cm at the caudal pole. The left adrenal gland measured 0.56 cm at the cranial pole and 0.48 cm at the caudal pole.

Spleen

The **spleen** presented a smooth homogeneous parenchyma hyperechoic to liver and renal cortical parenchyma. The capsule was smooth without noticeable expansion or deviation from within the spleen or adjacent pathology. The splenic vasculature demonstrated normal volume without signs of congestion or thrombosis. No sonographic evidence of acute or chronic inflammatory, neoplastic, or infarctual changes were noted.

Liver

The **liver** was uniformly swollen with minor, excessive gallbladder debris and over distension with dependent and suspended bile without evidence of overt mucocele formation. However, excessive sludge was present. The liver presented coarse architecture with mildly increased portal markings and subtle, mixed echogenic changes. This is consistent with vacuolar hepatopathy and some level of remodeling and history of inflammatory component. There was no overt suspicion of neoplasia.

Gastrointestinal

Minor retention of ingesta or soft shadowing material noted in the **pyloric** outflow, likely grass or similar. Mucosal speckling noted in portions of the small intestine, clinical significance of this is unclear.



PATIENT

Pancreas

Mia Jordan

The base and limbs of the **pancreas** were observed to be largely isoechoic to surrounding omental fat. Some parenchymal remodeling, however, with mild deviation from curvilinear normalcy was observed. Pancreatic duct and capsular irregularities were present consistent with age related changes. If pain upon imaging (+ Murphy sign) was present or if the patient is focally painful in subxyphoid palpation then low-grade smoldering chronic pancreatitis should be suspected.

SPECIES

Canine

BREED

West Highland White Terrier

- Mild pancreatic remodeling
- Age related changes otherwise

ULTRASONOGRAPHIC FINDINGS

SEX

Spayed Female

INTERPRETATION OF THE FINDINGS & FURTHER RECOMMENDATIONS

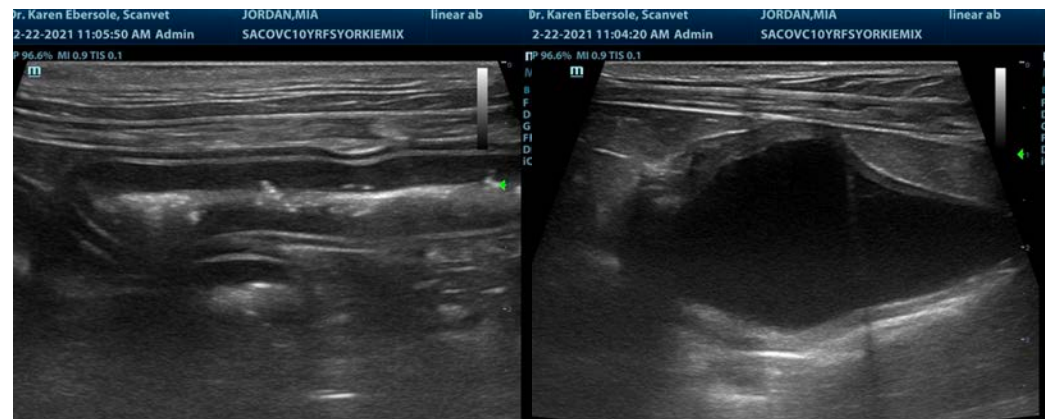
No evidence of significant disease. Largely expected changes for this age patient. History of pancreatitis likely given the pancreatic remodeling. However, no evidence of any significant active disease noted. Irritable bowel/inflammatory bowel likely. Hydrolyzed diet may be in this patient's best interest. 7-10 days Amoxicillin/Metronidazole recommended. If the patient's clinical signs resolve, then continuation on geriatric hydrolyzed diet would be recommended for long-term management.

AGE

10 Years 10 Months

WEIGHT

23.8 Pounds

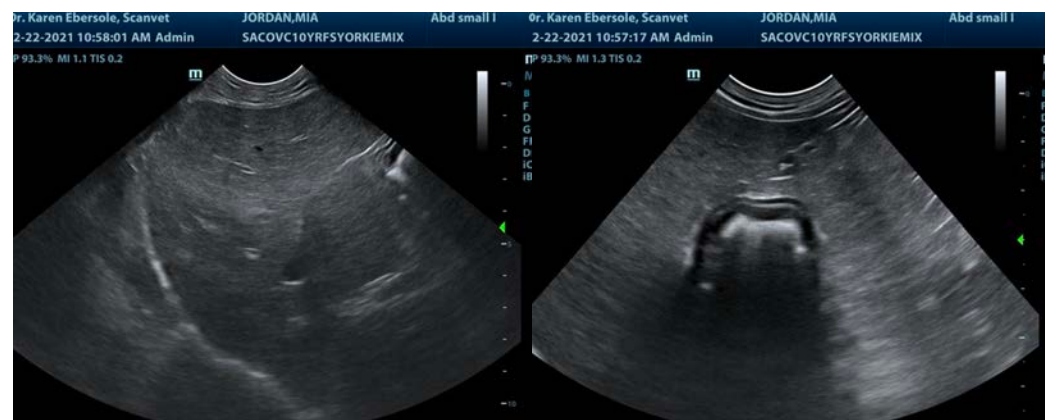


INTERPRETED BY

Eric Lindquist, DMV
DABVP, Cert. IVUSS

IMAGING PERFORMED BY

Dr. Ebersole



HOSPITAL NAME

Scanvet

REFERRING VET

Dr. Chadbourne

INVOICE

33679

DATE

12/22/21



PATIENT

Mia Jordan

SPECIES

Canine

BREED

West Highland White Terrier

SEX

Spayed Female

AGE

10 Years 10 Months

WEIGHT

23.8 Pounds

INTERPRETED BY

Eric Lindquist, DMV
DABVP, Cert. IVUSS

IMAGING PERFORMED BY

Dr. Ebersole

HOSPITAL NAME

Scanvet

REFERRING VET

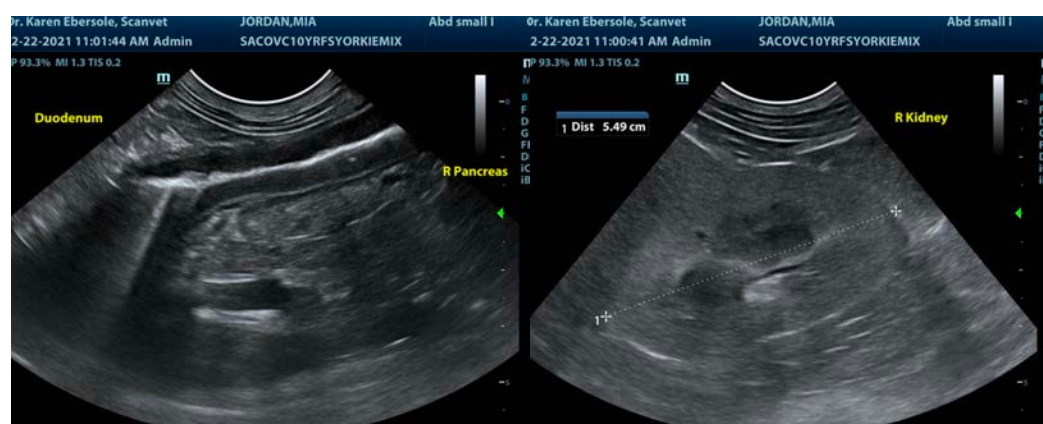
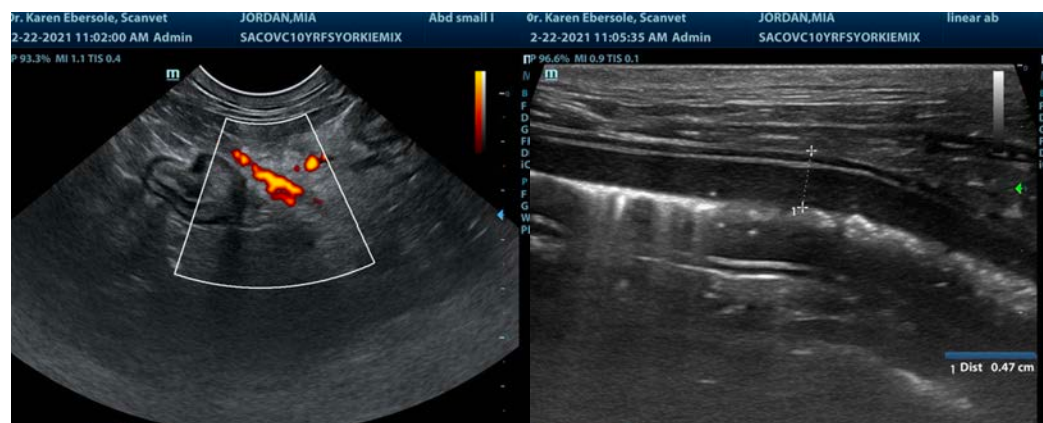
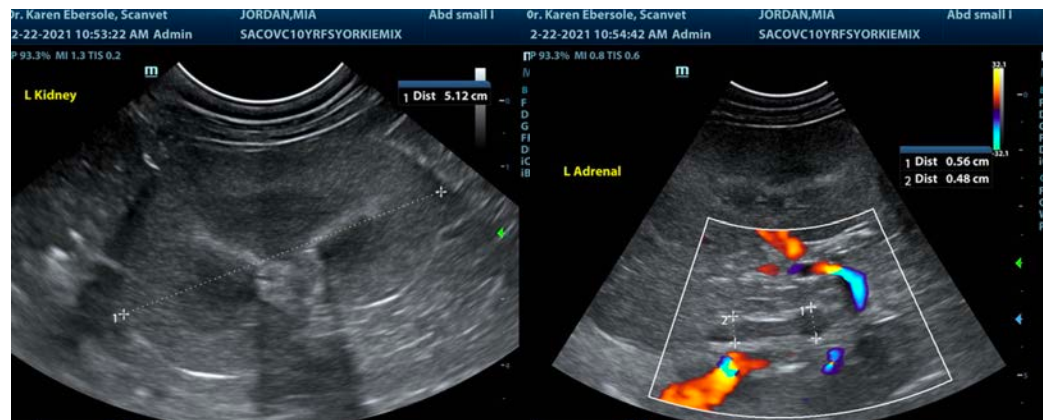
Dr. Chadbourne

INVOICE

33679

DATE

12/22/21





PATIENT

Mia Jordan

SPECIES

Canine

BREED

West Highland White Terrier

SEX

Spayed Female

AGE

10 Years 10 Months

WEIGHT

23.8 Pounds

INTERPRETED BY

Eric Lindquist, DMV
DABVP, Cert. IVUSS

IMAGING PERFORMED BY

Dr. Ebersole

HOSPITAL NAME

Scanvet

REFERRING VET

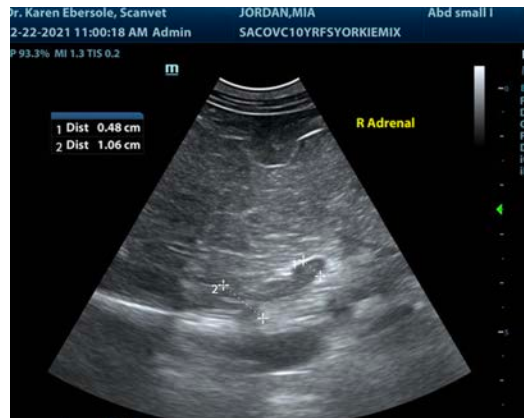Dr. Chadbourne

INVOICE

33679

DATE

12/22/21



The information and recommendations provided are based on the images presented by the referring veterinarian. No evaluation can be communicated regarding pathology that was not visible in the image/video clips provided.

Thank you for this referral. If the clinical or image interpretation does not parallel your findings or if I can be of any further assistance please contact me.

Eric Lindquist, DMV, DABVP, Cert. IVUSS, CEO of SonoPath.com
info@SonoPath.com