



<b>PATIENT</b>	<b>PRESENTING CLINICAL SIGNS</b>
Buddy Meixelsperger	History: Lethargy and inappetence for last couple days. Suspect splenic mass. Free fluid seen on fast scan.
<b>SPECIES</b>	<b>ULTRASONOGRAPHIC EXAMINATION OF THE ABDOMEN</b>
Canine	<i>Urinary System</i>
<b>BREED</b>	The <b>urinary bladder</b> , trigone, and pelvic urethra presented normal thicknesses and normal tone. The ureters were not visible which is normal. No uroliths or sediment were visualized and anechoic urine was present. No evidence of inflammatory or neoplastic changes was noted. Ureteral papillae were normal.
German Shepherd	
<b>SEX</b>	
Neutered male	The <b>kidneys</b> revealed normal size and structure, corticomedullary definition and ratio for this age. The cortices presented largely uniform texture with normal echogenic relationship to liver and spleen. Medullary structure differed distinctly from the cortex and no evidence of pelvic dilation was present. The capsules were acceptably uniform without significant irregularities. The kidneys each measured 6.0 cm.
<b>AGE</b>	
9 years	
<b>WEIGHT</b>	<i>Adrenal Glands</i>
95 lbs	Both <b>adrenal glands</b> were visualized and recognized as having normal shape, size, position and echogenicity for this breed. The phrenic vasculature, glandular echogenicity and detail were unremarkable. Capsule, cortex, and medullary definition were normal for this age patient. The left adrenal gland measured 0.72 cm. The right adrenal gland measured 0.76 cm. The right adrenal gland measured 0.76 cm.
<b>INTERPRETED BY</b>	
Eric Lindquist, DMV DABVP, Cert. IVUSS	
<b>IMAGING PERFORMED BY</b>	<i>Spleen</i>
Dr. Gromalak	The <b>spleen</b> was generally enlarged with heterogenous parenchymal changes. A mixed, echogenic parenchymal mass was noted and measured 6.0 + cm with other heterogenous nodular changes. Reactive omentum was noted around the mass with some areas of mild, heterogenous omentum. This may represent seeding. The splenic mass is mildly vascular.
<b>HOSPITAL NAME</b>	
SVS Imaging	
<b>REFERRING VET</b>	<i>Liver</i>
Dr. Dobbert	The <b>liver</b> images from right and left intercostal as well as subcostal views revealed subjectively normal liver size, contour, and structure. Some age-related parenchymal remodeling was noted but likely not clinically significant at this time. Vascular and biliary tracts were of normal volume and no evidence of congestion was noted. The gallbladder presented some dependent debris with essentially normal contour. The cystic and common bile ducts were normal. No overt evidence of active inflammatory, infiltrative or regenerative pathology was noted but should be paired with current or past LE elevations regarding any clinical significance to this presentation. The hepatic lymph nodes were unremarkable.
<b>INVOICE</b>	
94807	
<b>DATE</b>	
12/21/21	



<b>PATIENT</b>	<b>Gastrointestinal</b>
Buddy Meixelsperger	Examination of the <b>gastrointestinal tract</b> revealed a stomach and intestine free of stasis, of normal wall thickness, acceptable curvilinear mural detail, and peristaltic activity. There was some retention of ingesta in the stomach and gas accumulation. Small and large intestine demonstrated normal luminal chyme and stool consistency respectively. No obstructive or overt infiltrative disease was noted. No associated abnormal lymphatic activity was noted.
<b>SPECIES</b>	
Canine	
<b>BREED</b>	<b>Pancreas</b>
German Shepherd	The base and limbs of the <b>pancreas</b> were observed to be largely isoechoic to surrounding omental fat. Pancreatic duct and capsular contour were acceptably normal and parenchyma respected normal curvilinear patterns. No overt evidence of active inflammatory or neoplastic disease was noted.
<b>SEX</b>	
Neutered male	
<b>AGE</b>	<b>Free Abdomen</b>
9 years	A moderate amount of mildly echogenic free fluid was noted.
<b>WEIGHT</b>	<b>Heart</b>
95 lbs	Rapid view of the heart revealed a volume contracted heart and hypocontractility owing to volume contraction and potential emerging stage 1 shock.
<b>INTERPRETED BY</b>	<b>ULTRASONOGRAPHIC FINDINGS</b>
Eric Lindquist, DMV DABVP, Cert. IVUSS	Splenic mass.
<b>IMAGING PERFORMED BY</b>	<b>INTERPRETATION OF THE FINDINGS &amp; FURTHER RECOMMENDATIONS</b>
Dr. Gromalak	Plasma expanders are recommended with three view chest radiographs and immediate exploratory surgery. However, the surgeon should be prepared for possible omental seeding. Hemangiosarcoma is likely with a potential for round cell neoplasia. Benign hematoma is less likely. The prognosis is guarded to poor long term.
<b>HOSPITAL NAME</b>	
SVS Imaging	
<b>REFERRING VET</b>	
Dr. Dobbert	
<b>INVOICE</b>	
94807	
<b>DATE</b>	
12/21/21	



**PATIENT**

Buddy Meixelsperger

**SPECIES**

Canine

**BREED**

German Shepherd

**SEX**

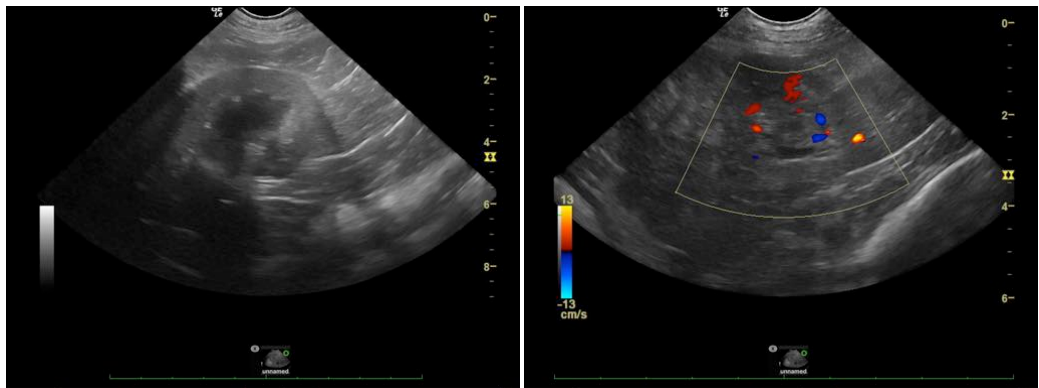
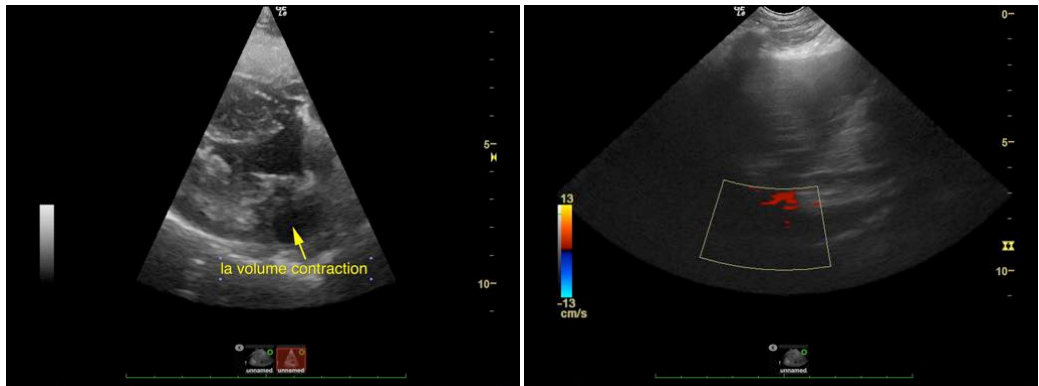
Neutered male

**AGE**

9 years

**WEIGHT**

95 lbs



**INTERPRETED BY**

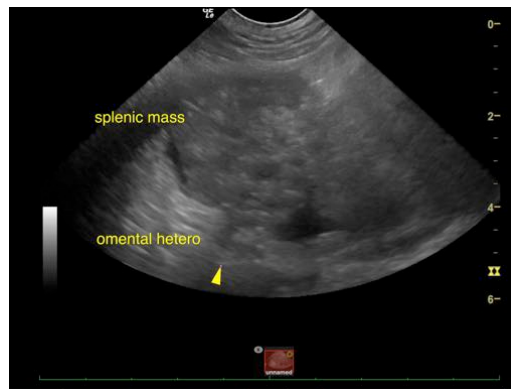
Eric Lindquist, DMV  
DABVP, Cert. IVUSS

**IMAGING PERFORMED BY**

Dr. Gromalak

**HOSPITAL NAME**

SVS Imaging



**REFERRING VET**

Dr. Dobbert

**INVOICE**

94807

**DATE**

12/21/21

The information and recommendations provided are based on the images presented by the referring veterinarian. No evaluation can be communicated regarding pathology that was not visible in the image/video clips provided.

Thank you for this referral. If the clinical or image interpretation does not parallel your findings or if I can be of any further assistance please contact me.

**Eric Lindquist, DMV, DABVP, Cert. IVUSS, CEO of SonoPath.com**  
info@SonoPath.com