



**PATIENT**

Ruby Melendez

**PRESENTING CLINICAL SIGNS**

History: poss parvo tested neg with gastroenteritis

**SPECIES**

Canine

**ULTRASONOGRAPHIC EXAMINATION OF THE ABDOMEN**

**Urinary System**

**BREED**

Pitbull

The **urinary bladder**, trigone, and pelvic urethra presented normal thicknesses and normal tone. The ureters were not visible which is normal. No uroliths or sediment were visualized and anechoic urine was present. No evidence of inflammatory or neoplastic changes was noted. Ureteral papillae were normal.

**SEX**

Female

The **kidneys** revealed normal size and structure, corticomedullary definition and ratio for this age. The cortices presented largely uniform texture with normal echogenic relationship to liver and spleen. Medullary structure differed distinctly from the cortex and no evidence of pelvic dilation was present. The capsules were acceptably uniform without significant irregularities. The left kidney measured 6.0 cm.

**AGE**

5 months

**WEIGHT**

27.5 lbs

**Adrenal Glands**

Both **adrenal glands** were visualized and recognized as having normal shape, size, position and echogenicity for this breed. The phrenic vasculature, glandular echogenicity and detail were unremarkable. Capsule, cortex, and medullary definition were normal for this age patient. The right adrenal gland measured 1.76 x 1.58 cm at the cranial pole and 0.72 cm at the caudal pole. The left adrenal gland measured 2.96 x 0.6 cm at the caudal pole and 0.71 cm at the cranial pole.

**INTERPRETED BY**

Eric Lindquist, DMV  
DABVP, Cert. IVUSS

**IMAGING PERFORMED BY**

Jenn

**Spleen**

The **spleen** presented a smooth homogeneous parenchyma hyperechoic to liver and renal cortical parenchyma. The capsule was smooth without noticeable expansion or deviation from within the spleen or adjacent pathology. The splenic vasculature demonstrated normal volume without signs of congestion or thrombosis. No sonographic evidence of acute or chronic inflammatory, neoplastic, or infarctual changes was noted.

**HOSPITAL NAME**

Rockaway AH

**REFERRING VET**

Dr. Maniar

**Liver**

The **liver** images submitted revealed subjectively normal liver size, contour, and structure. Parenchymal echogenicity was naturally coarse and hypoechoic to the spleen. Vascular and biliary tracts were of normal volume with no evidence of congestion. The gallbladder presented acceptably thin walls with primarily anechoic content. The cystic and common bile ducts were normal. No pathological hepatic lymphadenopathy was evident. No overt structural evidence of inflammatory, infiltrative or regenerative pathology was evident.

**INVOICE**

42266

**DATE**

12/21/22



**PATIENT**

**Gastrointestinal**

Ruby Melendez

Examination of the **gastrointestinal tract** revealed an unremarkable stomach and small intestine regarding structure. There were minor areas of luminal fluid noted. There was no evidence of obstructive pattern. Curvilinear patterns were retained throughout the gastrointestinal tract. Areas of hyperperistalsis were noted. This is consistent with response to irritation. The colon was unremarkable.

**SPECIES**

Canine

**BREED**

Pitbull

**SEX**

Female

**AGE**

5 months

**WEIGHT**

27.5 lbs

**Pancreas**

The **pancreas** was hypoechoic and mildly irregular. There is a potential for low grade inflammation.

**ULTRASONOGRAPHIC FINDINGS**

Gastroenteritis, consistent with Parvo virus or other insults.

Prominent, irregular pancreas, likely concurrent pancreatitis.

**INTERPRETATION OF THE FINDINGS & FURTHER RECOMMENDATIONS**

24-hour n.p.o., plasma expanders, treatment for enterotoxins, GI Protectants and anti-parasitic protocol is all indicated.

**INTERPRETED BY**

Eric Lindquist, DMV  
DABVP, Cert. IVUSS

**IMAGING PERFORMED BY**

Jenn

**HOSPITAL NAME**

Rockaway AH

**REFERRING VET**

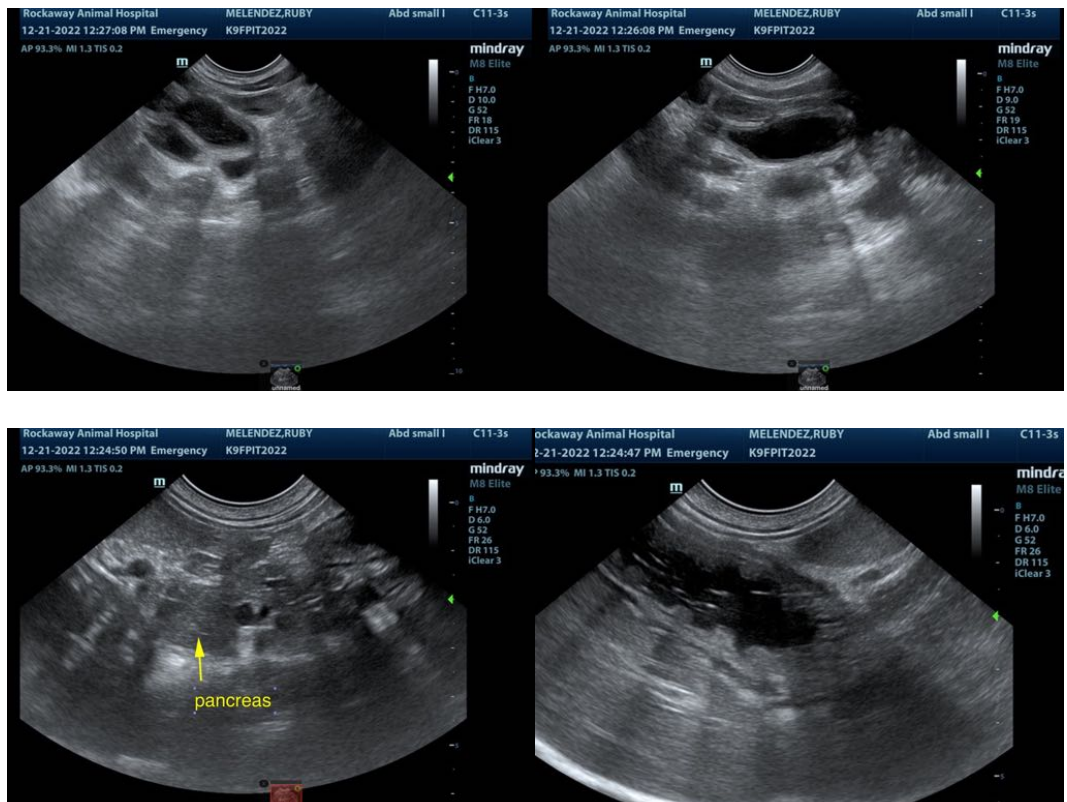
Dr. Maniar

**INVOICE**

42266

**DATE**

12/21/22





**PATIENT**

Ruby Melendez

**SPECIES**

Canine

**BREED**

Pitbull

**SEX**

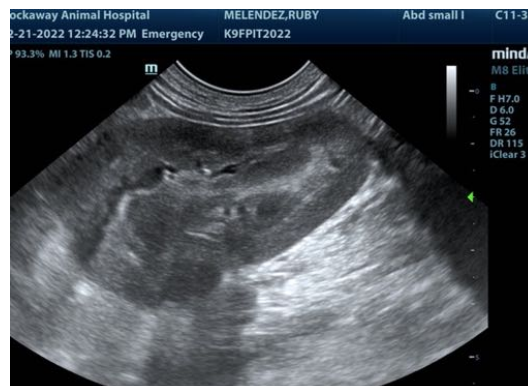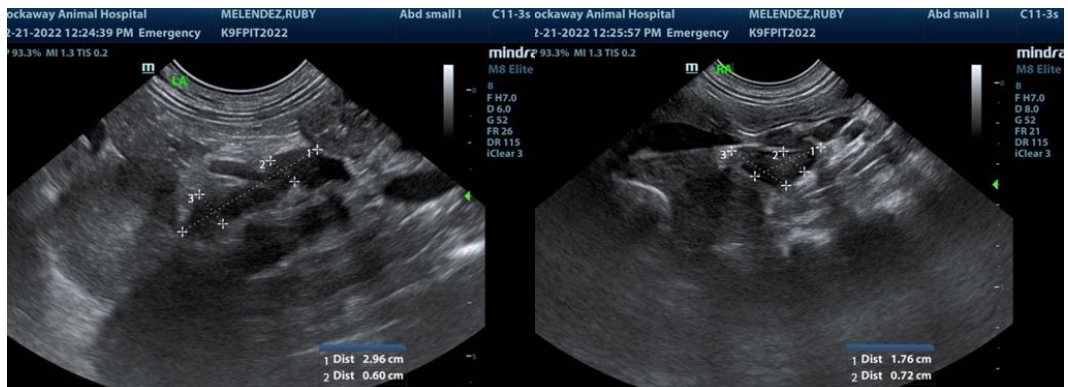
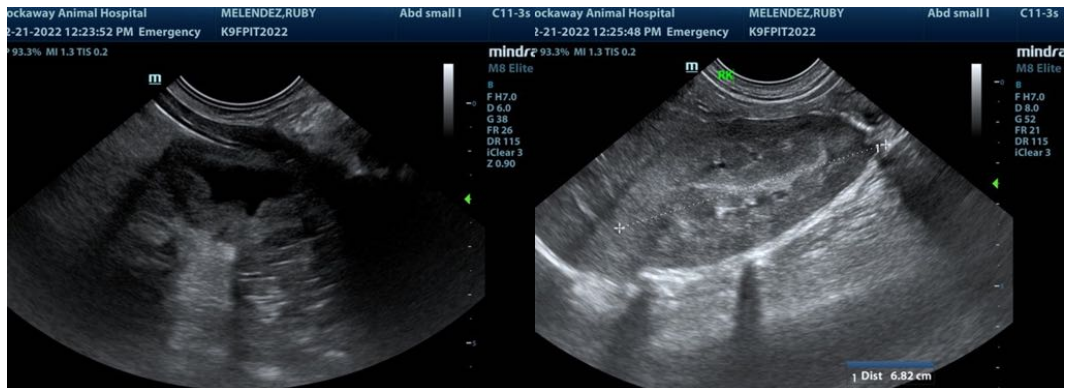
Female

**AGE**

5 months

**WEIGHT**

27.5 lbs



**INTERPRETED BY**

Eric Lindquist, DMV  
DABVP, Cert. IVUSS

**IMAGING PERFORMED BY**

Jenn

**HOSPITAL NAME**

Rockaway AH

**REFERRING VET**

Dr. Maniar

**INVOICE**

42266

**DATE**

12/21/22

The information and recommendations provided are based on the images presented by the referring veterinarian/sonographer. No evaluation can be communicated regarding pathology that was not visible in the image/video clips provided.

Thank you for this referral. If the clinical or image interpretation does not parallel your findings or if I can be of any further assistance please contact me.

**Eric Lindquist, DMV, DABVP, Cert. IVUSS, CEO of SonoPath.com**  
info@SonoPath.com