# SonoPath
Clinical Sonography & Telecytology

EDUCATIONAL TELECONSULTATION SERVICES™

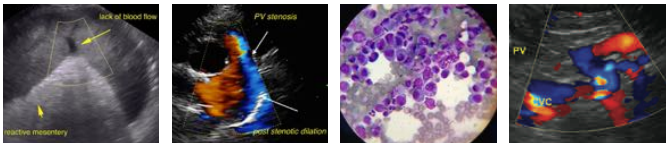


SonoPath.com
1-800-838-4268 info@sonopath.com

**PATIENT**

Oliver Zisa

**SPECIES**

Canine

**BREED**

Havanese

**SEX**

Male

**AGE**

15 years

**INTERPRETED BY**

Eric Lindquist, DMV
DABVP, Cert. IVUSS

**IMAGING PERFORMED BY**

Eric Lindquist, DMV
DABVP, Cert. IVUSS

**HOSPITAL NAME**

Butler Vet

**REFERRING VET**

Dr. Garro

**INVOICE**

94777

**DATE**

12/21/21

## PRESENTING CLINICAL SIGNS

Recent anemia and thrombocytopenia.

ALT 190, GGT 33,

## ULTRASONOGRAPHIC EXAMINATION OF THE ABDOMEN

### *Urinary System*

The **urinary bladder**, trigone, and pelvic urethra presented normal thicknesses and normal tone. The ureters were not visible which is normal. No uroliths or sediment were visualized and anechoic urine was present. No evidence of inflammatory or neoplastic changes was noted. Ureteral papillae were normal.

The **kidneys** revealed largely normal size and structure, corticomedullary definition and ratio (cortex 1/3 of medulla) were essentially maintained with some age-related loss of curvilinear patterns regarding the capsule and C/M junction. The cortices presented largely uniform texture with some increased echogenicity expected for this age patient. Medullary structure differed distinctly from that of the cortex. Slight pyelectasia was noted. The left kidney measured 4.21 cm. The right kidney measured 4.55 cm.

### *Adrenal Glands*

Both **adrenal glands** were visualized and recognized as having largely normal shape, size, position and acceptable echogenicity for this age group and breed. Some heterogeneity was noted within the adrenal parenchyma without concerning capsular distortion. These changes are likely age related but should be monitored by sonogram should the patient be suspected of having adrenal disease. The left adrenal gland measured 2.13 x 0.46 cm. The right adrenal gland measured 1.81 x 0.99 cm at the cranial pole and 0.6 cm at the caudal pole.

### *Spleen*

The **spleen** revealed multi-focal, mixed, hypoechoic distorted target nodule and heterogenous changes.

### *Liver*

The **liver** was riddled with multiple, disruptive, mixed echogenic and target lesions with capsular expansion. An overt 4.8 x 3.8 cm partially cavitated mass was noted. The gallbladder revealed minor polyps.

### *Gastrointestinal*

Examination of the **gastrointestinal tract** revealed a stomach and intestine free of stasis, of normal wall thickness, acceptable curvilinear mural detail, and peristaltic activity. Small and large intestine demonstrated normal luminal chyme and stool consistency respectively. No obstructive or overt infiltrative disease was noted. No associated abnormal lymphatic activity was noted.

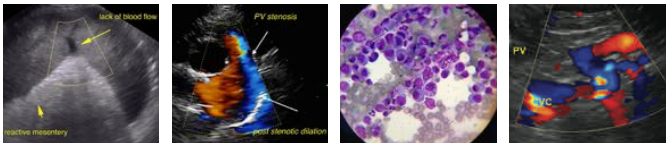

SonoPath.com
1-800-838-4268 info@sonopath.com

**PATIENT**

Oliver Zisa

**SPECIES**

Canine

**BREED**

Havanese

**SEX**

Male

**AGE**

15 years

**INTERPRETED BY**

Eric Lindquist, DMV
DABVP, Cert. IVUSS

**IMAGING PERFORMED BY**

Eric Lindquist, DMV
DABVP, Cert. IVUSS

**HOSPITAL NAME**

Butler Vet

**REFERRING VET**

Dr. Garro

**INVOICE**

94777

**DATE**

12/21/21

## *Pancreas*

The base and limbs of the **pancreas** were observed to be largely isoechoic to surrounding omental fat. Some parenchymal remodeling, however, with mild deviation from curvilinear normalcy was observed. Pancreatic duct and capsular irregularities were present consistent with age related changes. If pain upon imaging (+ Murphy sign) was present or if the patient is focally painful in subxiphoid palpation then low-grade smoldering chronic pancreatitis should be suspected.

## ULTRASONOGRAPHIC FINDINGS

Splenohepatic neoplastic pattern with distorted targets and cavitation. Strongly suggestive for hemangiosarcoma or similar neoplasia.

Otherwise, geriatric abdominal changes.

## INTERPRETATION OF THE FINDINGS & FURTHER RECOMMENDATIONS

Ultrasound guided FNA of the spleen and liver is recommended.

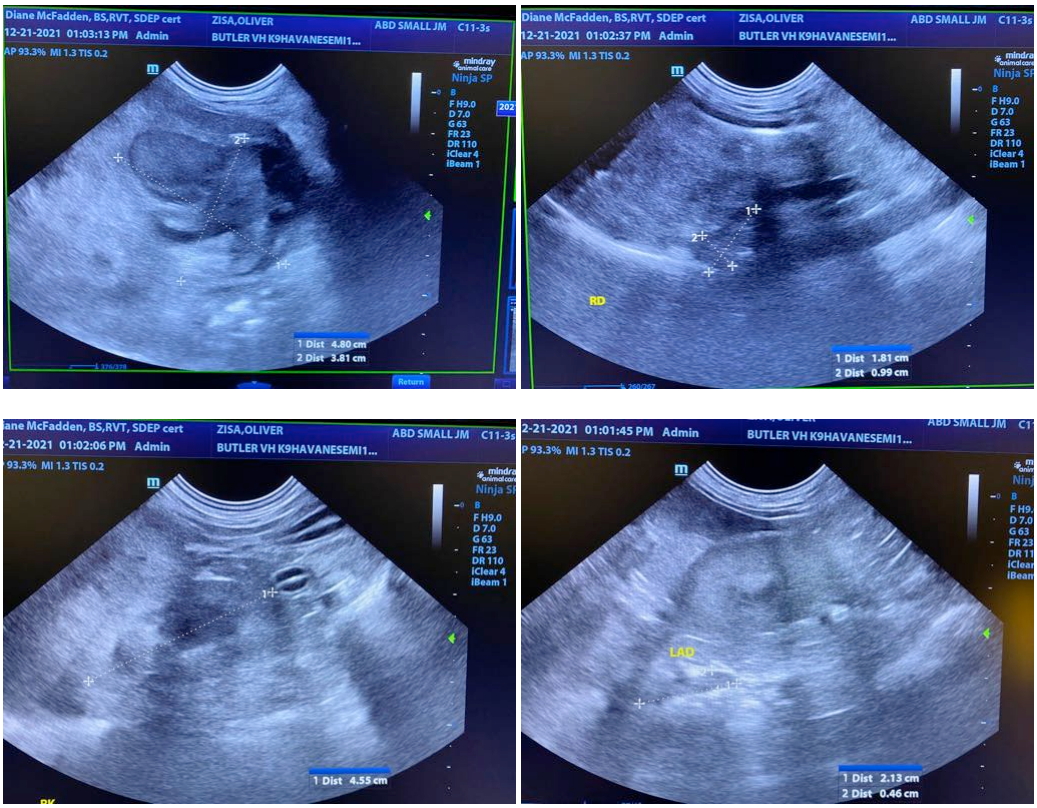

# SonoPath

*Clinical Sonography & Telecytology*

EDUCATIONAL TELECONSULTATION SERVICES™

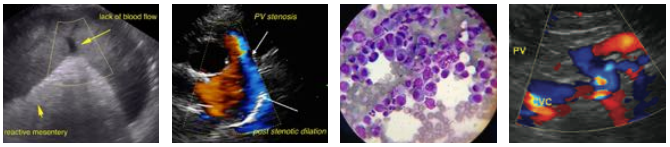

SonoPath.com™
1-800-838-4268 info@sonopath.com

**PATIENT**

Oliver Zisa

**SPECIES**

Canine

**BREED**

Havanese

**SEX**

Male

**AGE**

15 years

**INTERPRETED BY**

Eric Lindquist, DMV
DABVP, Cert. IVUSS

**IMAGING PERFORMED BY**

Eric Lindquist, DMV
DABVP, Cert. IVUSS

**HOSPITAL NAME**

Butler Vet

**REFERRING VET**

Dr. Garro

**INVOICE**

94777

**DATE**

12/21/21

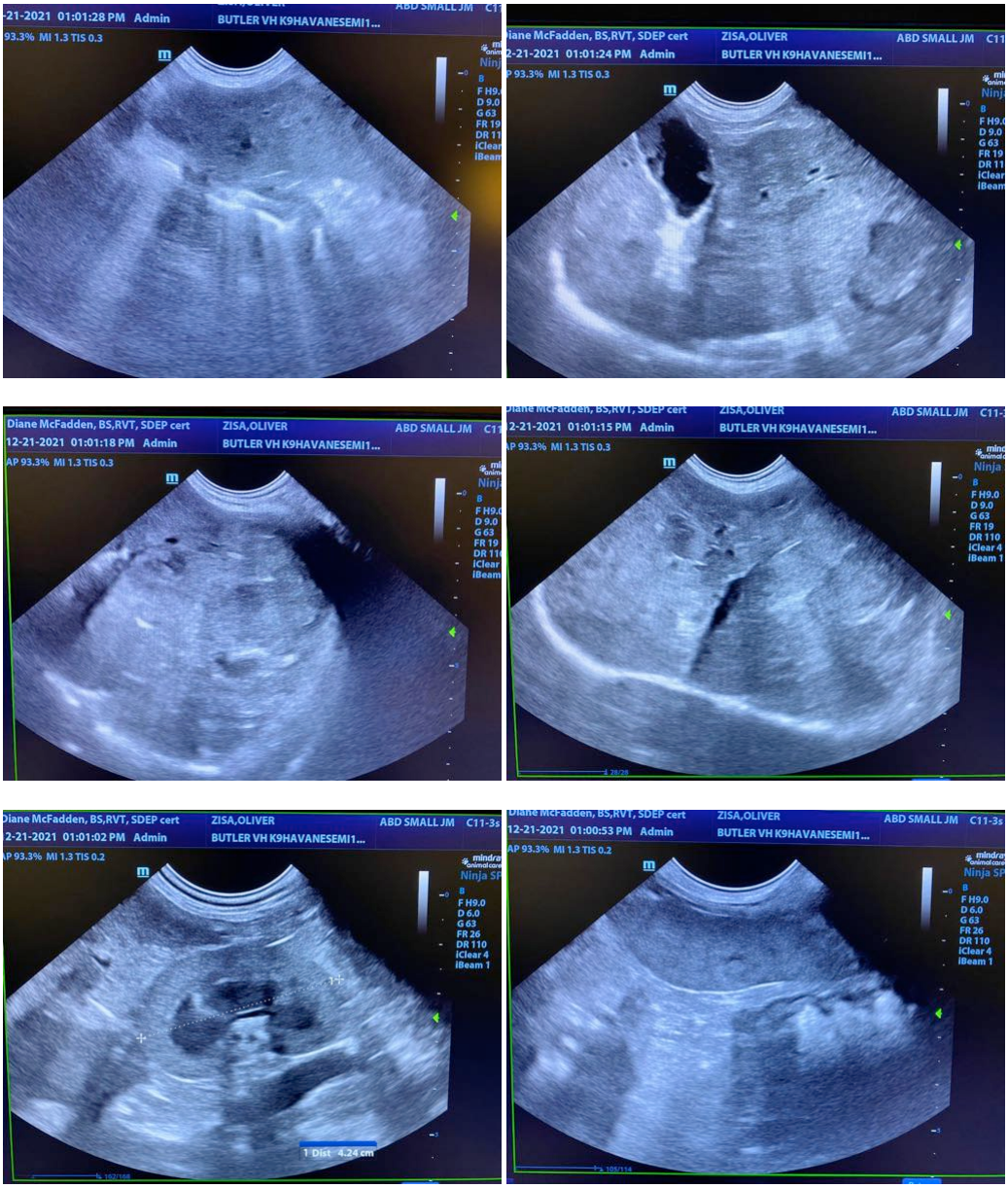


**The information and recommendations provided are based on the images presented by the referring veterinarian. No evaluation can be communicated regarding pathology that was not visible in the image/video clips provided.**

Thank you for this referral. If the clinical or image interpretation does not parallel your findings or if I can be of any further assistance please contact me.

**Eric Lindquist**, DMV, DABVP, Cert. IVUSS, CEO of SonoPath.com
Info@SonoPath.com