



PATIENT PRESENTING CLINICAL SIGNS

Nicky Lundeen
Hair loss over the last year, some increase in water consumption. Overall, feels good and has a good appetite, but not voracious. Pruritus unknown, but does have a few scabs on body. Owner thinks that vulva sometimes appears enlarged.

SPECIES
Abnormal PE/Chem/CBC/UA Results: Bilateral, symmetrical, hair loss over caudal body. No labs performed at this time as would need full anesthesia. DDX - adrenocortical disease, pancreatic disease, splenic disease

Feline

BREED ULTRASONOGRAPHIC EXAMINATION OF THE ABDOMEN

Ferret Urinary System

SEX
The **urinary bladder**, trigone, and pelvic urethra presented normal thicknesses and normal tone. The ureters were not visible which is normal. No uroliths or sediment were visualized and anechoic urine was present. No evidence of inflammatory or neoplastic changes were noted. Ureteral papillae were normal. The pelvic urethra was imaged 1.0 cm beyond the cystourethral junction.

Spayed Female

AGE
The **kidneys** revealed largely normal size and structure, corticomedullary definition and ratio (cortex 1/3 of medulla) were essentially maintained with some age-related loss of curvilinear patterns regarding the capsule and C/M junction. The cortices presented largely uniform texture with some increased echogenicity expected for his age patient. Medullary structure differed distinctly from that of the cortex and no evidence of pelvic dilation was present. The right kidney measured 2.7 cm. The left kidney measured 2.6 cm.

8 Years

WEIGHT Adrenal Glands

795 Grams
An irregular mass was noted in the region of the **left adrenal gland**, measuring 1.0 cm and was irregular in contour with enhanced surrounding mesentery. Enlarged lymph nodes noted in the region of the **right adrenal gland**. The right adrenal could not be completely differentiated.

INTERPRETED BY Spleen

Eric Lindquist, DMV
DABVP, Cert. IVUSS
The **spleen** was enlarged, micronodular and slightly irregular.

IMAGING PERFORMED BY Liver

Dr. Jolee Stegemoller
The **liver** presented mild coarse architecture and increased portal markings. Minor gallbladder thickening noted, consistent with history of cholangitis.

HOSPITAL NAME Gastrointestinal

North Idaho AH
The **stomach** was unremarkable. Variable intestinal thickening noted with some areas of loss of detail.

REFERRING VET Pancreas

Dr. Jolee Stegemoller
The **pancreas** was hypoechoic and irregular with undulating contour.

Free Abdomen

INVOICE
A 1.6 cm x 1.3 cm hypoechoic, undifferentiated mass was noted. A separate elongated 2.2 cm x 0.7 cm mass was also present. Both masses appeared to be lymph nodes. Multiple other smaller lymph nodes were enlarged.

33645

DATE ULTRASONOGRAPHIC FINDINGS

- 12/22/21
- Mesenteric lymphadenopathy
 - Enlarged, irregular spleen



PATIENT

Nicky Lundeen

- Left adrenal mass
- Variable intestinal thickening
- Hypoechoic pancreas

SPECIES

Feline

INTERPRETATION OF THE FINDINGS & FURTHER RECOMMENDATIONS

There are multiple issues in this patient. Suspect lymphoma as well as left adrenal neoplasia. Recommend 35-gauge FNA spleen and lymph nodes in this patient to assess for potential underlying lymphoma. Prognosis is guarded. Medical management for adrenal cortical disease recommended.

BREED

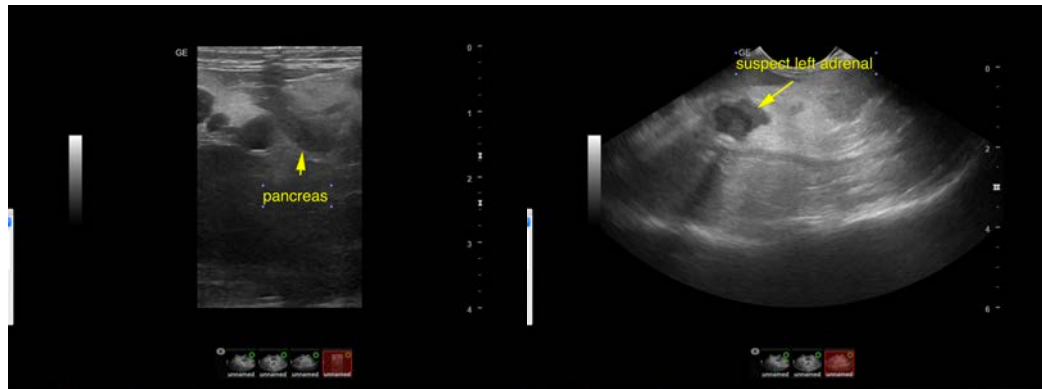
Ferret

SEX

Spayed Female

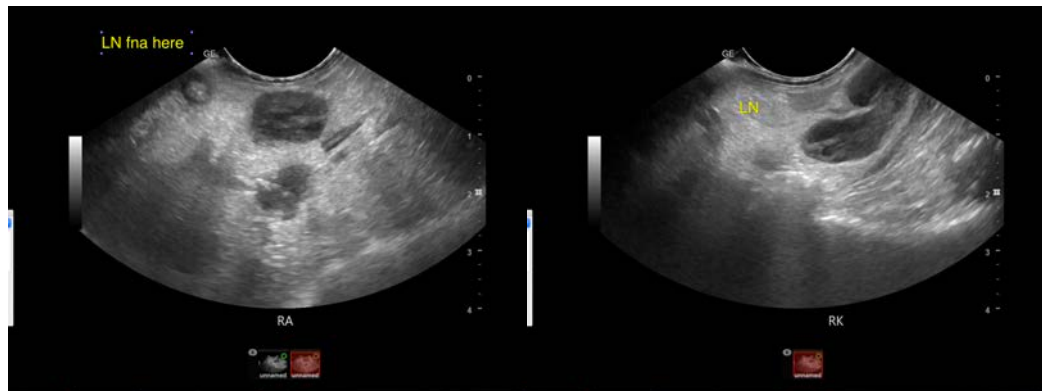
AGE

8 Years



WEIGHT

795 Grams



INTERPRETED BY

Eric Lindquist, DMV
DABVP, Cert. IVUSS

IMAGING PERFORMED BY

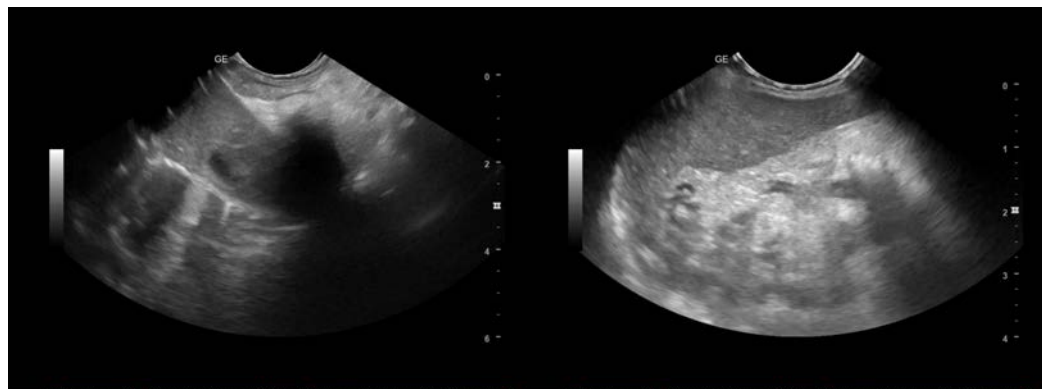
Dr. Jolee Stegemoller

HOSPITAL NAME

North Idaho AH

REFERRING VET

Dr. Jolee Stegemoller



INVOICE

33645

DATE

12/22/21



PATIENT

Nicky Lundeen

SPECIES

Feline

BREED

Ferret

SEX

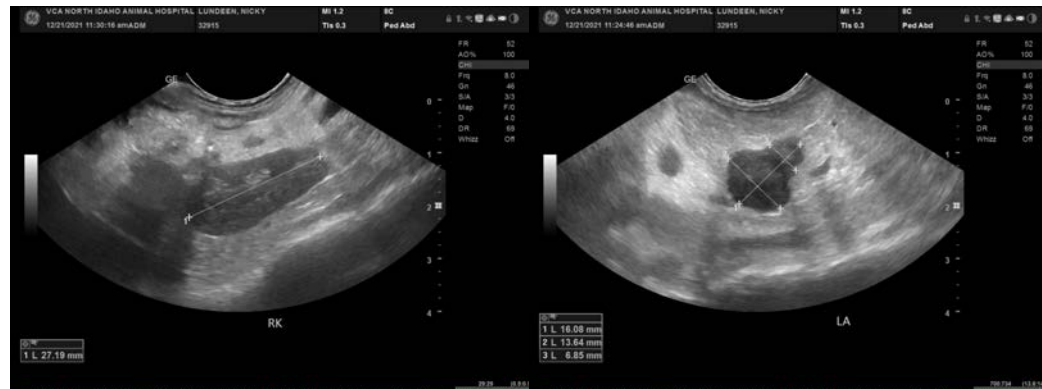
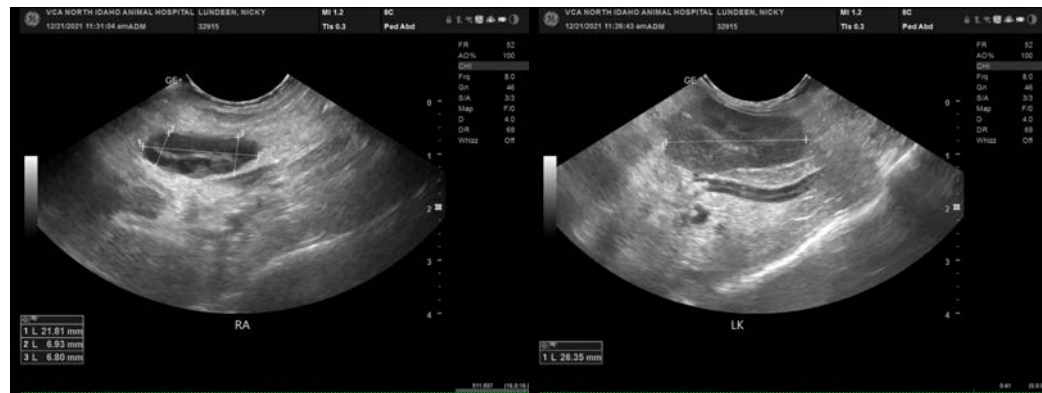
Spayed Female

AGE

8 Years

WEIGHT

795 Grams



INTERPRETED BY

Eric Lindquist, DMV
DABVP, Cert. IVUSS

IMAGING PERFORMED BY

Dr. Jolee Stegemoller

HOSPITAL NAME

North Idaho AH

REFERRING VET

Dr. Jolee Stegemoller

INVOICE

33645

DATE

12/22/21

The information and recommendations provided are based on the images presented by the referring veterinarian. No evaluation can be communicated regarding pathology that was not visible in the image/video clips provided.

Thank you for this referral. If the clinical or image interpretation does not parallel your findings or if I can be of any further assistance please contact me.

Eric Lindquist, DMV, DABVP, Cert. IVUSS, CEO of SonoPath.com
info@SonoPath.com