



PATIENT

Milo Goodman

PRESENTING CLINICAL SIGNS

History: Grade II/VI heart murmur, has had since birth- previous echo unremarkable but heart murmur a bit louder

SPECIES

Canine

ULTRASONOGRAPHIC EXAMINATION OF THE HEART

BREED

Cavapoo

SEX

Neutered male

AGE

4 years

The echocardiogram in this patient demonstrated normal **left atrial** size based on 3 separate methods of LA evaluation. **Mitral** valve insufficiency was noted. The **left ventricle** presented thicknesses with linear contour and was not dilated nor restricted. The **myocardium** presented normal echogenicity without subjective evidence of significant fibrotic or ischemic disease. **Contractility** of the ventricular walls was adequate and in normal range for this patient evidenced by the fractional shortening measurement and subjective evaluation of the different regions of the myocardium. The aortic valve was thickened and elongated. **Aortic insufficiency** was present at 5.0 m/sec. This is consistent with subaortic stenosis. The aortic valve was slightly thickened. This is likely a congenital lesion. The **right atrium** and auricle revealed normal size, structure and content. No evidence of masses was noted. **Tricuspid** insufficiency was noted. The **right ventricle** was of normal size (1/3 diameter of LV), chordae structure, myocardial echogenicity and thickness. **Pulmonary outflow** tract assessment revealed normal valve structure, laminar flow, and diameter (approx. 1:1 pa/ao ratio). No visible **pericardial** or free pleura fluid was noted. The cranial **mediastinum and pericardial and extra-cardiac regions** were free of masses in the visible window.

WEIGHT

29 lbs

INTERPRETED BY

Eric Lindquist, DMV
DABVP, Cert. IVUSS

CANINE CARDIAC PARAMETERS	MR VMAX (m/s)	TR VMAX (m/s)	LA/AO (Boon method)	LA/AO (Heart Base; Swe)	FS (%)	EF (%)	EPSS (cm)
NORMAL PARAMETER	4.5-5.5	<2.7	1.3	<1.6	28-40	40-100	<0.6
PATIENT		1.91	1.05		42	75	0.1
CANINE CARDIAC PARAMETERS	HR (BPM)	AV VMAX (m/s)	PV MAX (m/s)	BODY WEIGHT	LA 2D short axis Base view (cm)	LVIDd Avg; 2D and m- mode short axis (cm)	LVIDs Avg; 2D and m-mode short axis (cm)
NORMAL PARAMETER	50-100	0.7-1.7	0.7-1.6				
PATIENT	147	3.0	1.19	29 lbs	2.62	2.9	

Dr. Herzog

ULTRASONOGRAPHIC FINDINGS

INVOICE

94786

Subaortic stenosis with secondary aortic insufficiency.

Trivial mitral insufficiency, compensated at this time.

DATE

12/15/21



PATIENT

Milo Goodman

INTERPRETATION OF THE FINDINGS & FURTHER RECOMMENDATIONS

A recheck echocardiogram is recommended in 6 months. The breeding line should be evaluated for similar changes as this is a congenital lesion.

SPECIES

Canine

BREED

Cavapoo

SEX

Neutered male

AGE

4 years

WEIGHT

29 lbs

INTERPRETED BY

Eric Lindquist, DMV
DABVP, Cert. IVUSS

IMAGING PERFORMED BY

Jessica Miller, RDMS

HOSPITAL NAME

The Venturing Vet

REFERRING VET

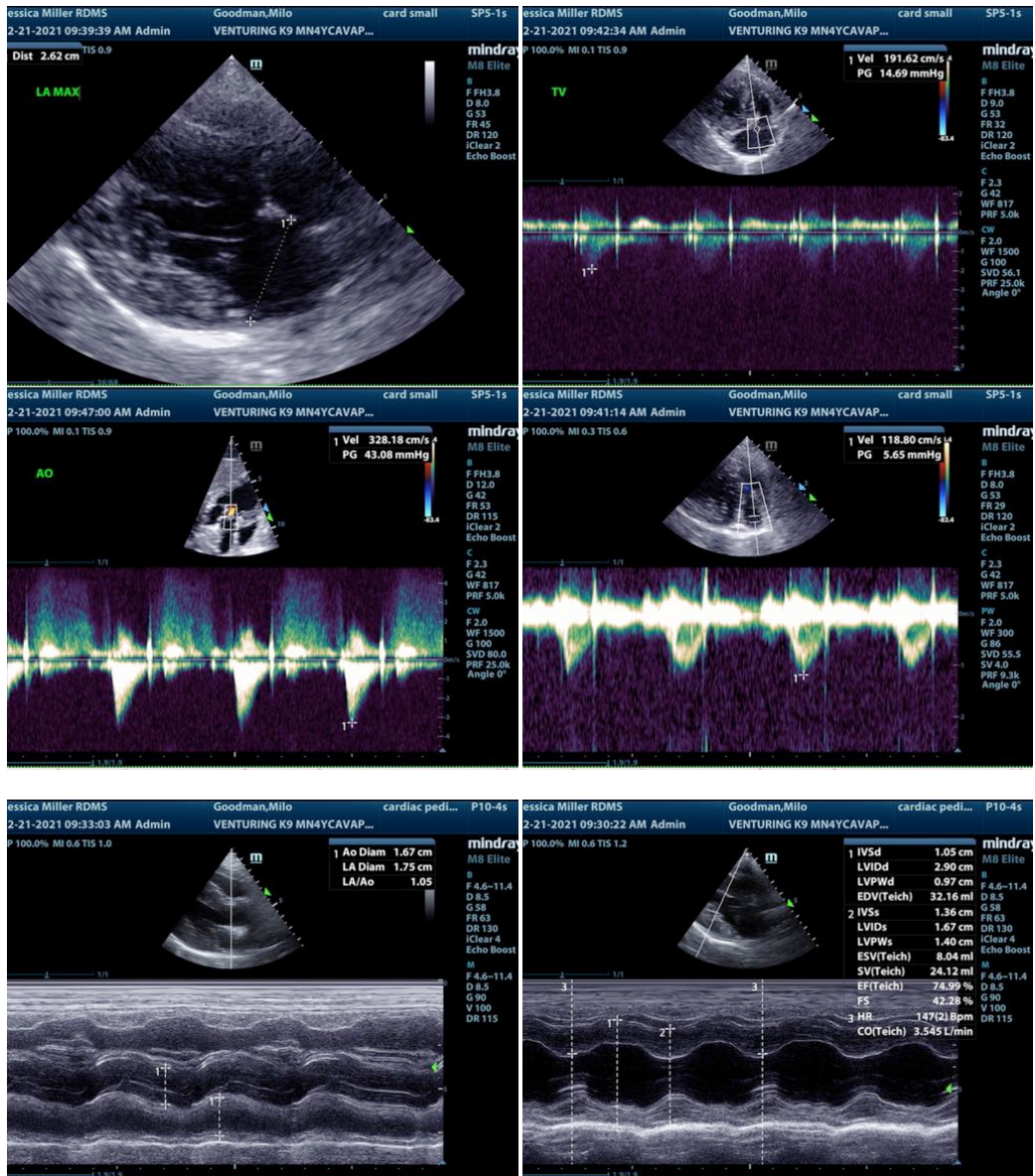
Dr. Herzog

INVOICE

94786

DATE

12/15/21





PATIENT

Milo Goodman

SPECIES

Canine

BREED

Cavapoo

SEX

Neutered male

AGE

4 years

WEIGHT

29 lbs

INTERPRETED BY

Eric Lindquist, DMV
DABVP, Cert. IVUSS

IMAGING PERFORMED BY

Jessica Miller, RDMS

HOSPITAL NAME

The Venturing Vet

REFERRING VET

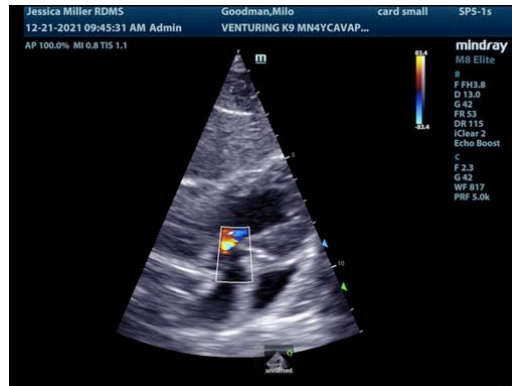Dr. Herzog

INVOICE

94786

DATE

12/15/21



The information and recommendations provided are based on the images presented by the referring veterinarian. No evaluation can be communicated regarding pathology that was not visible in the image/video clips provided.

Thank you for this referral. If the clinical or image interpretation does not parallel your findings or if I can be of any further assistance please contact me.

Eric Lindquist, DMV, DABVP, Cert. IVUSS, CEO of SonoPath.com
info@SonoPath.com