



**PATIENT PRESENTING CLINICAL SIGNS**

JR Ferro Diagnosed with HCM at another hospital. Grade II heart murmur.

**SPECIES ULTRASONOGRAPHIC EXAMINATION OF THE HEART**

Feline

**BREED**

Domestic Shorthair

**SEX**

Neutered male

**AGE**

11 years

The **left atrium** was at the upper limits of normal. The cranial and caudal **mitral valve** leaflets appeared mildly thickened with some insufficiency noted on Doppler. The **left ventricle** presented excessive free wall and septal thicknesses with hypertrophic thicknesses compared to normal for this species. The **myocardium** presented essentially normal echogenicity without immediate signs of fibrotic or ischemic disease. **Contractility** of the ventricular walls was considered excessive for this patient evidenced by the elevated fractional shortening measurement. The **left ventricular outflow** tract demonstrated turbulent laminar flow. Subjective assessment of the **right atrium** and auricle revealed normal size, structure and content. No evidence of masses was noted. **Tricuspid** insufficiency was noted. The **right ventricle** was of normal size with normal chordae structure, myocardial echogenicity and thickness. **Pulmonic** tract assessment revealed normal valve structure, laminar flow, and diameter. No visible **pericardial** or free pleura fluid was noted. No echographically detectable evidence of infiltrative disease was visible. The **mediastinum** was free of masses in the visible window.

**INTERPRETED BY**

Eric Lindquist, DMV  
DABVP, Cert. IVUSS

**IMAGING PERFORMED BY**

Eric Lindquist, DMV  
DABVP, Cert. IVUSS

**HOSPITAL NAME**

HoHoKus VH

**REFERRING VET**

Dr. Scott

FELINE CARDIAC PARAMETERS	BODY WEIGHT (kg)	HR (BPM)	IVSd (cm)	LVIDd (cm)	LVWd (cm)	FS (%)	EF (%)
NORMAL PARAMETER	-----	150-240	0.3-0.6	1.0-2.1	0.25-0.6	35-67	80-100
PATIENT		217	0.54	1.7	0.64	60	92
FELINE CARDIAC PARAMETERS	LA/AO (Boon)	LA/AO HEART BASE (Sisson)	LA 2D 4-chamber long axis AS to FW (Sisson) (cm)		LVOT VEL. (m/s)	RVOT VEL. (m/s)	IVRT (m/)
NORMAL PARAMETER	<1.5	0.88-1.79	0.7-1.7		<1.6	<1.3	40-60
PATIENT	1.6	1.55	2.1		1.1	0.77	NM
Adapted from June Boon, Veterinary Echocardiography, 1998 Sisson D et al. JVIM 1991; 5: 232, Jacobs et al. Am J Vet Res 1985; 46:1705							

**INVOICE**

94781

**DATE**

12/21/21

**ULTRASONOGRAPHIC FINDINGS**

Minor hypertrophic cardiomyopathy.

Left atrium upper limits normal.

**INTERPRETATION OF THE FINDINGS & FURTHER RECOMMENDATIONS**

No therapy is recommended at this time. There is no overt contraindication to anesthetic procedure. Torbutrol premed, Propofol induction, and Isoflurane maintenance is recommended.



**PATIENT**

JR Ferro

**SPECIES**

Feline

**BREED**

Domestic Shorthair

**SEX**

Neutered male

**AGE**

11 years

**INTERPRETED BY**

Eric Lindquist, DMV  
DABVP, Cert. IVUSS

**IMAGING PERFORMED BY**

Eric Lindquist, DMV  
DABVP, Cert. IVUSS

**HOSPITAL NAME**

HoHoKus VH

**REFERRING VET**

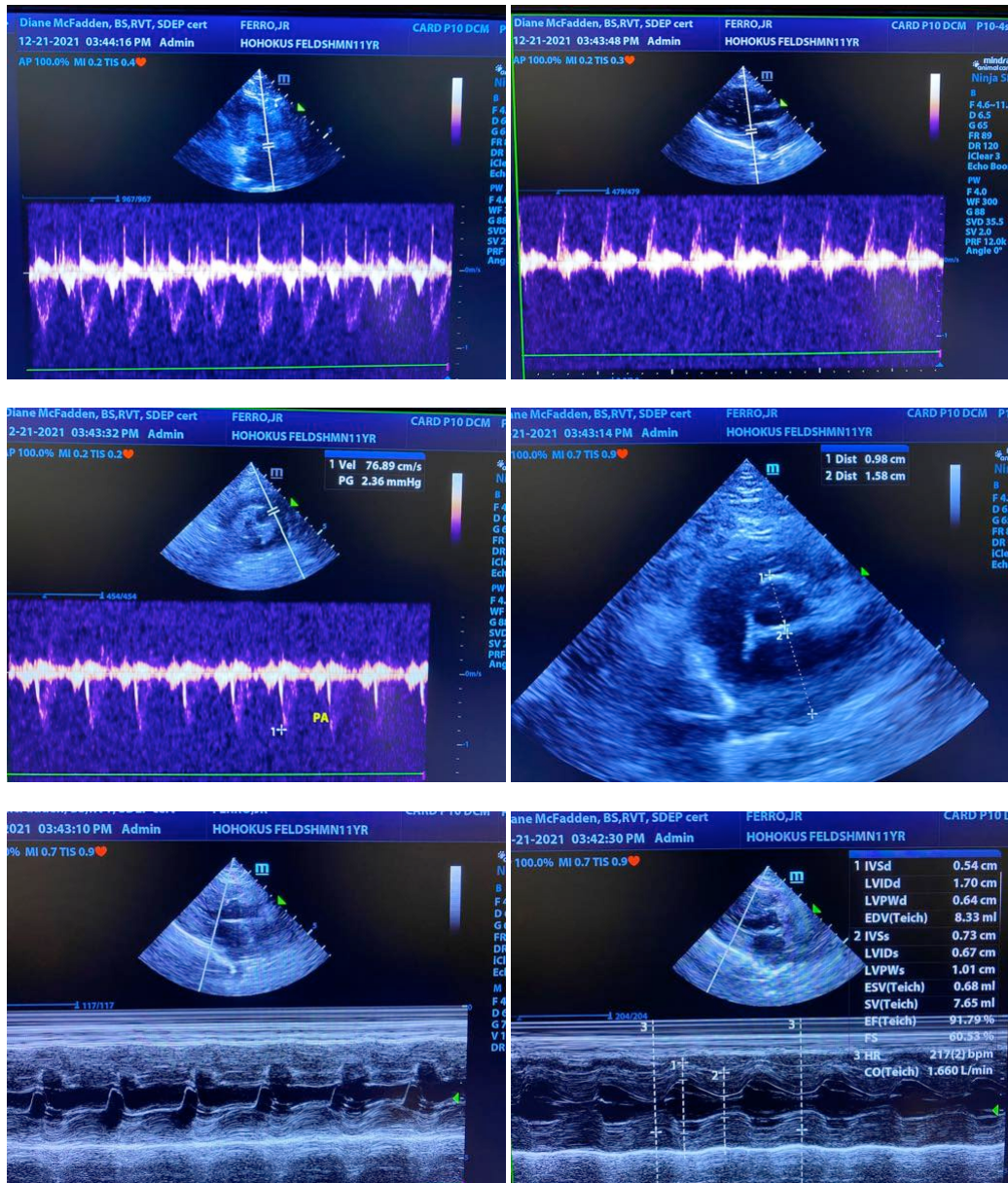
Dr. Scott

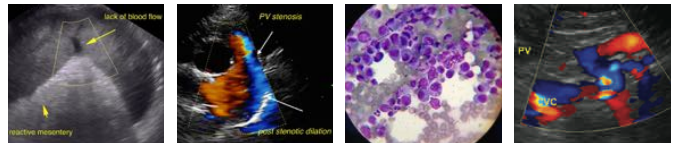
**INVOICE**

94781

**DATE**

12/21/21





**PATIENT**

JR Ferro

**SPECIES**

Feline

**BREED**

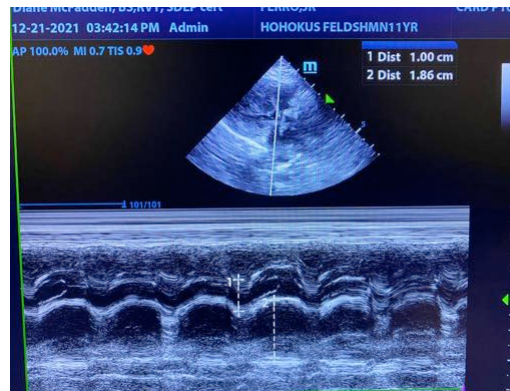
Domestic Shorthair

**SEX**

Neutered male

**AGE**

11 years



The information and recommendations provided are based on the images presented by the referring veterinarian. No evaluation can be communicated regarding pathology that was not visible in the image/video clips provided.

Thank you for this referral. If the clinical or image interpretation does not parallel your findings or if I can be of any further assistance please contact me.

**INTERPRETED BY**

Eric Lindquist, DMV  
DABVP, Cert. IVUSS

Eric Lindquist, DMV, DABVP, Cert. IVUSS, CEO of SonoPath.com  
Info@SonoPath.com

**IMAGING PERFORMED BY**

Eric Lindquist, DMV  
DABVP, Cert. IVUSS

**HOSPITAL NAME**

HoHoKus VH

**REFERRING VET**

Dr. Scott

**INVOICE**

94781

**DATE**

12/21/21