

**PATIENT**

Rosie Sirotek

**SPECIES**

Canine

**BREED**

Rhodesian Ridgeback

**SEX**

Spayed Female

**AGE**

1 Year 5 Month

**WEIGHT**

50 Pounds

**INTERPRETED BY**

Eric Lindquist, DMV,  
DABVP, Cert. IVUSS

**HOSPITAL NAME**

Riverbrook AC

**REFERRING VET**

Dr. Browning

**INVOICE NUMBER**

20222

**DATE**

12/20/22

**PRESENTING CLINICAL SIGNS**

History: Emesis, Diarrhea, fever 103.9 (dropped after IV fluids)  
Abnormal PE/Chem/CBC/UA Results: Sodium 141 - L CL-103 I ALP-346 H

**ULTRASONOGRAPHIC EXAMINATION OF THE ABDOMEN**

**Urinary System**

The **urinary bladder**, trigone, and pelvic urethra presented normal thicknesses and normal tone. The ureters were not visible which is normal. No uroliths or sediment were visualized and anechoic urine was present. No evidence of inflammatory or neoplastic changes were noted. Ureteral papillae were normal.

The **kidneys** revealed normal size and structure, corticomedullary definition and ratio for this age. The cortices presented largely uniform texture with normal echogenic relationship to liver and spleen. Medullary structure differed distinctly from the cortex and no evidence of pelvic dilation was present. The capsules were acceptably uniform without significant irregularities. The left kidney measured 6.11 cm. The right kidney measured 6.11 cm.

**Adrenal Glands**

Both **adrenal glands** were visualized and recognized as having normal shape, size, position and echogenicity for this breed. The phrenic vasculature, glandular echogenicity and detail were unremarkable. Capsule, cortex, and medullary definition were normal for this age patient. The left adrenal gland measured 2.5 cm x 0.63 cm at the caudal pole and 0.46 cm at the cranial pole. The right adrenal gland measured 2.72 cm x 0.69 cm at the caudal pole and 0.87 cm at the cranial pole.

**Spleen**

The **spleen** was mildly enlarged, this is likely a reactive state given the patient history. Caudal folding of the spleen was noted.

**Liver**

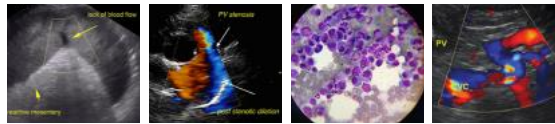
The **liver** images submitted revealed subjectively normal liver size, contour, and structure. Parenchymal echogenicity was naturally coarse and hypoechoic to the spleen. Vascular and biliary tracts were of normal volume with no evidence of congestion. The gallbladder presented acceptably thin walls with primarily anechoic content. The cystic and common bile ducts were normal. No pathological hepatic lymphadenopathy was evident. No overt structural evidence of inflammatory, infiltrative or regenerative pathology was evident.

**Gastrointestinal**

Examination of the **gastrointestinal tract** revealed a stomach and intestine free of stasis, of normal wall thickness, acceptable curvilinear mural detail, and peristaltic activity. Small and large intestine demonstrated normal luminal chyme and stool consistency respectively. No obstructive or overt infiltrative disease was noted. No associated abnormal lymphatic activity was noted.

**Pancreas**

The **pancreas** was mildly hypoechoic to surrounding fat, this may be a normal variant or related to low-grade inflammation, yet the changes were minor.



**PATIENT**

Rosie Sirotek

**SPECIES**

Canine

**BREED**

Rhodesian Ridgeback

**SEX**

Spayed Female

**AGE**

1 Year 5 Month

**WEIGHT**

50 Pounds

**INTERPRETED BY**

Eric Lindquist, DMV,  
DABVP, Cert. IVUS

**HOSPITAL NAME**

Riverbrook AC

**REFERRING VET**

Dr. Browning

**INVOICE NUMBER**

20222

**DATE**

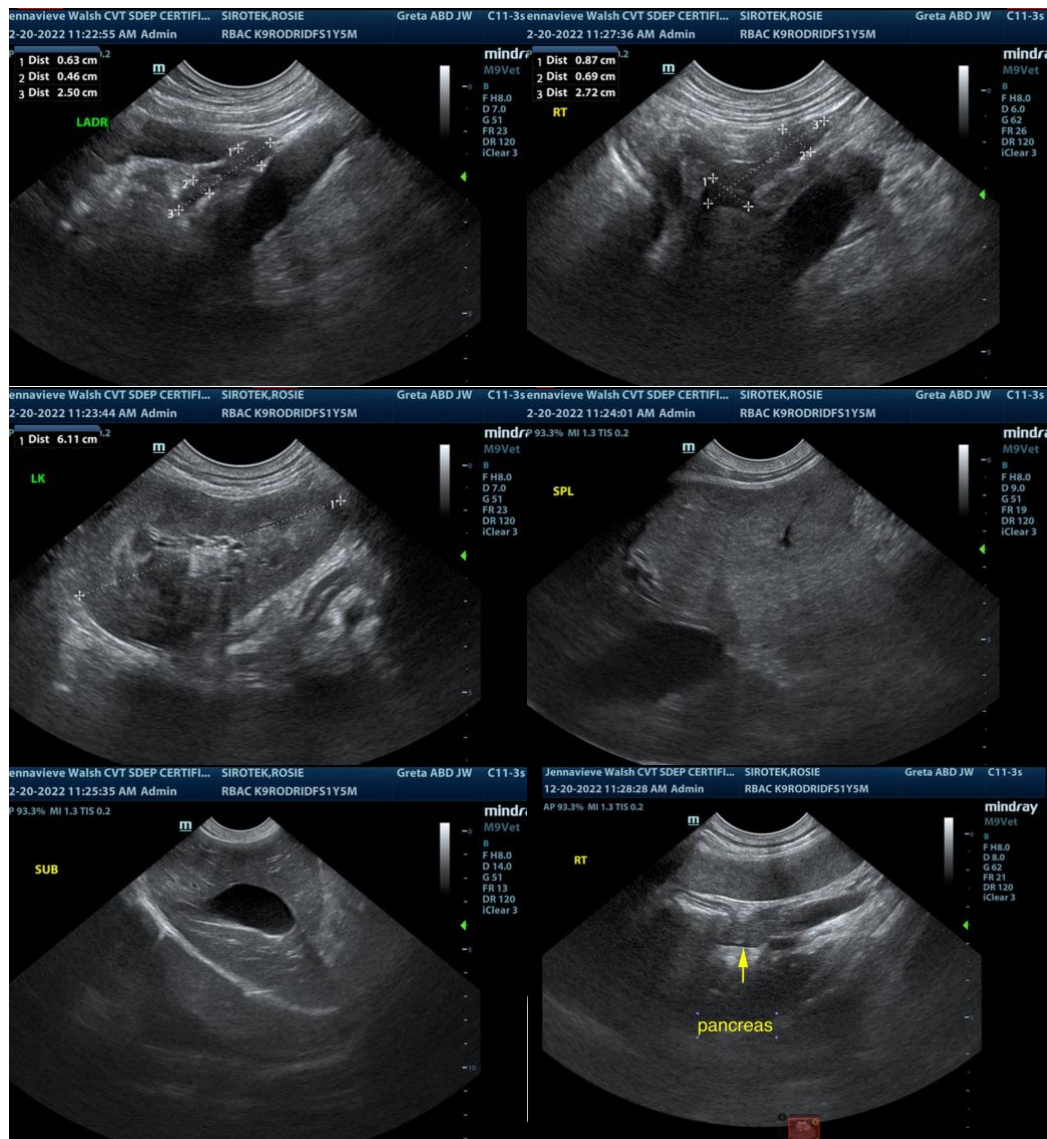
12/20/22

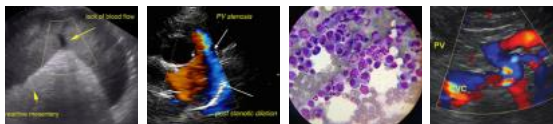
**ULTRASONOGRAPHIC FINDINGS**

- Reactive spleen
- Unremarkable gastrointestinal tract
- Prominent pancreas
- Nonspecific abdominal presentation

**INTERPRETATION OF THE FINDINGS & FURTHER RECOMMENDATIONS**

Supportive care should prove effective. Enterotoxin or occult parasitism is suspected. No evidence of obstructive disease.





**PATIENT** The information and recommendations provided are based on the images presented by the referring veterinarian. No evaluation can be communicated regarding pathology that was not visible in the image/video clips provided.

Rosie Sirotek

**SPECIES** Thank you for this referral. If the clinical or image interpretation does not parallel your findings or if I can be of any further assistance please contact me.

Canine

**Eric Lindquist**, DMV, DABVP, Cert. IVUSS, CEO of SonoPath.com  
[Eric.Lindquist@SonoPath.com](mailto:Eric.Lindquist@SonoPath.com)

**BREED**

Rhodesian Ridgeback

**SEX**

Spayed Female

**AGE**

1 Year 5 Month

**WEIGHT**

50 Pounds

**INTERPRETED BY**

Eric Lindquist, DMV,  
DABVP, Cert. IVUSS

**HOSPITAL NAME**

Riverbrook AC

**REFERRING VET**

Dr. Browning

**INVOICE NUMBER**

20222

**DATE**

12/20/22