



## PATIENT

Ricky Trochez

## SPECIES

Canine

## BREED

Poodle Mix

## SEX

Neutered Male

## AGE

15 Years

## WEIGHT

27.3 Pounds

## INTERPRETED BY

Eric Lindquist, DMV  
DABVP, Cert. IVUSS

## IMAGING PERFORMED BY

Jessica Miller

## HOSPITAL NAME

Newton VH

## REFERRING VET

Dr. Varhalen

## INVOICE

20219

## DATE

12/20/22

## PRESENTING CLINICAL SIGNS

History: Seizure vs syncopal episode, pericardial effusion + possible mass noted near R atrium. ~120mL blood aspirated. No current meds.

Abnormal PE/Chem/CBC/UA Results: Neut 15, ALT 186

## ULTRASONOGRAPHIC EXAMINATION OF THE HEART

CANINE CARDIAC PARAMETERS	MR VMAX (m/s)	TR VMAX (m/s)	LA/AO (Boon method)	LA/AO (Heart Base; Swe)	FS (%)	EF (%)	EPSS (cm)
NORMAL PARAMETER	4.5-5.5	<2.7	1.3	<1.3	28-40	40-100	<0.6
PATIENT	6.07	2.5	1.23	1.22	46	79	0.1
CANINE CARDIAC PARAMETERS	HR (BPM)	AV VMAX (m/s)	PV MAX (m/s)	BODY WEIGHT (kg)	LA 2D short axis Base view (cm)	LVIDd Avg; 2D and m-mode short axis (cm)	LVIDs Avg; 2D and m-mode short axis (cm)
NORMAL PARAMETER	50-100	0.7-1.7	0.7-1.6				
PATIENT	119	1.30	.87	--	3.14	3.13	--

## Cardiac Presentation

The echocardiogram in this patient demonstrated normal **left atrial** size based on 3 different LA measurement methods. Complete filling of the left atrium was noted on color flow assessment. Minor prolapse of the anterior mitral valve leaflet was noted. Doppler indicated measurable insufficiency. The **left ventricle** presented thicknesses with linear contour and was not dilated nor restricted. The **myocardium** presented normal echogenicity without subjective evidence of significant fibrotic or ischemic disease. **Contractility** of the ventricular walls was adequate and in normal range for this patient evidenced by the fractional shortening measurement and subjective evaluation of the different regions of the myocardium. The **left ventricular outflow** tract demonstrated normal laminar flow and subjective structural integrity. The **right atrium** and auricle revealed normal size, structure and content. No evidence of masses was noted or chamber overload. **Tricuspid** insufficiency was noted. The **right ventricle** was of normal size (1/3 diameter of LV), chordae structure, myocardial echogenicity and thickness. **Pulmonic** tract assessment revealed normal valve structure, laminar flow, and diameter (approx.1:1 pa/ao ratio). No visible **pericardial** or free pleura fluid was noted. No echographically detectable evidence of infiltrative disease was visible. The cranial **mediastinum and pericardial regions** were free of masses in the visible window.

## ULTRASONOGRAPHIC FINDINGS

- Stage B-1 valvular disease

## INTERPRETATION OF THE FINDINGS & FURTHER RECOMMENDATIONS



**PATIENT**

Ricky Trochez

No evidence of volume overload. No therapy is recommended at this time, unless blood pressure measurements are >160 systolic. There is no evidence of pericardial effusion at this time and no evidence of masses. Given the patient history, idiopathic pericardial effusion is likely. Abdominal sonogram is warranted to assess for comorbidities.

**SPECIES**

Canine

**BREED**

Poodle Mix

**SEX**

Neutered Male

**AGE**

15 Years

**WEIGHT**

27.3 Pounds

**INTERPRETED BY**

Eric Lindquist, DMV  
DABVP, Cert. IVUSS

**IMAGING PERFORMED BY**

Jessica Miller

**HOSPITAL NAME**

Newton VH

**REFERRING VET**

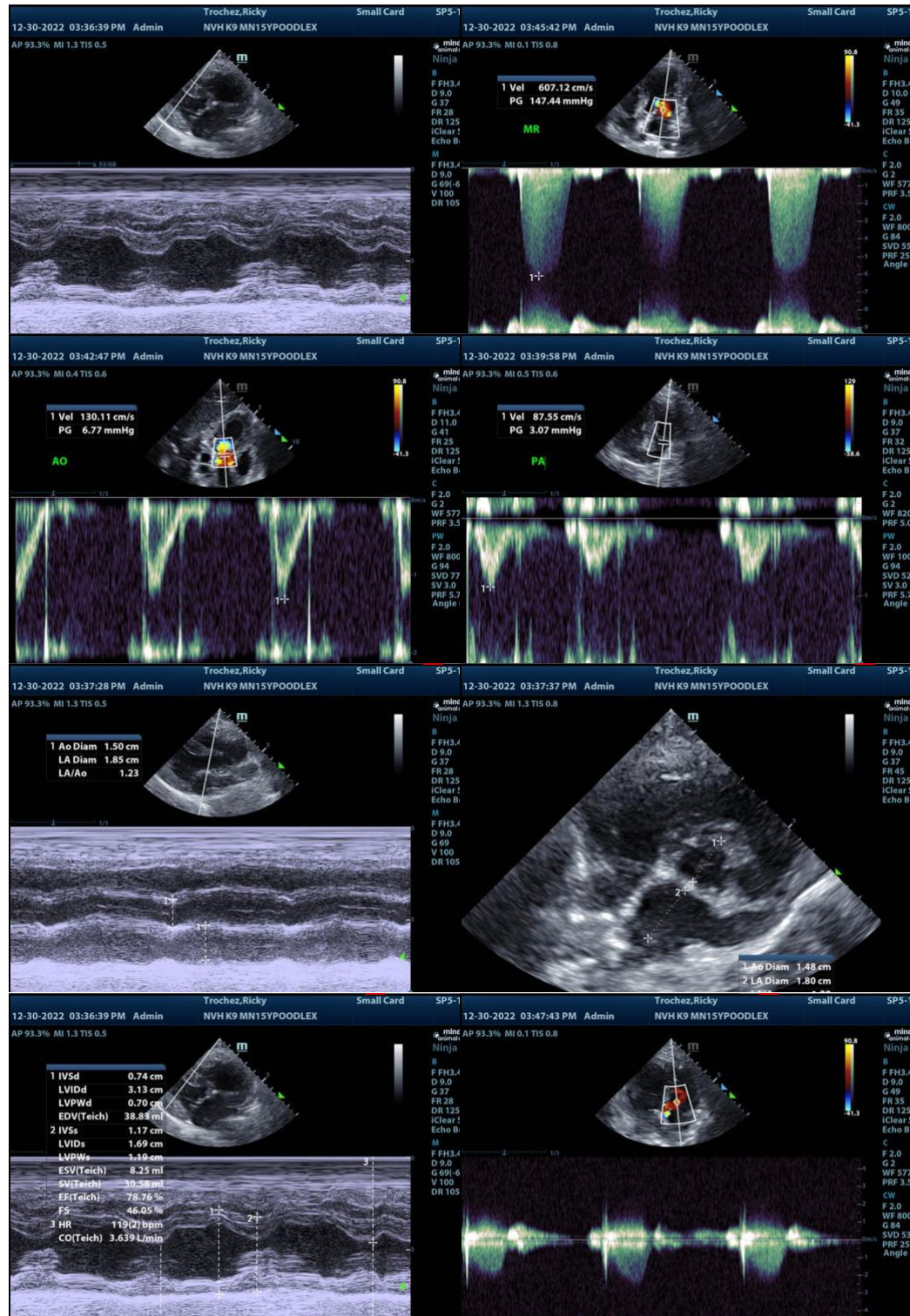
Dr. Varhalen

**INVOICE**

20219

**DATE**

12/20/22





**PATIENT**

Ricky Trochez

**SPECIES**

Canine

**BREED**

Poodle Mix

**SEX**

Neutered Male

**AGE**

15 Years

**WEIGHT**

27.3 Pounds

**INTERPRETED BY**

Eric Lindquist, DMV  
DABVP, Cert. IVUSS

**IMAGING PERFORMED BY**

Jessica Miller

**HOSPITAL NAME**

Newton VH

**REFERRING VET**

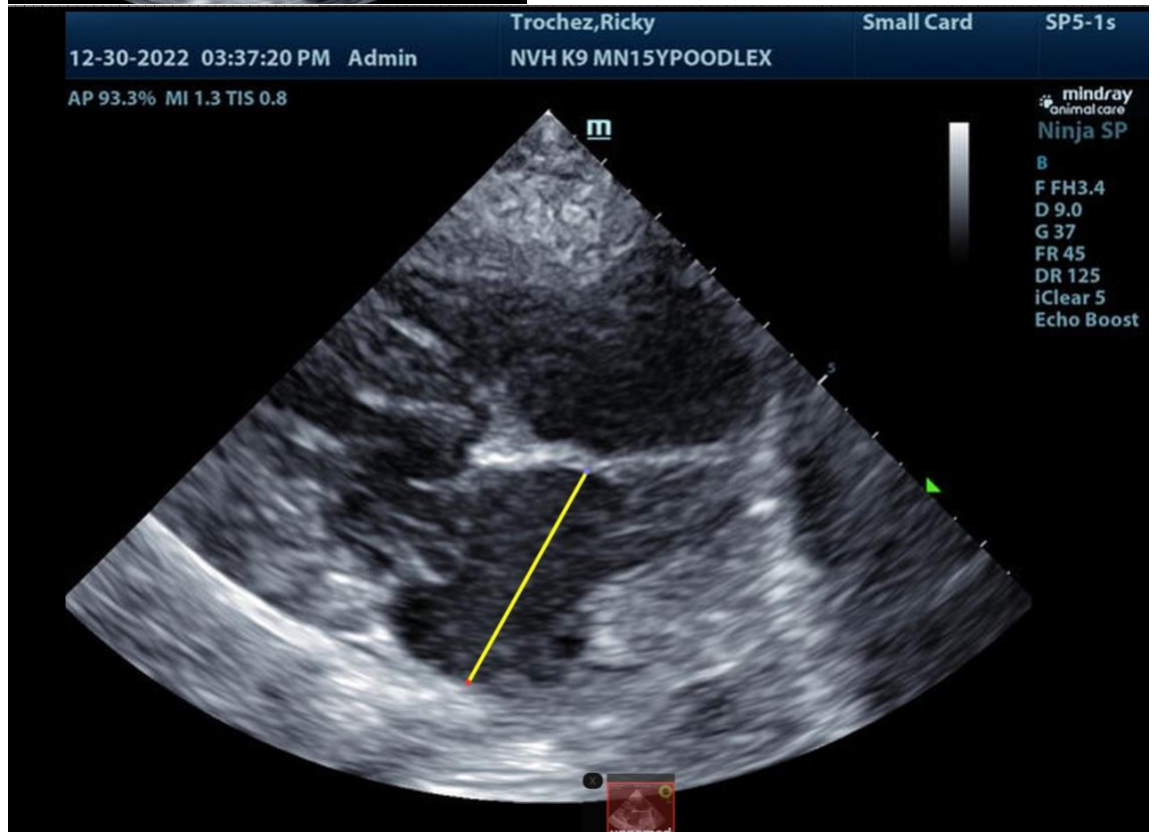
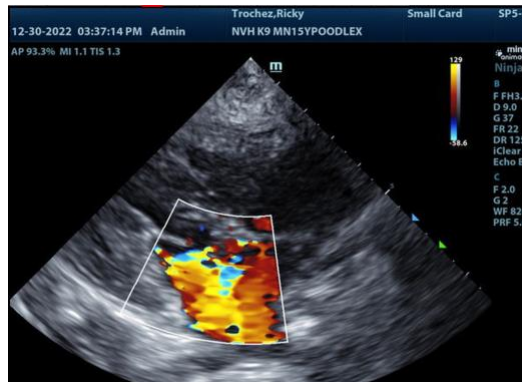
Dr. Varhalen

**INVOICE**

20219

**DATE**

12/20/22





**PATIENT**

Ricky Trochez

**SPECIES**

Canine

**BREED**

Poodle Mix

**SEX**

Neutered Male

**AGE**

15 Years

**WEIGHT**

27.3 Pounds

**INTERPRETED BY**

Eric Lindquist, DMV  
DABVP, Cert. IVUSS

**IMAGING PERFORMED BY**

Jessica Miller

**HOSPITAL NAME**

Newton VH

**REFERRING VET**

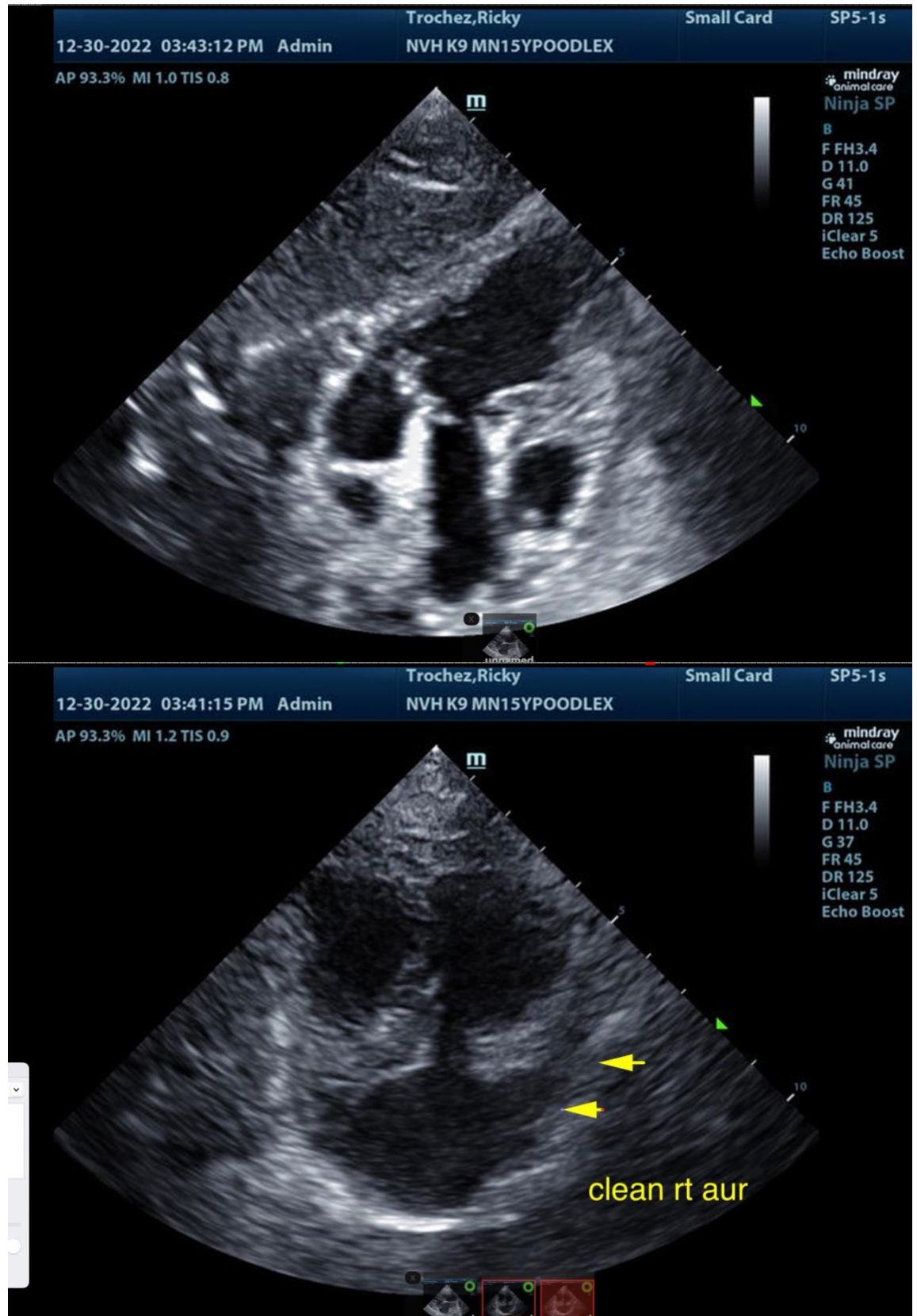
Dr. Varhalen

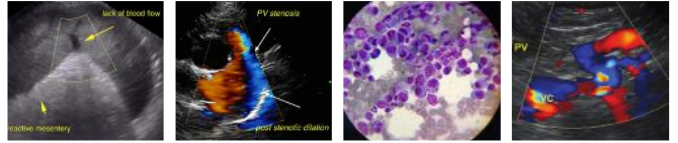
**INVOICE**

20219

**DATE**

12/20/22





**PATIENT**

Ricky Trochez

**SPECIES**

Canine

**BREED**

Poodle Mix

**SEX**

Neutered Male

**AGE**

15 Years

**WEIGHT**

27.3 Pounds

**INTERPRETED BY**

Eric Lindquist, DMV  
DABVP, Cert. IVUSS

**IMAGING  
PERFORMED BY**

Jessica Miller

**HOSPITAL NAME**

Newton VH

**REFERRING VET**

Dr. Varhalen

**INVOICE**

20219

**DATE**

12/20/22

**The information and recommendations provided are based on the images presented by the referring veterinarian. No evaluation can be communicated regarding pathology that was not visible in the image/video clips provided.**

Thank you for this referral. If the clinical or image interpretation does not parallel your findings or if I can be of any further assistance please contact me.

**Eric Lindquist**, DMV, DABVP, Cert. IVUSS, CEO of SonoPath.com  
info@SonoPath.com