



PATIENT

Oz Di Pietro

SPECIES

Feline

BREED

DLH

SEX

Neutered Male

AGE

9 Years

WEIGHT

10 Pounds

PRESENTING CLINICAL SIGNS

History: Chronic unresponsive increased RR/RE. R/O cardiac as cause for resp signs

Abnormal PE/Chem/CBC/UA Results: N/A

ULTRASONOGRAPHIC EXAMINATION OF THE HEART

FELINE CARDIAC PARAMETERS	BODY WEIGHT (kg)	HR (BPM)	IVSd (cm)	LVIDd (cm)	LVWd (cm)	FS (%)	EF (%)
NORMAL PARAMETER	-----	150-240	0.3-0.6	1.0-2.1	0.25-0.6	35-67	80-100
PATIENT	--	NM	0.43	1.92	0.56	69	96
FELINE CARDIAC PARAMETERS	LA/AO (Boon)	LA/AO HEART BASE (Sisson)	LA 2D 4-chamber long axis AS to FW (Sisson) (cm)	LVOT VEL. (m/s)	RVOT VEL. (m/s)	IVRT (m/)	
NORMAL PARAMETER	<1.5	0.88-1.79	0.7-1.7	<1.6	<1.3	40-60	
PATIENT	1.1	1.2	1.22	--	1.30	NM	
Adapted from June Boon, Veterinary Echocardiography, 1998							
Sisson D et al. JVIM 1991; 5: 232, Jacobs et al. Am J Vet Res 1985; 46:1705							

INTERPRETED BY

Eric Lindquist, DMV
DABVP, Cert. IVUSS

IMAGING PERFORMED BY

Rodriguez

HOSPITAL NAME

Foxfield VS

REFERRING VET

Rodriguez

INVOICE

20225

DATE

12/20/22

Cardiac Presentation

The echocardiogram in this patient demonstrated normal **left atrial** size based on 3 separate LA measurements. The cranial and caudal **mitral** valve leaflets presented normal linear structure and kinetics. The **left ventricle** presented normal thicknesses with linear contour and was not dilated nor restricted. The **myocardium** presented normal echogenicity without subjective evidence of significant fibrotic or ischemic disease. **Contractility** of the ventricular walls was adequate and in normal range for this patient evidenced by the fractional shortening measurement and subjective evaluation of the different regions and angles of the myocardium. The **left ventricular outflow** tract demonstrated normal laminar flow and subjective structural integrity. The **right atrium** and auricle revealed normal size, structure and content. No evidence of masses was noted or chamber overload. **Tricuspid** valvular assessment demonstrated adequate linear morphology and kinetics. The **right ventricle** was of normal size (1/3 diameter of LV), chordae structure, myocardial echogenicity and thickness. **Pulmonic** tract assessment revealed normal valve structure, laminar flow, and diameter (approx. 1:1 pa/ao ratio). Excessive respiratory interference was noted in some views.

ULTRASONOGRAPHIC FINDINGS

- Essentially normal echocardiogram
- Excessive respiratory interference

INTERPRETATION OF THE FINDINGS & FURTHER RECOMMENDATIONS

No evidence of structural or functional cardiac disease. Primary respiratory issues are likely the



PATIENT

underlying cause in this patient.

Oz Di Pietro

SPECIES

Feline

BREED

DLH

SEX

Neutered Male

AGE

9 Years

WEIGHT

10 Pounds

INTERPRETED BY

Eric Lindquist, DMV
DABVP, Cert. IVUSS

IMAGING PERFORMED BY

Rodriguez

HOSPITAL NAME

Foxfield VS

REFERRING VET

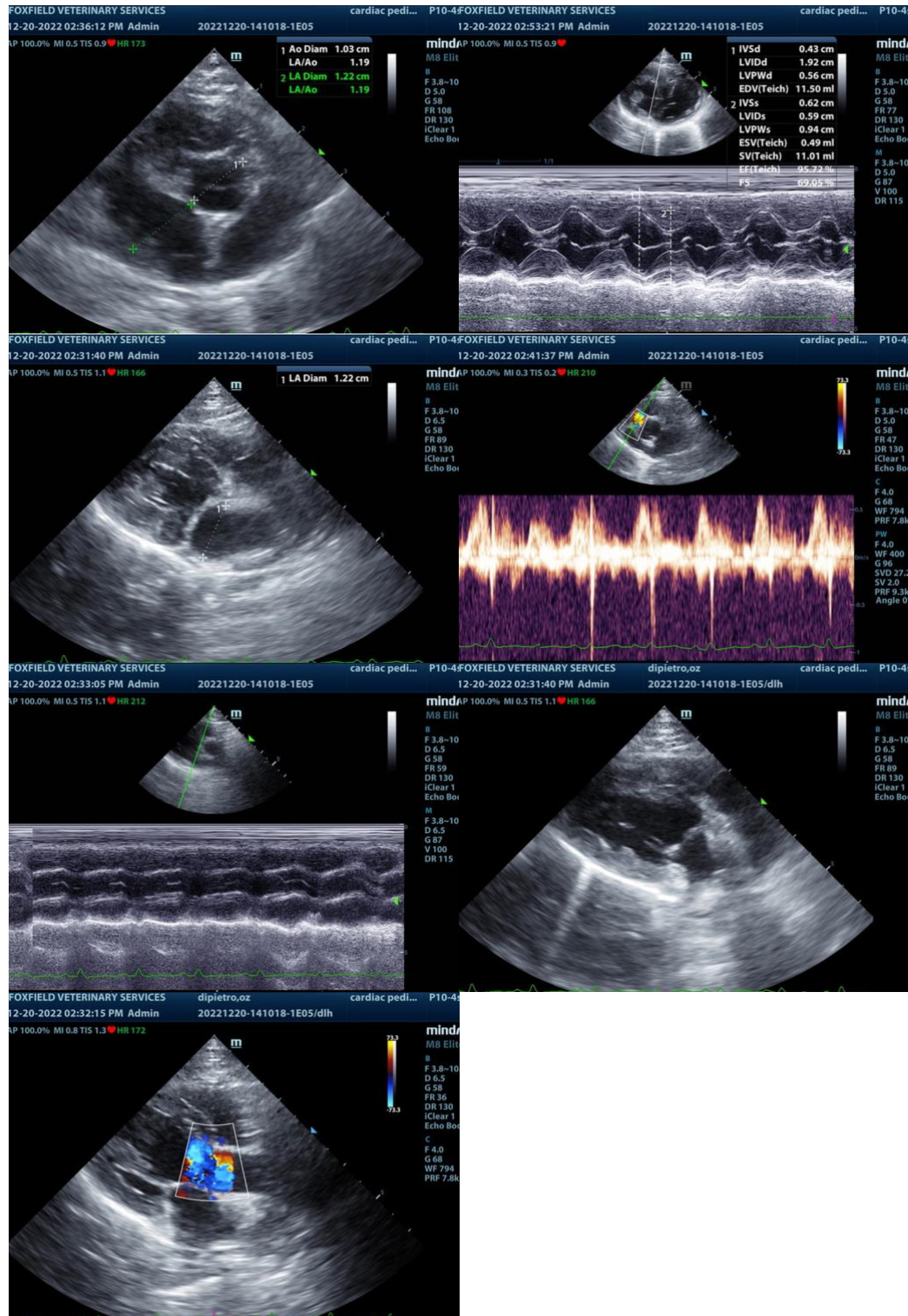
Rodriguez

INVOICE

20225

DATE

12/20/22



The information and recommendations provided are based on the images presented by the



PATIENT

Oz Dipietro

referring veterinarian. No evaluation can be communicated regarding pathology that was not visible in the image/video clips provided.

Thank you for this referral. If the clinical or image interpretation does not parallel your findings or if I can be of any further assistance please contact me.

SPECIES

Feline

Eric Lindquist, DMV, DABVP, Cert. IVUSS, CEO of SonoPath.com

info@SonoPath.com

BREED

DLH

SEX

Neutered Male

AGE

9 Years

WEIGHT

10 Pounds

INTERPRETED BY

Eric Lindquist, DMV
DABVP, Cert. IVUSS

**IMAGING
PERFORMED BY**

Rodriguez

HOSPITAL NAME

Foxfield VS

REFERRING VET

Rodriguez

INVOICE

20225

DATE

12/20/22