



PATIENT

Charlie Pierce

PRESENTING CLINICAL SIGNS

History: Recheck case from yesterday. Patient has been fasting for the last 24 hours. Concerns for a potential foreign body.

SPECIES

Canine

ULTRASONOGRAPHIC EXAMINATION

Gastrointestinal

BREED

Labradr

The **gastrointestinal tract** revealed gastric stasis with thickened, irregular mucosa particularly in the caudal aspect of the pyloric antrum. Much of the small intestine was empty, yet a persistent midabdominal progressively shadowing luminal structure was present. This was just caudal to the stomach. This cannot be completely differentiated from transverse colon; however, the wall of the associated intestine would be most consistent with small intestine. Reactive mesentery was noted associated with the small intestine as well.

SEX

Neutered male

AGE

9 years

ULTRASONOGRAPHIC FINDINGS

Progressively shadowing luminal structure.

WEIGHT

30 lbs

INTERPRETATION OF THE FINDINGS & FURTHER RECOMMENDATIONS

If the patient is still clinical and has not had a bowel movement and will not survive successfully pass a food challenge, then I recommend exploratory surgery for two reasons. One reason is to evacuate any intestinal material and the second reason is to obtain GI biopsies particularly that of the pyloric antrum. Inspection of the pyloric mucosa is also indicated at the time of surgery. GI biopsies are essential. Underlying disease is suspected with potential of soft shadowing and non-obstructive foreign matter.

INTERPRETED BY

Eric Lindquist, DMV
DABVP, Cert. IVUSS

IMAGING PERFORMED BY

Dr. Gardner

HOSPITAL NAME

Wilvet Salem

REFERRING VET

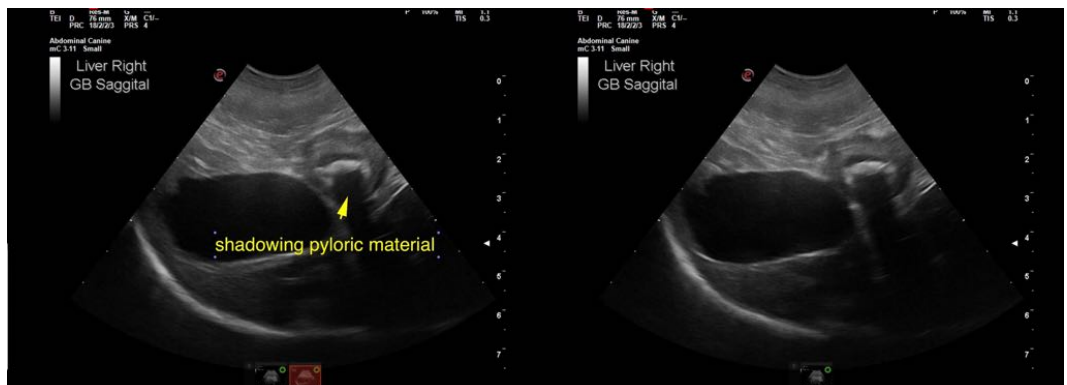
Dr. Gardner

INVOICE

42217

DATE

12/19/22





PATIENT

Charlie Pierce

SPECIES

Canine

BREED

Labraodr

SEX

Neutered male

AGE

9 years

WEIGHT

30 lbs

INTERPRETED BY

Eric Lindquist, DMV
DABVP, Cert. IVUSS

IMAGING PERFORMED BY

Dr. Gardner

HOSPITAL NAME

Wilvet Salem

REFERRING VET

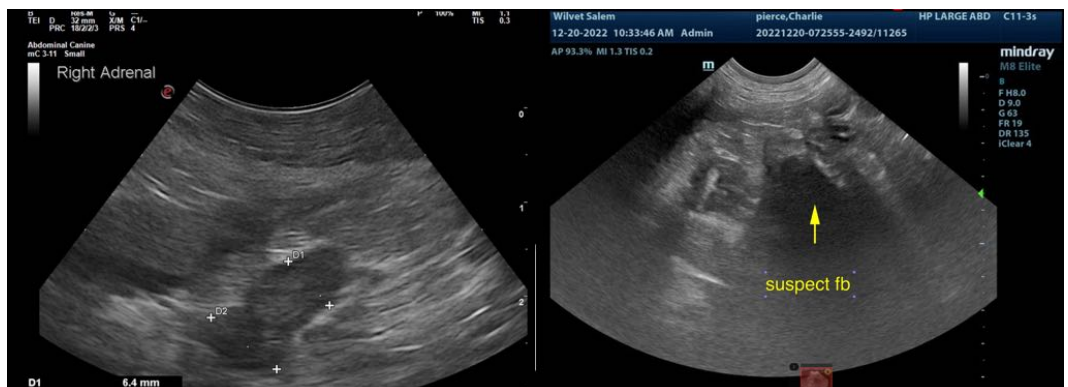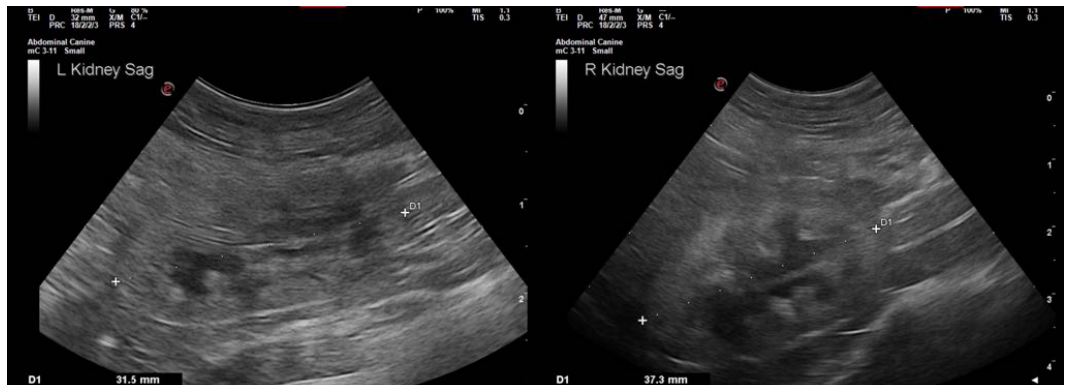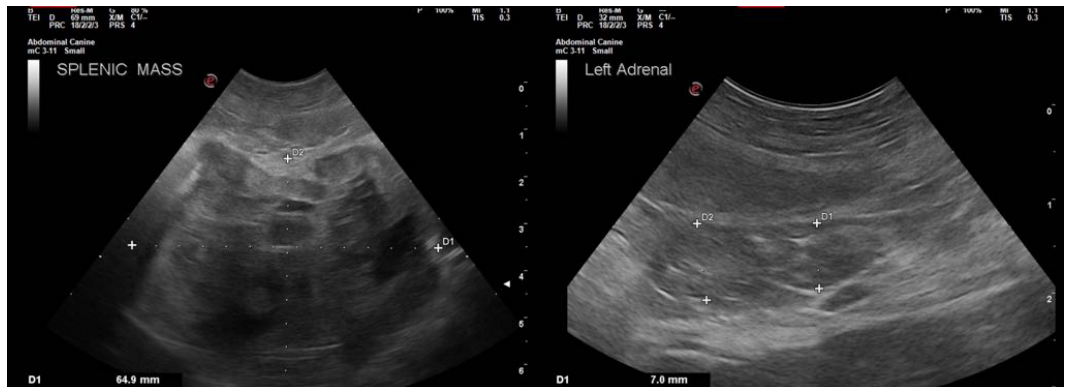
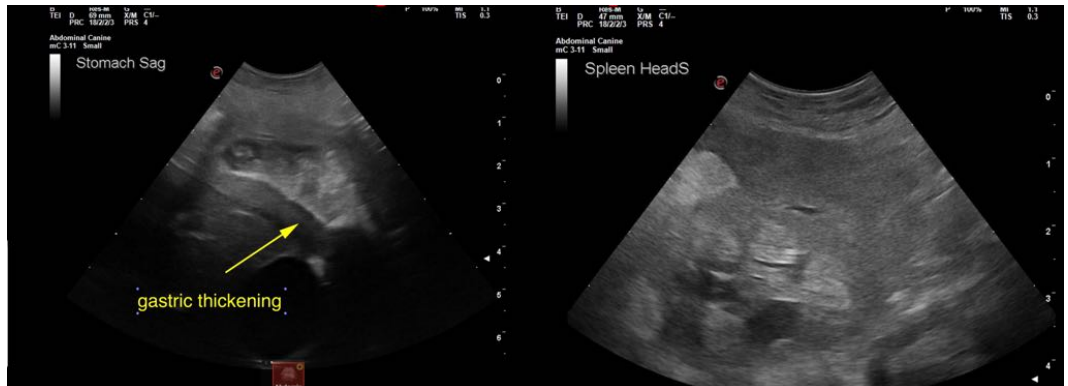Dr. Gardner

INVOICE

42217

DATE

12/19/22





PATIENT

Charlie Pierce

SPECIES

Canine

BREED

Labrador

SEX

Neutered male

AGE

9 years

WEIGHT

30 lbs

INTERPRETED BY

Eric Lindquist, DMV
DABVP, Cert. IVUSS

IMAGING PERFORMED BY

Dr. Gardner

HOSPITAL NAME

Wilvet Salem

REFERRING VET

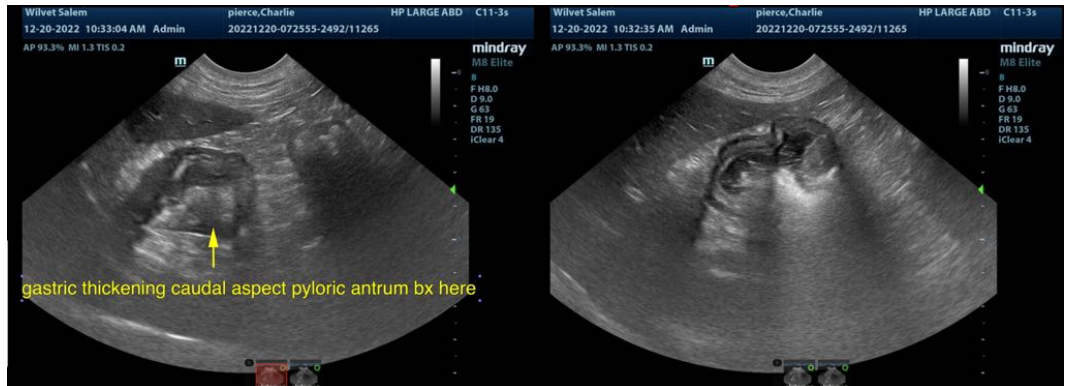Dr. Gardner

INVOICE

42217

DATE

12/19/22



The information and recommendations provided are based on the images presented by the referring veterinarian/sonographer. No evaluation can be communicated regarding pathology that was not visible in the image/video clips provided.

Thank you for this referral. If the clinical or image interpretation does not parallel your findings or if I can be of any further assistance please contact me.

Eric Lindquist, DMV, DABVP, Cert. IVUSS, CEO of SonoPath.com
info@SonoPath.com