



PATIENT

Pretzel Silk

SPECIES

Feline

BREED

DSH

SEX

Neutered Male

AGE

10 Years

WEIGHT

4.4 kg

INTERPRETED BY

Eric Lindquist, DMV
DABVP, Cert. IVUSS

IMAGING PERFORMED BY

Erin Wicks

HOSPITAL NAME

Shores VEC

REFERRING VET

Dr. Miller

INVOICE

33589

DATE

12/20/21

PRESENTING CLINICAL SIGNS

Presented at our hospital for AUS, was seen on an outpatient basis here 12/18... intermediate episode since June where patient will not eat or drink, vomits; weight loss; Becomes very lethargic, hiding not wanting to do much, Gave Zyrtec on the 16th Previous Health Concerns: facial paralysis when he was a kitten, dry eye, dental disease ; most recent blood work and rads- October 2021- nsf according to owner; Current Medications: dry eye lube SID-BID in both eyes, Metronidazole and Pred started 12/18. Abnormal PE/Chem/CBC/UA Results: Icteric Blood work- Lver panel- ALT957(H) ALP 129(H) GGT 20 (H) Bili 5.6(H); normal ProBNP.

ULTRASONOGRAPHIC EXAMINATION OF THE ABDOMEN

Urinary System

The **urinary bladder**, trigone, and pelvic urethra presented normal thicknesses and normal tone. The ureters were not visible which is normal. No uroliths or sediment were visualized and anechoic urine was present. No evidence of inflammatory or neoplastic changes were noted. Ureteral papillae were normal.

The **kidneys** revealed largely normal size and structure, corticomedullary definition and ratio (cortex 1/3 of medulla) were essentially maintained with some age-related loss of curvilinear patterns regarding the capsule and C/M junction. The cortices presented largely uniform texture with some increased echogenicity expected for his age patient. Medullary structure differed distinctly from that of the cortex and no evidence of pelvic dilation was present. The left kidney measured 4.13 cm. The right kidney measured 4.19 cm.

Adrenal Glands

The regions of the **adrenal glands** were unremarkable.

Spleen

The **spleen** presented a smooth homogeneous parenchyma hyperechoic to liver and renal cortical parenchyma. The capsule was smooth without noticeable expansion or deviation from within the spleen or adjacent pathology. The splenic vasculature demonstrated normal volume without signs of congestion or thrombosis. No sonographic evidence of acute or chronic inflammatory, neoplastic, or infarctual changes were noted.

Liver

The **liver** presented coarse architecture and tortuous cystic duct. Mild swollen hepatic contour noted. Post-hepatic obstruction is present as well as hepatic lymphadenopathy. The common bile duct was dilated to 6.0 mm. Lobar biliary dilation also noted owing to post-hepatic obstruction.

Gastrointestinal & Pancreas

The **stomach** itself was unremarkable. The region of the upper duodenum and right pancreatic limb revealed an undifferentiated mass measuring approximately 3.0 cm. The mass appears to be deriving from the gastrointestinal tract.

ULTRASONOGRAPHIC FINDINGS

- Upper gastrointestinal/pancreatic mass with post-hepatic obstruction
- Concurrent cholangiohepatitis



PATIENT

Pretzel Silk

SPECIES

Feline

BREED

DSH

SEX

Neutered Male

AGE

10 Years

WEIGHT

4.4 kg

INTERPRETED BY

Eric Lindquist, DMV
DABVP, Cert. IVUSS

IMAGING PERFORMED BY

Erin Wicks

HOSPITAL NAME

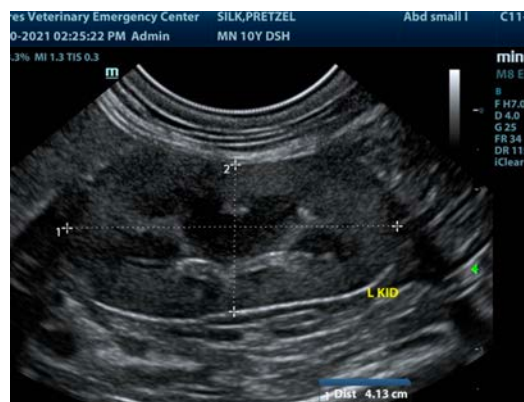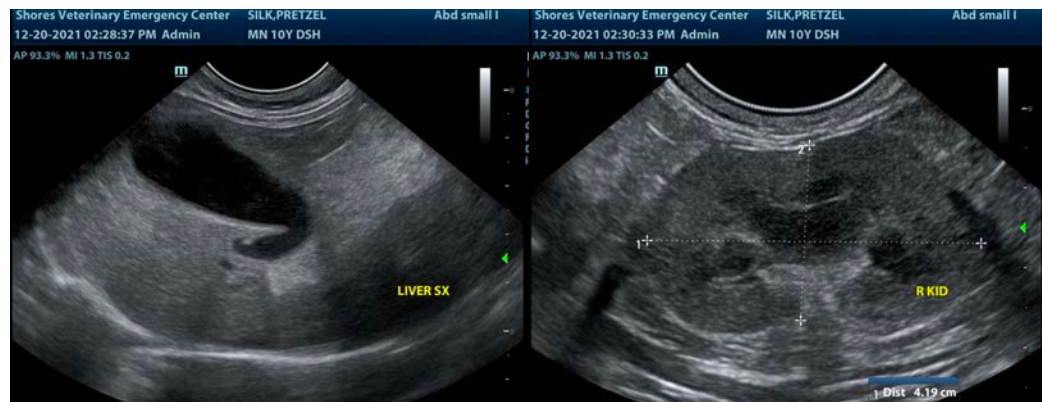
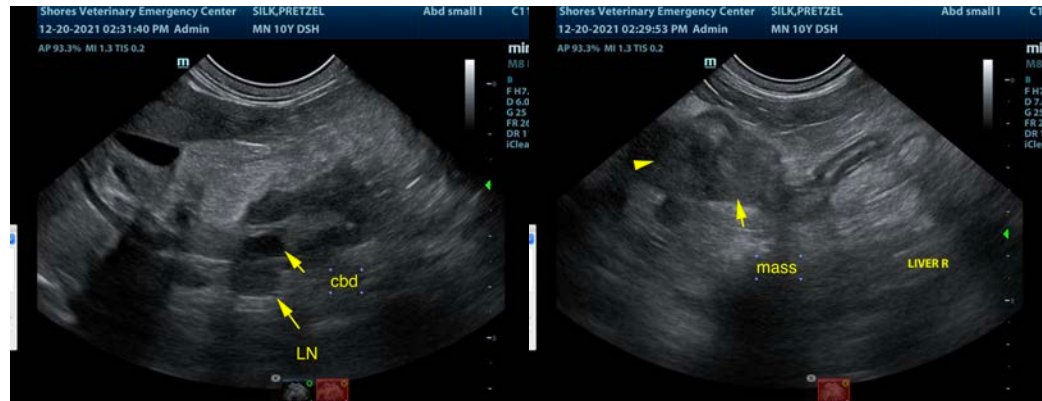
Shores VEC

REFERRING VET

Dr. Miller

INTERPRETATION OF THE FINDINGS & FURTHER RECOMMENDATIONS

Ultrasound guided FNA of the mass and liver could be considered for further definition. However, prognosis is poor. The mass appears to involve the gastroduodenal junction and therefore is not overtly resectable.



INVOICE

33589

DATE

12/20/21

The information and recommendations provided are based on the images presented by the referring veterinarian. No evaluation can be communicated regarding pathology that was not visible in the image/video clips provided.

Thank you for this referral. If the clinical or image interpretation does not parallel your findings or if I can be of any further assistance please contact me.

Eric Lindquist, DMV, DABVP, Cert. IVUSS, CEO of SonoPath.com
info@SonoPath.com