



PATIENT

Pooch Wright

PRESENTING CLINICAL SIGNS

CC PROTEINURIA ABD US DONE TODAY BP=190 CONCERN ABOUT POSSIBLY CARDIOMEGALY ON RADS

SPECIES

Canine

ULTRASONOGRAPHIC EXAMINATION OF THE ABDOMEN

Urinary System

BREED

Yorkie

The **urinary bladder**, trigone, and pelvic urethra presented normal thicknesses and normal tone. The ureters were not visible which is normal. No uroliths or sediment were visualized and anechoic urine was present. No evidence of inflammatory or neoplastic changes was noted. Ureteral papillae were normal.

SEX

Neutered male

The **kidneys** revealed largely normal size and structure, corticomedullary definition and ratio (cortex 1/3 of medulla) were essentially maintained with some age-related loss of curvilinear patterns regarding the capsule and C/M junction. The cortices presented largely uniform texture with some increased echogenicity expected for this age patient. Medullary structure differed distinctly from that of the cortex and no evidence of pelvic dilation was present. The right kidney measured 3.93 cm. The left kidney measured 3.63 cm.

AGE

9 years

WEIGHT

10.7 lbs

Adrenal Glands

The right adrenal gland was slightly enlarged and measured 0.8 cm. The left adrenal gland was slightly enlarged and measured 0.6 cm.

INTERPRETED BY

Eric Lindquist, DMV
DABVP, Cert. IVUSS

Spleen

IMAGING PERFORMED BY

Dr. Barnea

The **spleen** presented a smooth homogeneous parenchyma hyperechoic to liver and renal cortical parenchyma. The capsule was smooth without noticeable expansion or deviation from within the spleen or adjacent pathology. The splenic vasculature demonstrated normal volume without signs of congestion or thrombosis. No sonographic evidence of acute or chronic inflammatory, neoplastic, or infarctual changes was noted.

HOSPITAL NAME

Tenafly

Liver

REFERRING VET

Dr. Barnea

The **liver** images submitted revealed subjectively normal liver size, contour, and structure. Parenchymal echogenicity was naturally coarse and hypoechoic to the spleen. Vascular and biliary tracts were of normal volume with no evidence of congestion. The gallbladder presented acceptably thin walls with primarily anechoic content. The cystic and common bile ducts were normal. No pathological hepatic lymphadenopathy was evident. No overt structural evidence of inflammatory, infiltrative or regenerative pathology was evident.

INVOICE

97456

DATE

12/20/21



PATIENT

Gastrointestinal

Pooch Wright

Examination of the **gastrointestinal tract** revealed a stomach and intestine free of stasis, of normal wall thickness, acceptable curvilinear mural detail, and peristaltic activity. Small and large intestine demonstrated normal luminal chyme and stool consistency respectively. No obstructive or overt infiltrative disease was noted. No associated abnormal lymphatic activity was noted.

SPECIES

Canine

BREED

Yorkie

SEX

Neutered male

Pancreas

The base and limbs of the **pancreas** were observed to be largely isoechoic to surrounding omental fat. Some parenchymal remodeling, however, with mild deviation from curvilinear normalcy was observed. Pancreatic duct and capsular irregularities were present consistent with age related changes. If pain upon imaging (+ Murphy sign) was present or if the patient is focally painful in subxiphoid palpation then low-grade smoldering chronic pancreatitis should be suspected.

AGE

9 years

ULTRASONOGRAPHIC FINDINGS

Mild bilateral adrenal hypertrophy, non-specific age related renal changes.

WEIGHT

10.7 lbs

INTERPRETATION OF THE FINDINGS & FURTHER RECOMMENDATIONS

If the urine specific gravity is less than 1.020 then work-up for PDH is indicated.

INTERPRETED BY

Eric Lindquist, DMV
DABVP, Cert. IVUS

IMAGING PERFORMED BY

Dr. Barnea

HOSPITAL NAME

Tenafly

REFERRING VET

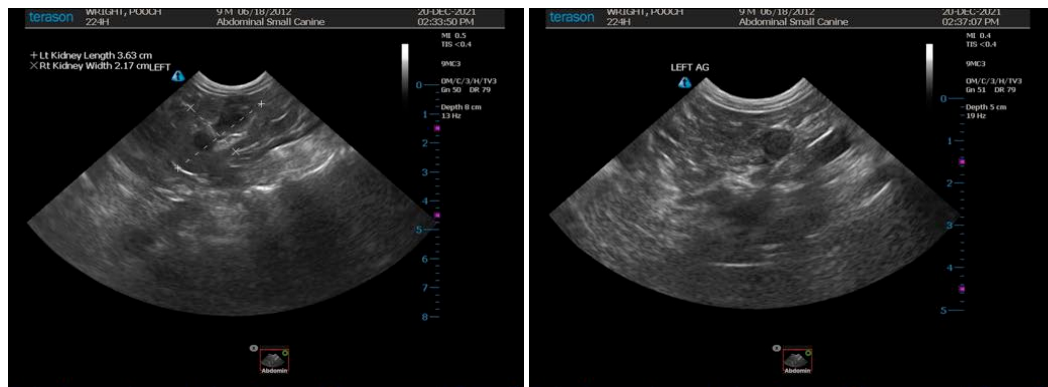
Dr. Barnea

INVOICE

97456

DATE

12/20/21





PATIENT

Pooch Wright

SPECIES

Canine

BREED

Yorkie

SEX

Neutered male

AGE

9 years

WEIGHT

10.7 lbs

INTERPRETED BY

Eric Lindquist, DMV
DABVP, Cert. IVUSS

IMAGING PERFORMED BY

Dr. Barnea

HOSPITAL NAME

Tenafly

REFERRING VET

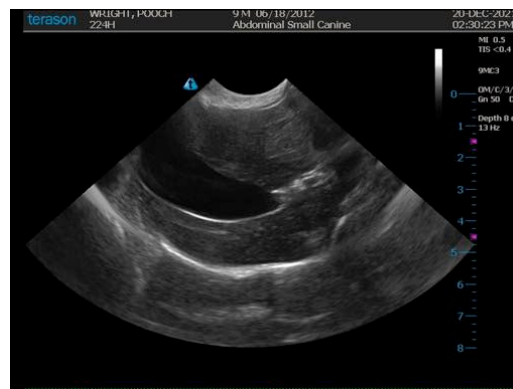
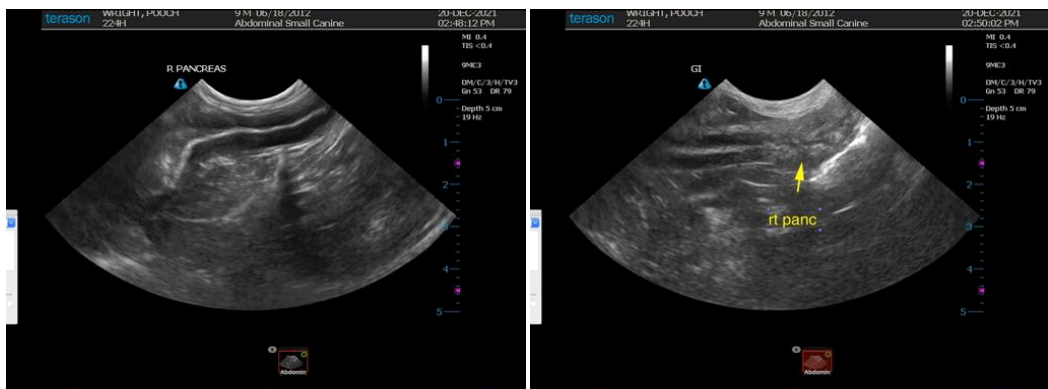
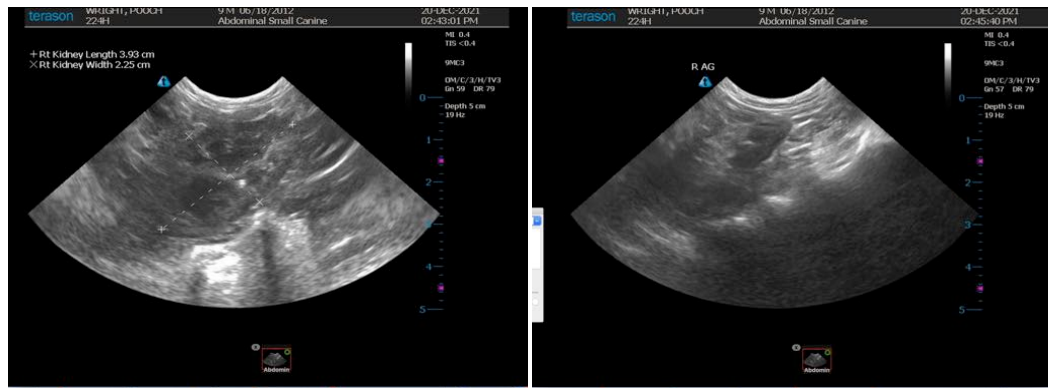Dr. Barnea

INVOICE

97456

DATE

12/20/21



The information and recommendations provided are based on the images presented by the referring veterinarian. No evaluation can be communicated regarding pathology that was not visible in the image/video clips provided.

Thank you for this referral. If the clinical or image interpretation does not parallel your findings or if I can be of any further assistance please contact me.



PATIENT

Eric Lindquist, DMV, DABVP, Cert. IVUSS, CEO of SonoPath.com
info@SonoPath.com

Pooch Wright

SPECIES

Canine

BREED

Yorkie

SEX

Neutered male

AGE

9 years

WEIGHT

10.7 lbs

INTERPRETED BY

Eric Lindquist, DMV
DABVP, Cert. IVUSS

**IMAGING
PERFORMED BY**

Dr. Barnea

HOSPITAL NAME

Tenafly

REFERRING VET

Dr. Barnea

INVOICE

97456

DATE

12/20/21