



**PATIENT**

Peep Bassolino

**PRESENTING CLINICAL SIGNS**

History: Poor appetite for 2 days, lethargic, elevated liver values and high WBC  
Abnormal PE/Chem/CBC/UA Results: Blood ALK PHOS 162, TOTAL BILI 4.5, WBC 26.1

**SPECIES**

Feline

**ULTRASONOGRAPHIC EXAMINATION OF THE ABDOMEN**

**Urinary System**

The **urinary bladder**, trigone, and pelvic urethra presented normal thicknesses and normal tone. The ureters were not visible which is normal. No uroliths or sediment were visualized and anechoic urine was present. No evidence of inflammatory or neoplastic changes was noted. Ureteral papillae were normal.

**BREED**

Domestic Longhair

**SEX**

Spayed Female

**AGE**

7 years

The **kidneys** revealed largely normal size and structure, corticomedullary definition and ratio (cortex 1/3 of medulla) were essentially maintained with some age-related loss of curvilinear patterns regarding the capsule and C/M junction. The cortices presented largely uniform texture with some increased echogenicity expected for this age patient. Medullary structure differed distinctly from that of the cortex and no evidence of pelvic dilatation was present. The left kidney measured 3.6 cm. The right kidney measured 3.82 cm.

**WEIGHT**

8.3 lbs

**Adrenal Glands**

Both **adrenal glands** were visualized and recognized as having normal shape, size, position and echogenicity for this breed. The phrenic vasculature, glandular echogenicity and detail were unremarkable. Capsule, cortex, and medullary definition were normal for this age patient.

**INTERPRETED BY**

Eric Lindquist, DMV  
DABVP, Cert. IVUSS

**Spleen**

The **spleen** was enlarged with scalloping contour. The spleen measured 1.3 cm.

**IMAGING PERFORMED BY**

JK

**Liver**

The **liver** was mildly enlarged and heterogenous. The liver was diffusely hypoechoic to the falciform fat. The gallbladder was essentially collapsed, yet mildly thickened. There was no evidence of post hepatic obstruction.

**HOSPITAL NAME**

Hamburg VC

**REFERRING VET**

Dr. Martens

**Gastrointestinal**

Examination of the **gastrointestinal tract** revealed a stomach and intestine free of stasis, of normal wall thickness, acceptable curvilinear mural detail, and peristaltic activity. Small areas of intestinal thickening was noted in the caudal abdomen with regional, enhanced mesentery.

**INVOICE**

94734

**DATE**

12/20/21



**PATIENT**

**Pancreas**

Peep Bassolino

The base and limbs of the **pancreas** were observed to be largely isoechoic to surrounding omental fat. Pancreatic duct and capsular contour were acceptably normal and parenchyma respected normal curvilinear patterns. No overt evidence of active inflammatory or neoplastic disease was noted.

**SPECIES**

Feline

**ULTRASONOGRAPHIC FINDINGS**

**BREED**

Infiltrative splenohepatic pattern.

Domestic Longhair

**INTERPRETATION OF THE FINDINGS & FURTHER RECOMMENDATIONS**

**SEX**

There is a strong suspicion for round cell neoplasia/lymphoma. FNA of the spleen and liver is recommended for confirmation.

Spayed Female

**AGE**

7 years

**WEIGHT**

8.3 lbs

**INTERPRETED BY**

Eric Lindquist, DMV  
DABVP, Cert. IVUSS

**IMAGING PERFORMED BY**

JK

**HOSPITAL NAME**

Hamburg VC

**REFERRING VET**

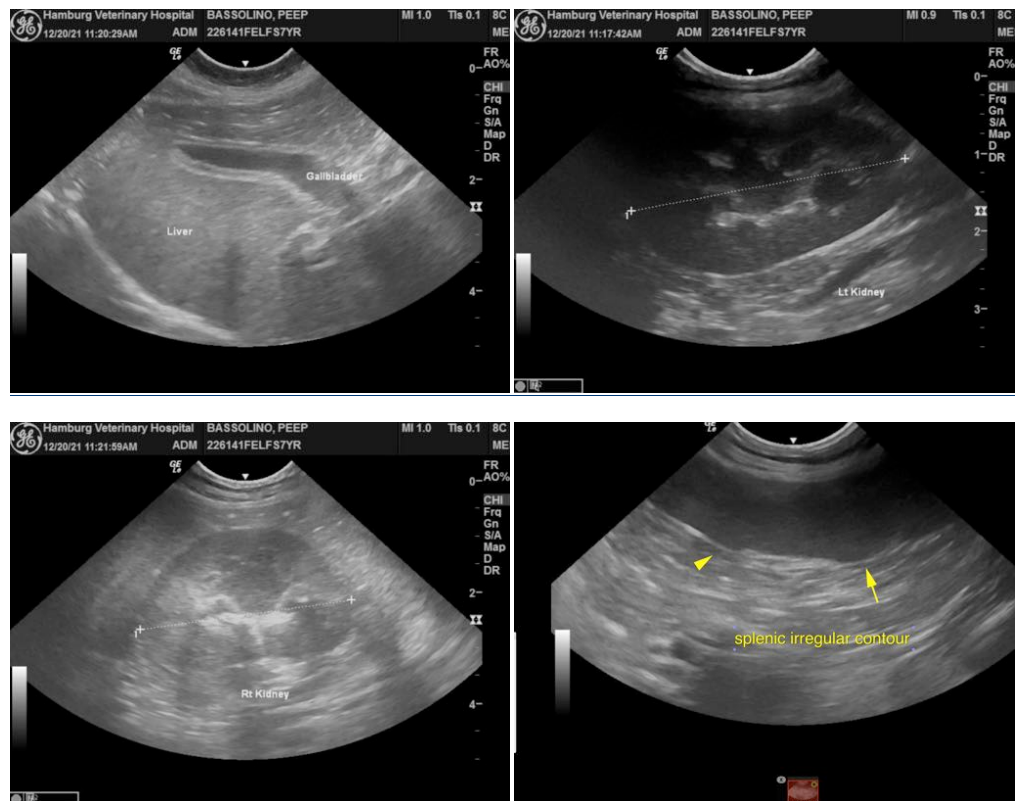
Dr. Martens

**INVOICE**

94734

**DATE**

12/20/21





**PATIENT**

Peep Bassolino

**SPECIES**

Feline

**BREED**

Domestic Longhair

**SEX**

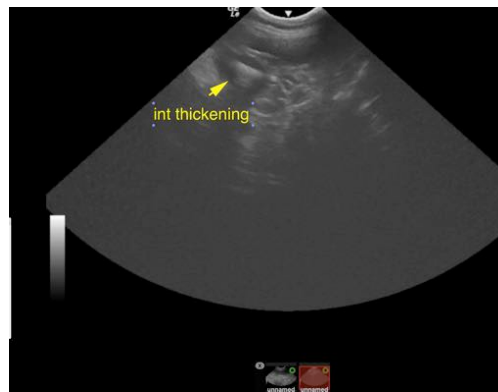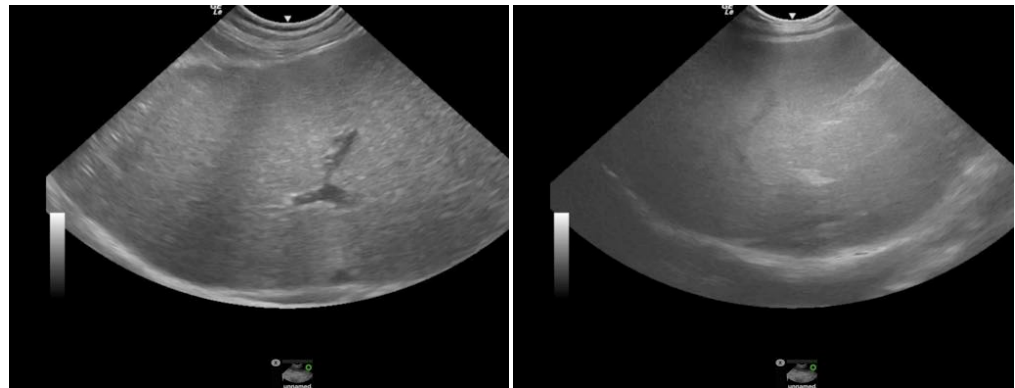
Spayed Female

**AGE**

7 years

**WEIGHT**

8.3 lbs



**INTERPRETED BY**

Eric Lindquist, DMV  
DABVP, Cert. IVUSS

The information and recommendations provided are based on the images presented by the referring veterinarian. No evaluation can be communicated regarding pathology that was not visible in the image/video clips provided.

**IMAGING PERFORMED BY**

JK

Thank you for this referral. If the clinical or image interpretation does not parallel your findings or if I can be of any further assistance please contact me.

**HOSPITAL NAME**

Hamburg VC

**Eric Lindquist, DMV, DABVP, Cert. IVUSS, CEO of SonoPath.com**  
info@SonoPath.com

**REFERRING VET**

Dr. Martens

**INVOICE**

94734

**DATE**

12/20/21