

**DATE**

12/20/21

PRESENTING CLINICAL SIGNS

History: intermittent trouble urinating, palpable mass in abdomen.

Date of Previous IntraPet Ultrasound: 1-18-21.

Sedation: Ace & Torb.

Stat Report: Not requested.

PATIENT

Gunner Gahagan

SPECIES

Canine

BREED

German Shepherd

SEX

Neutered male

AGE

10/27/13

WEIGHT

90 lbs

INTERPRETED BYEric Lindquist, DMV
DABVP, Cert. IVUSS**IMAGING PERFORMED BY**

Rachel Brillhart RDMS

HOSPITAL NAME

Madonna VC

REFERRING VET

Dr. Cangro

INVOICE

94736

ULTRASONOGRAPHIC EXAMINATION OF THE ABDOMEN**Urinary System**

The **urinary bladder**, trigone, and pelvic urethra presented normal thicknesses and normal tone. The ureters were not visible which is normal. A trace amount of sand was noted. No evidence of inflammatory or neoplastic changes was noted. Ureteral papillae were normal.

The **kidneys** revealed normal size and structure, corticomedullary definition and ratio for this age. The cortices presented largely uniform texture with normal echogenic relationship to liver and spleen. Medullary structure differed distinctly from the cortex and no evidence of pelvic dilation was present. The capsules were acceptably uniform without significant irregularities. The left kidney was hypoechoic with an irregular nodule that measured 1.74 cm and an overt 4.33 x 3.84 cm mass that was deriving from the dorsal cortex. The left kidney measured 6.24 cm. The right kidney measured 6.73 cm.

Adrenal Glands

Both **adrenal glands** were visualized and recognized as having normal shape, size, position and echogenicity for this breed. The phrenic vasculature, glandular echogenicity and detail were unremarkable. Capsule, cortex, and medullary definition were normal for this age patient. The left adrenal gland measured 3.09 x 0.74 cm at the cranial pole and 0.74 cm at the caudal pole. The right adrenal gland measured 2.47 cm at the caudal pole and 0.85 cm at the cranial pole.

Spleen

The **spleen** in this patient revealed an expansive, nodular parenchymal mass that measured 10+ cm. A separate splenic mass measured 3.95 cm. Portions of the splenic pathology appear to involve the pancreas.

Liver

The **liver** was mildly heterogenous with coarse architecture, particularly in the right liver. This may be related to a micrometastatic event. There were no overt masses noted. The gallbladder presented acceptably thin walls with primarily anechoic content. The cystic and common bile ducts were normal.

Gastrointestinal

Examination of the **gastrointestinal tract** revealed a stomach and intestine free of stasis, of normal wall thickness, acceptable curvilinear mural detail, and peristaltic activity. Small and large intestine demonstrated normal luminal chyme and stool consistency respectively. No obstructive or overt infiltrative disease was noted. No associated abnormal lymphatic activity was noted.

Pancreas

Much of the **pancreas** was obscured owing to the splenic mass. However, the right pancreatic limb was unremarkable.

Heart

Rapid view of the heart revealed no evidence of pathology.

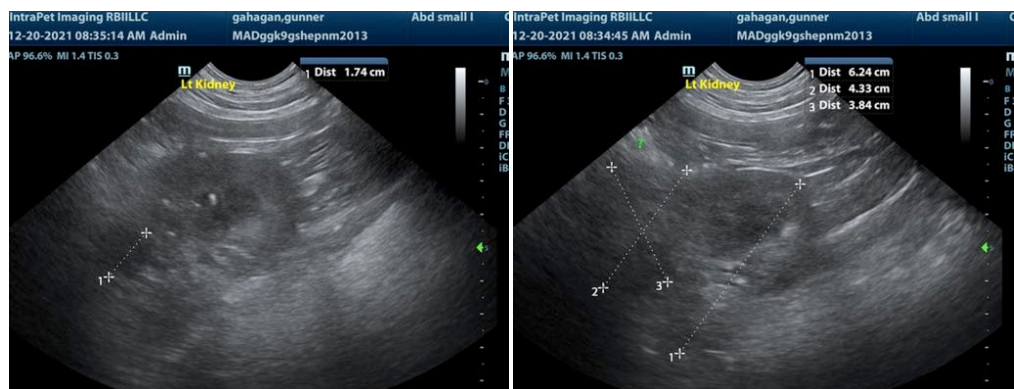
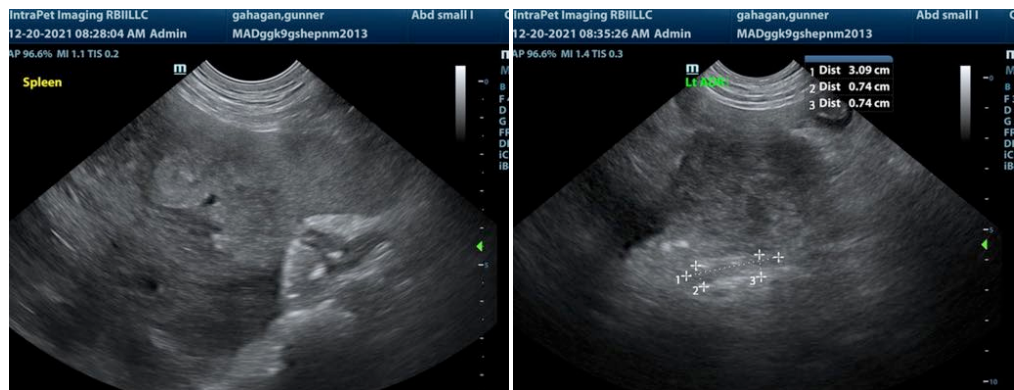
ULTRASONOGRAPHIC FINDINGS

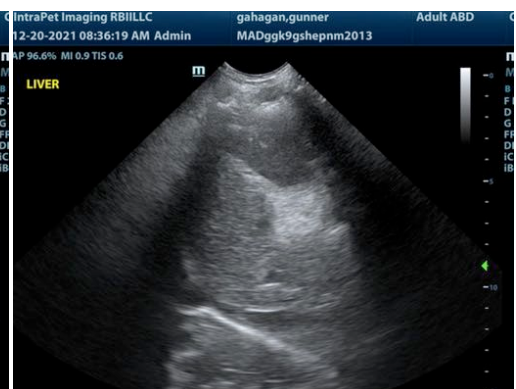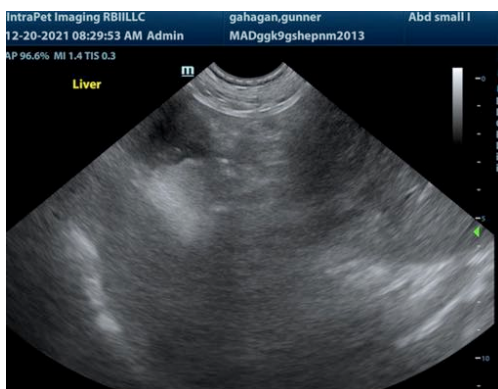
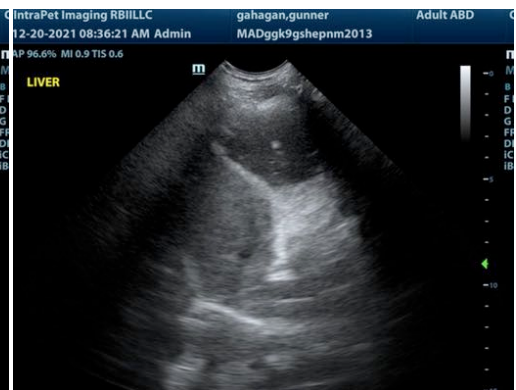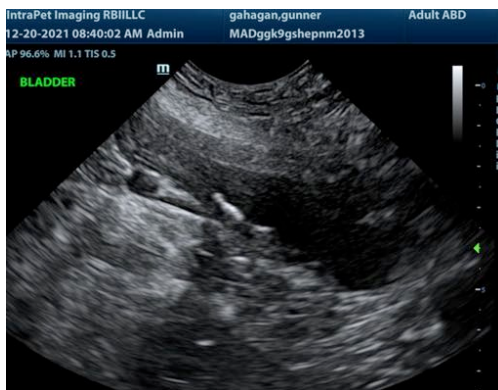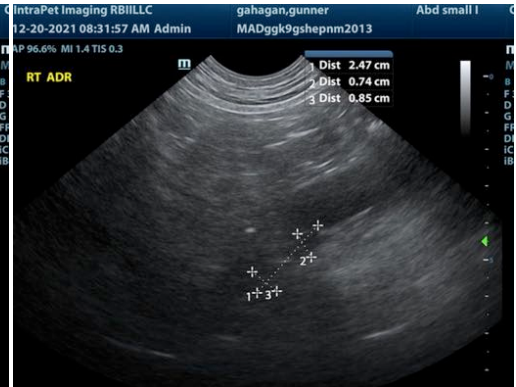
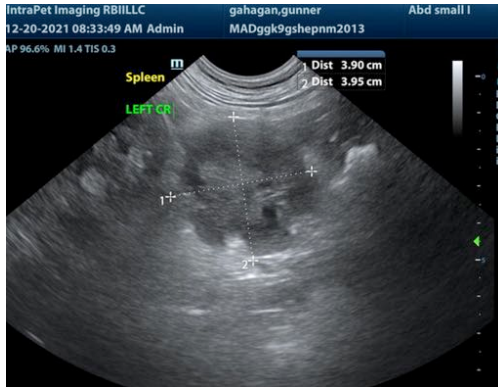Splenic and renal masses.
Bladder sand.

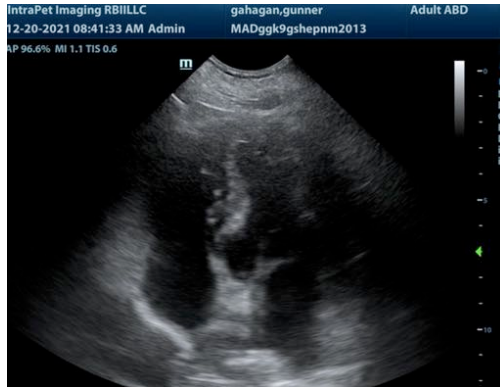INTERPRETATION OF THE FINDINGS & FURTHER RECOMMENDATIONS

FNA of the pathology is recommended with immediate chemotherapeutic intervention. This is not a surgical presentation. The splenic masses extend into the regional omentum. FNA screening of the liver is warranted as well as the spleen and kidney. Multi-centric sarcoma or similar neoplasia is suspected.

**The mass made it difficult to completely visualize the abdomen.







The information and recommendations provided are based on the images presented by the referring veterinarian. No evaluation can be communicated regarding pathology that was not visible in the image/video clips provided.

Thank you for this referral. If the clinical or image interpretation does not parallel your findings or if I can be of any further assistance please contact me.

Eric Lindquist, DMV, DABVP, Cert. IVUSS, CEO of SonoPath.com
Eric.Lindquist@SonoPath.com