



PATIENT

Edward Gerardi

PRESENTING CLINICAL SIGNS

History: weight loss, appetite and behavior normal
CBC/Chem/T4 unremarkable, amylase was 3301, had dental 11/17/2021

SPECIES

Feline

ULTRASONOGRAPHIC EXAMINATION OF THE ABDOMEN

Urinary System

BREED

Ragdoll Mix

The **urinary bladder**, trigone, and pelvic urethra presented normal thicknesses and normal tone. The ureters were not visible which is normal. No uroliths or sediment were visualized and anechoic urine was present. No evidence of inflammatory or neoplastic changes was noted. Ureteral papillae were normal.

SEX

Neutered male

The **kidneys** presented a relatively uniform cortical hyperechogenicity when compared to the renal medulla, spleen and liver. No overt masses were noted. Corticomedullary definition was nebulous and the ratio favored the cortex slightly. The ureters were not visible and assumed to be normal. These changes are most consistent with chronic interstitial nephritis yet infiltrative disease could not be entirely ruled out without biopsy though neoplasia is not suspected. The left kidney measured 3.0 cm. Blood flow to the kidneys appeared adequate. The right kidney measured 3.0 cm.

AGE

14 years

WEIGHT

7 lbs

Adrenal Glands

Both **adrenal glands** were visualized and recognized as having normal shape, size, position and echogenicity for this breed. The phrenic vasculature, glandular echogenicity and detail were unremarkable. Capsule, cortex, and medullary definition were normal for this age patient.

INTERPRETED BY

Eric Lindquist, DMV
DABVP, Cert. IVUSS

Spleen

The **spleen** in this patient was uniform, yet volume contracted. Hydration status should be assessed.

IMAGING PERFORMED BY

Linda Grau

Liver

HOSPITAL NAME

Fredon AH

The **liver** images submitted revealed subjectively normal liver size, contour, and structure. Parenchymal echogenicity was naturally coarse and hypoechoic to the spleen. Vascular and biliary tracts were of normal volume with no evidence of congestion. The gallbladder presented acceptably thin walls with primarily anechoic content. The cystic and common bile ducts were normal. No pathological hepatic lymphadenopathy was evident. No overt structural evidence of inflammatory, infiltrative or regenerative pathology was evident.

REFERRING VET

Dr. Roche

INVOICE

94735

Gastrointestinal

Examination of the **gastrointestinal tract** revealed a stomach and intestine free of stasis, of normal wall thickness, acceptable curvilinear mural detail, and peristaltic activity. Small and large intestine demonstrated normal luminal chyme and stool consistency respectively. No obstructive or overt infiltrative disease was noted. No associated abnormal lymphatic activity was noted.

DATE

12/20/21



PATIENT

Pancreas

Edward Gerardi

The base and limbs of the **pancreas** were observed to be largely isoechoic to surrounding omental fat. Pancreatic duct and capsular contour were acceptably normal and parenchyma respected normal curvilinear patterns. No overt evidence of active inflammatory or neoplastic disease was noted.

SPECIES

Feline

ULTRASONOGRAPHIC FINDINGS

BREED

Largely geriatric abdomen.

Ragdoll Mix

SEX

Neutered male

INTERPRETATION OF THE FINDINGS & FURTHER RECOMMENDATIONS

There is no evidence of significant disease. Maldigestion panel, three view chest radiographs and full CNS examination is recommended to examine for occult disease that could be responsible for the weight loss. Evaluation for competitive eating environments should also be considered. The changes are expected for this age patient.

AGE

14 years

WEIGHT

7 lbs

INTERPRETED BY

Eric Lindquist, DMV
DABVP, Cert. IVUSS

IMAGING PERFORMED BY

Linda Grau

HOSPITAL NAME

Fredon AH

REFERRING VET

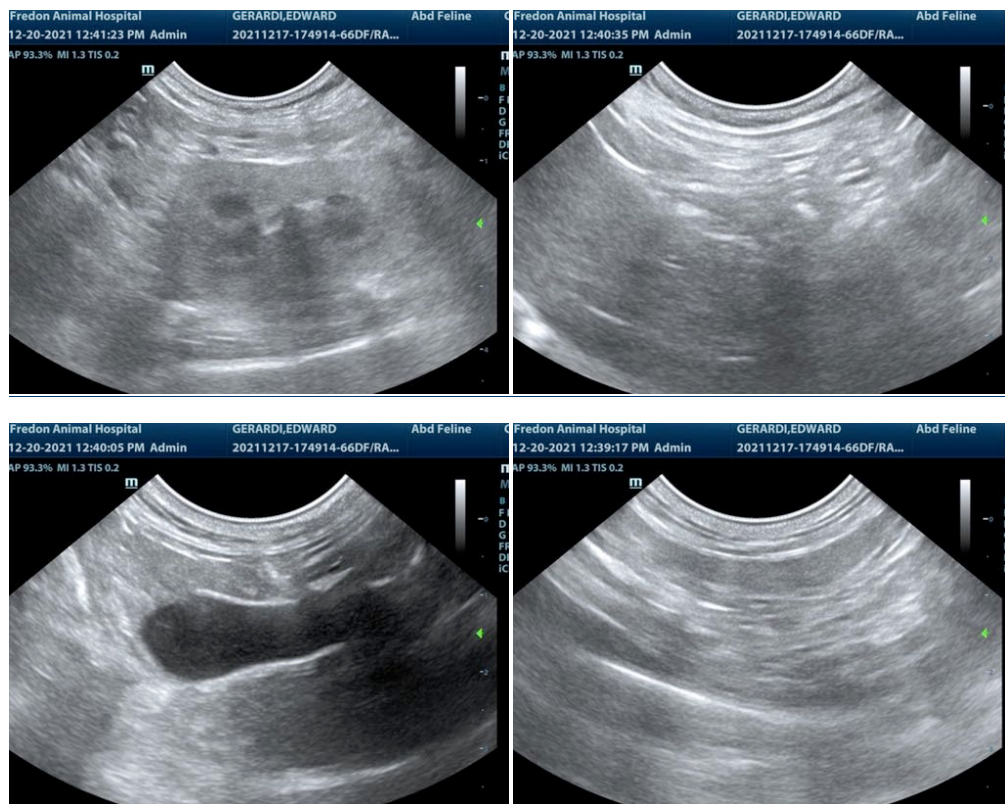
Dr. Roche

INVOICE

94735

DATE

12/20/21





PATIENT

Edward Gerardi

SPECIES

Feline

BREED

Ragdoll Mix

SEX

Neutered male

AGE

14 years

WEIGHT

7 lbs

INTERPRETED BY

Eric Lindquist, DMV
DABVP, Cert. IVUSS

IMAGING PERFORMED BY

Linda Grau

HOSPITAL NAME

Fredon AH

REFERRING VET

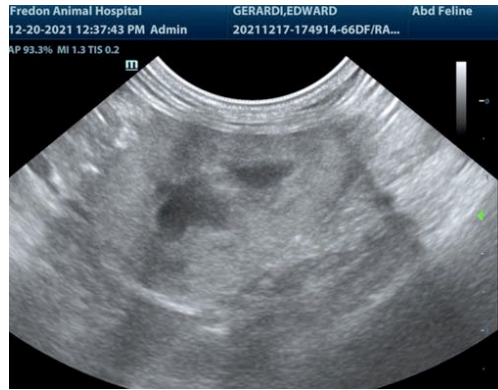Dr. Roche

INVOICE

94735

DATE

12/20/21



The information and recommendations provided are based on the images presented by the referring veterinarian. No evaluation can be communicated regarding pathology that was not visible in the image/video clips provided.

Thank you for this referral. If the clinical or image interpretation does not parallel your findings or if I can be of any further assistance please contact me.

Eric Lindquist, DMV, DABVP, Cert. IVUSS, CEO of SonoPath.com
info@SonoPath.com