



## PATIENT

Ginger Badrick

## SPECIES

Canine

## BREED

Golden Retriever/Toy  
Poodle

## SEX

Spayed female

## AGE

8 years

## WEIGHT

35 lbs

## INTERPRETED BY

Eric Lindquist, DMV  
DABVP, Cert. IVUSS

## IMAGING PERFORMED BY

Jeremiah Gabriel

## HOSPITAL NAME

Central Jersey AH

## REFERRING VET

Dr. Gabriel

## INVOICE

69249

## DATE

12/2/25

## PRESENTING CLINICAL SIGNS

History: high liver enzymes during routine previous blood work was normal owner is worried about sudden increase in liver enzymes doing clinically well no v/d/c/s eating well  
Abnormal PE/Chem/CBC/UA Results: ALT (SGPT) 243 ALK PHOS 132

## ULTRASONOGRAPHIC EXAMINATION OF THE ABDOMEN

### Urinary System

The **urinary bladder**, trigone, and pelvic urethra presented normal thicknesses and normal tone. The ureters were not visible which is normal. No uroliths or sediment were visualized and anechoic urine was present. No evidence of inflammatory or neoplastic changes was noted. Ureteral papillae were normal.

The **kidneys** revealed normal size and structure, corticomedullary definition and ratio for this age. The cortices presented largely uniform texture with normal echogenic relationship to liver and spleen. Medullary structure differed distinctly from the cortex and no evidence of pelvic dilation was present. The capsules were acceptably uniform without significant irregularities. The left kidney measured 5.0 cm. The right kidney measured 5.7 cm.

### Adrenal Glands

The **left adrenal gland** was visualized and recognized as having normal shape, size, position and echogenicity for this breed. The phrenic vasculature, glandular echogenicity and detail were unremarkable. Capsule, cortex, and medullary definition were normal for this age patient. The left adrenal gland measured 0.6 cm. The right adrenal gland was not visualized.

### Spleen

The **spleen** presented a smooth homogeneous parenchyma hyperechoic to liver and renal cortical parenchyma. The capsule was smooth without noticeable expansion or deviation from within the spleen or adjacent pathology. The splenic vasculature demonstrated normal volume without signs of congestion or thrombosis. No sonographic evidence of acute or chronic inflammatory, neoplastic, or infarctual changes was noted.

### Liver

The **liver** images from right and left intercostal as well as subcostal views revealed subjectively normal liver size, contour, and structure. Some age-related parenchymal remodeling was noted but likely not clinically significant at this time. Vascular and biliary tracts were of normal volume and no evidence of congestion was noted. The gallbladder presented some dependent debris with essentially normal contour. The cystic and common bile ducts were normal. No overt evidence of active inflammatory, infiltrative or regenerative pathology was noted but should be paired with current or past LE elevations regarding any clinical significance to this presentation. The hepatic lymph nodes were unremarkable.



**PATIENT**

**Gastrointestinal**

Ginger Badrick

There was some residual chyme and gas was noted in the **stomach**, yet not pathological. This is consistent with post prandial presentation. Transit of chyme into the small intestine was normal. Curvilinear patterns were maintained throughout the GI tract. No evidence of pathology. Small and large intestine demonstrated normal luminal chyme and stool consistency respectively. No obstructive or overt infiltrative disease was noted. No associated abnormal lymphatic activity was noted.

**SPECIES**

Canine

**BREED**

Golden Retriever/Toy Poodle

**Pancreas**

The base and limbs of the **pancreas** were observed to be largely isoechoic to surrounding omental fat. Pancreatic duct and capsular contour were acceptably normal and parenchyma respected normal curvilinear patterns. No overt evidence of active inflammatory or neoplastic disease was noted.

**SEX**

Spayed female

**AGE**

8 years

**ULTRASONOGRAPHIC FINDINGS**

Benign hepatopathy.

**WEIGHT**

35 lbs

**INTERPRETATION OF THE FINDINGS & FURTHER RECOMMENDATIONS**

**INTERPRETED BY**

Eric Lindquist, DMV DABVP, Cert. IVUSS

The changes are largely expected change for this age and breed. If adrenal disease is suspected full sedation and further imaging of the right adrenal gland is indicated.

**IMAGING PERFORMED BY**

Jeremiah Gabriel

**HOSPITAL NAME**

Central Jersey AH

**REFERRING VET**

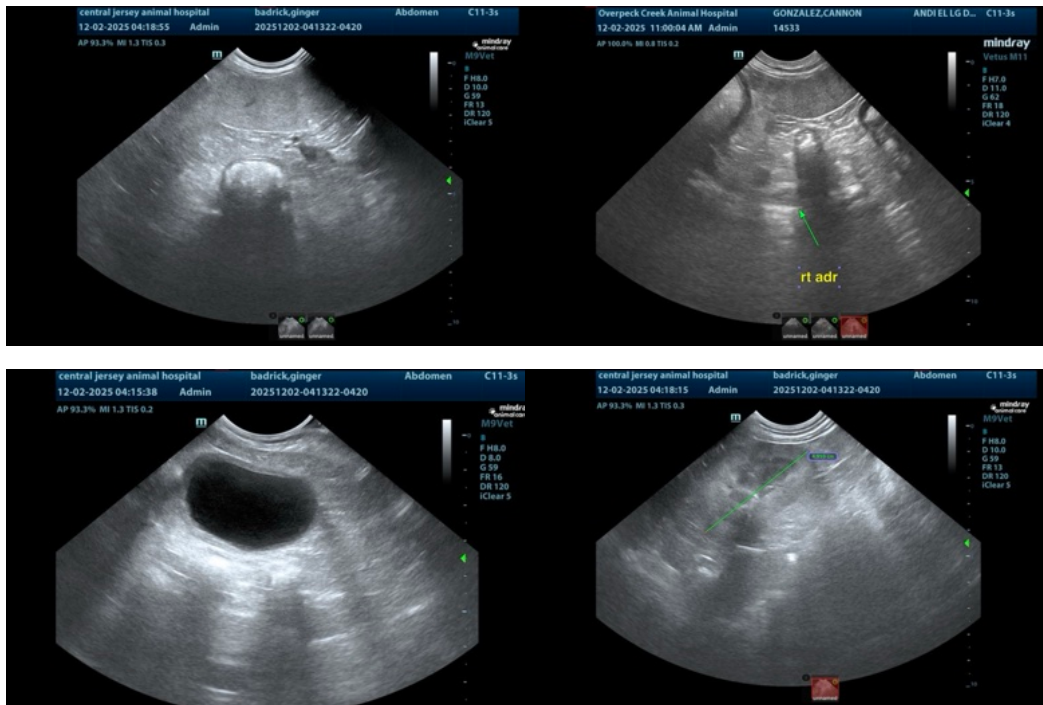
Dr. Gabriel

**INVOICE**

69249

**DATE**

12/2/25





## PATIENT

Ginger Badrick

## SPECIES

Canine

## BREED

Golden Retriever/Toy  
Poodle

## SEX

Spayed female

## AGE

8 years

## WEIGHT

35 lbs

## INTERPRETED BY

Eric Lindquist, DMV  
DABVP, Cert. IVUSS

## IMAGING PERFORMED BY

Jeremiah Gabriel

## HOSPITAL NAME

Central Jersey AH

## REFERRING VET

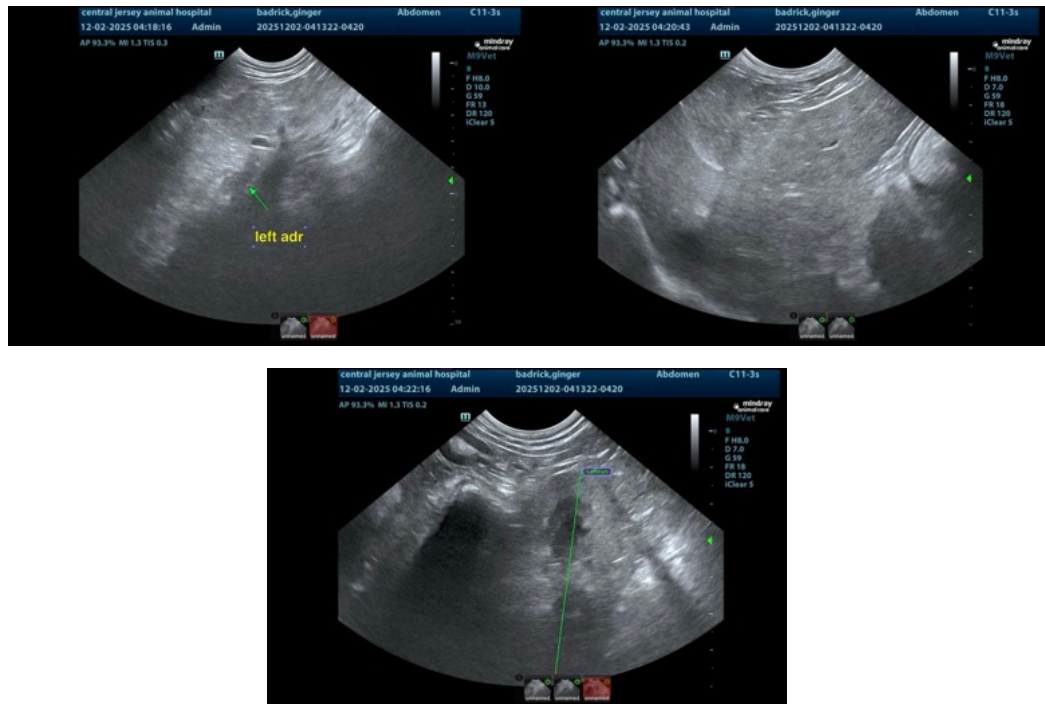
Dr. Gabriel

## INVOICE

69249

## DATE

12/2/25



The information and recommendations provided are based on the images presented by the referring veterinarian/sonographer. No evaluation can be communicated regarding pathology that was not visible in the image/video clips provided.

Thank you for this referral. If the clinical or image interpretation does not parallel your findings or if I can be of any further assistance please contact me.

Eric Lindquist, DMV, DABVP (CFM), Cert. IVUSS, CEO of SonoPath.com

[info@SonoPath.com](mailto:info@SonoPath.com)