



**PATIENT**

Tressa Texas  
Northstar Rescue

**SPECIES**

Canine

**BREED**

Mix

**SEX**

Female

**AGE**

12 Years

**WEIGHT**

14 Pounds

**PRESENTING CLINICAL SIGNS**

coughing more than normal, diarrhea for the past 4 weeks even on Metro

**ULTRASONOGRAPHIC EXAMINATION OF THE HEART & ABDOMEN**

CANINE CARDIAC PARAMETERS	MR VMAX (m/s)	TR VMAX (m/s)	LA/AO (Boon method)	LA/AO (Heart Base; Swe)	FS (%)	EF (%)	EPSS (cm)
NORMAL PARAMETER	4.5-5.5	<2.7	1.3	<1.6	28-40	40-100	<0.6
PATIENT	>5.0		2.0	2.3	33	62	0.3
CANINE CARDIAC PARAMETERS	HR (BPM)	AV VMAX (m/s)	PV MAX (m/s)	BODY WEIGHT (kg)	LA 2D short axis Base view (cm)	LVIDd Avg; 2D and m-mode short axis (cm)	LVIDs Avg; 2D and m-mode short axis (cm)
NORMAL PARAMETER	50-100	0.7-1.7	0.7-1.6	BELOW	BELOW	BELOW	BELOW
PATIENT	143		0.5		4.34	3.6	

**Cardiac Presentation**

The echocardiogram for this patient presented excessive **left atrial size** expressed both in the LA/AO and LA max measurements Chamber volumes and echogenicity were normal. The cranial and caudal **mitral** valve leaflets presented vegetative thickening consistent with endocardiosis. Doppler indicated measurable insufficiency. The **left ventricle** presented thicknesses with linear contour and was not dilated nor restricted. The **myocardium** presented normal echogenicity without subjective evidence of significant fibrotic or ischemic disease. **Contractility** of the ventricular walls was adequate and in normal range for this patient evidenced by the fractional shortening measurement and subjective evaluation of the different regions of the myocardium. The **left ventricular outflow** tract demonstrated normal laminar flow and subjective structural integrity. The **right atrium** and auricle revealed normal size, structure and content. No evidence of masses was noted or chamber overload. **Tricuspid** insufficiency noted. The **right ventricle** was of normal size (1/3 diameter of LV), chordae structure, myocardial echogenicity and thickness. **Pulmonic** tract assessment revealed normal valve structure, laminar flow, and diameter (approx.1:1 pa/ao ratio). No visible **pericardial** or free pleura fluid was noted. No echographically detectable evidence of infiltrative disease was visible. The cranial **mediastinum and pericardial regions** were free of masses in the visible window. Hepatic veins were dilated with ascites, consistent with right-sided heart failure.

**Urinary System**

The **urinary bladder**, trigone, and pelvic urethra presented normal thicknesses and normal tone. The ureters were not visible which is normal. No uroliths or sediment were visualized and anechoic urine was present. No evidence of inflammatory or neoplastic changes were noted. Ureteral papillae were normal.

The **kidneys** revealed largely normal size and structure, corticomedullary definition and ratio (cortex 1/3 of medulla) were essentially maintained with some age-related loss of curvilinear patterns regarding the capsule and C/M junction. The cortices presented largely uniform texture with some increased

**INTERPRETED BY**

Eric Lindquist, DMV  
DABVP, Cert. IVUSS

**IMAGING PERFORMED BY**

Jenn

**HOSPITAL NAME**

Rockaway AH

**REFERRING VET**

Dr. Gannon

**INVOICE**

43140

**DATE**

12/2/22



**PATIENT**

Tressa Texas  
Northstar Rescue

echogenicity expected for his age patient. Medullary structure differed distinctly from that of the cortex. The right kidney measured 4.6 cm. The left kidney measured 4.22 cm. Mineralization and slightly pyelectasia noted in both kidneys.

**SPECIES**

Canine

**Adrenal Glands**

Both **adrenal glands** were visualized and recognized as having normal shape, size, position and echogenicity for this breed. The phrenic vasculature, glandular echogenicity and detail were unremarkable. Capsule, cortex, and medullary definition were normal for this age patient. The right adrenal gland measured 2.08 cm x 1.33 cm at the cranial pole and 0.62 cm at the caudal pole. The left adrenal gland measured 1.82 cm x 0.67 cm at the caudal pole and 0.66 cm at the cranial pole.

**BREED**

Mix

**Spleen**

The **spleen** presented a smooth homogeneous parenchyma hyperechoic to liver and renal cortical parenchyma. The capsule was smooth without noticeable expansion or deviation from within the spleen or adjacent pathology. The splenic vasculature demonstrated normal volume without signs of congestion or thrombosis. No sonographic evidence of acute or chronic inflammatory, neoplastic, or infarctual changes were noted.

**SEX**

Female

**AGE**

12 Years

**Liver**

The **liver** revealed increased portal markings, isoechoic non-disruptive nodular changes, and irregular contour. Passive congestion pattern. Minor gallbladder debris noted. Hepatic veins were dilated with ascites, consistent with right-sided heart failure. Vena cava was 1.3:1.0 ratio with the aorta.

**WEIGHT**

14 Pounds

**Gastrointestinal**

Examination of the **gastrointestinal tract** revealed a stomach and intestine free of stasis, of normal wall thickness, acceptable curvilinear mural detail, and peristaltic activity. Small and large intestine demonstrated normal luminal chyme and stool consistency respectively. No obstructive or overt infiltrative disease was noted. No associated abnormal lymphatic activity was noted.

**INTERPRETED BY**

Eric Lindquist, DMV  
DABVP, Cert. IVUSS

**Pancreas**

The base and limbs of the **pancreas** were observed to be largely isoechoic to surrounding omental fat. Pancreatic duct and capsular contour were acceptably normal and parenchyma respected normal curvilinear patterns. No overt evidence of active inflammatory or neoplastic disease was noted.

**IMAGING PERFORMED BY**

Jenn

**ULTRASONOGRAPHIC FINDINGS**

**HOSPITAL NAME**

Rockaway AH

- Emerging left and right-sided heart failure
- Passive congestion liver pattern
- Age related renal changes with mineralization

**REFERRING VET**

Dr. Gannon

**INTERPRETATION OF THE FINDINGS & FURTHER RECOMMENDATIONS**

Given the current medications, I recommend adjustment of adding Lasix 1-2 mg/kg BID, ensuring Enalapril is utilized at 0.5 mg/kg BID and recheck echocardiogram in one month or earlier if clinical signs are an issue. Resting respiratory rate target of <25 p/m.

**INVOICE**

43140

**DATE**

12/2/22



**PATIENT**

Tressa Texas  
Northstar Rescue

**SPECIES**

Canine

**BREED**

Mix

**SEX**

Female

**AGE**

12 Years

**WEIGHT**

14 Pounds

**INTERPRETED BY**

Eric Lindquist, DMV  
DABVP, Cert. IVUSS

**IMAGING PERFORMED BY**

Jenn

**HOSPITAL NAME**

Rockaway AH

**REFERRING VET**

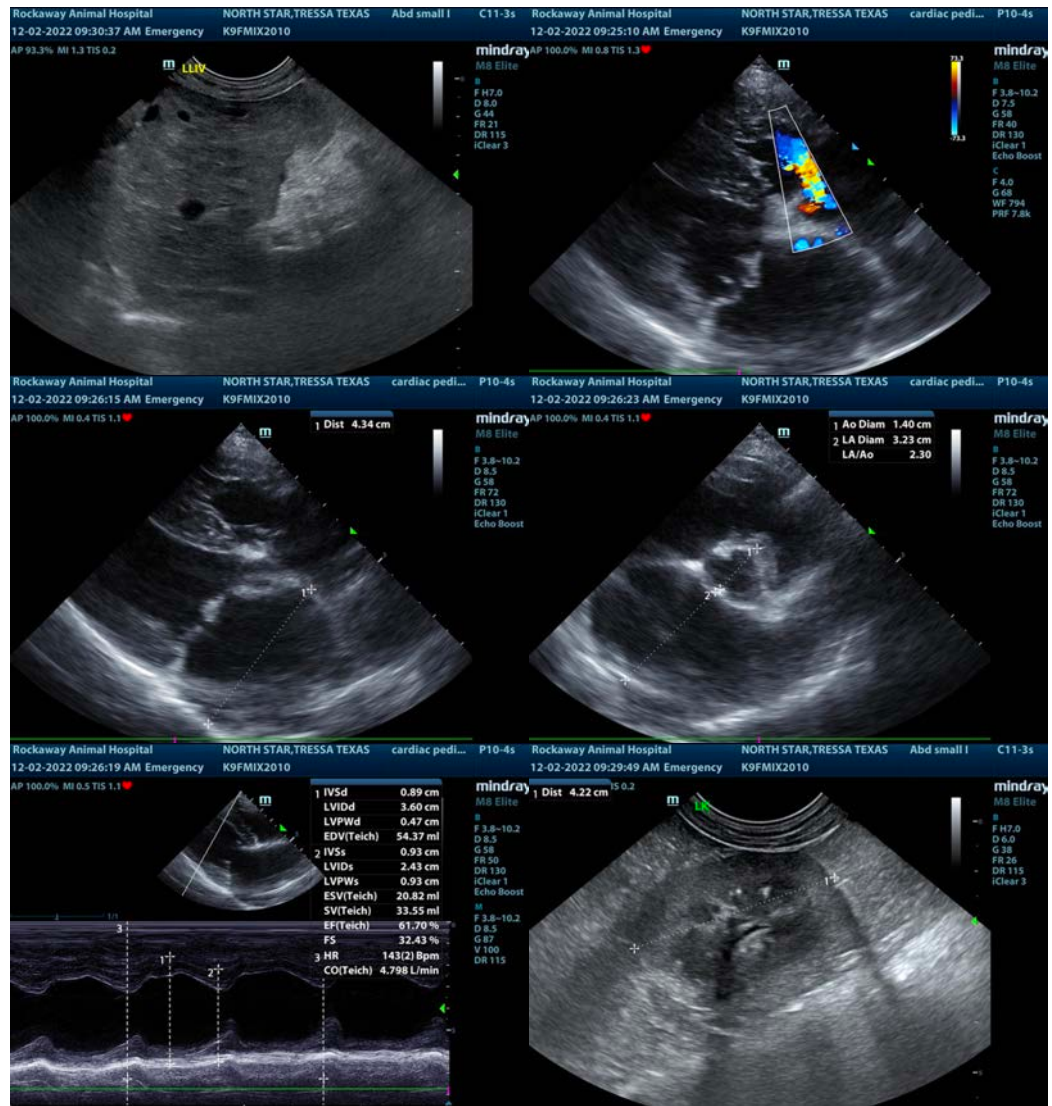
Dr. Gannon

**INVOICE**

43140

**DATE**

12/2/22





**PATIENT**

Tressa Texas  
Northstar Rescue

**SPECIES**

Canine

**BREED**

Mix

**SEX**

Female

**AGE**

12 Years

**WEIGHT**

14 Pounds

**INTERPRETED BY**

Eric Lindquist, DMV  
DABVP, Cert. IVUSS

**IMAGING PERFORMED BY**

Jenn

**HOSPITAL NAME**

Rockaway AH

**REFERRING VET**

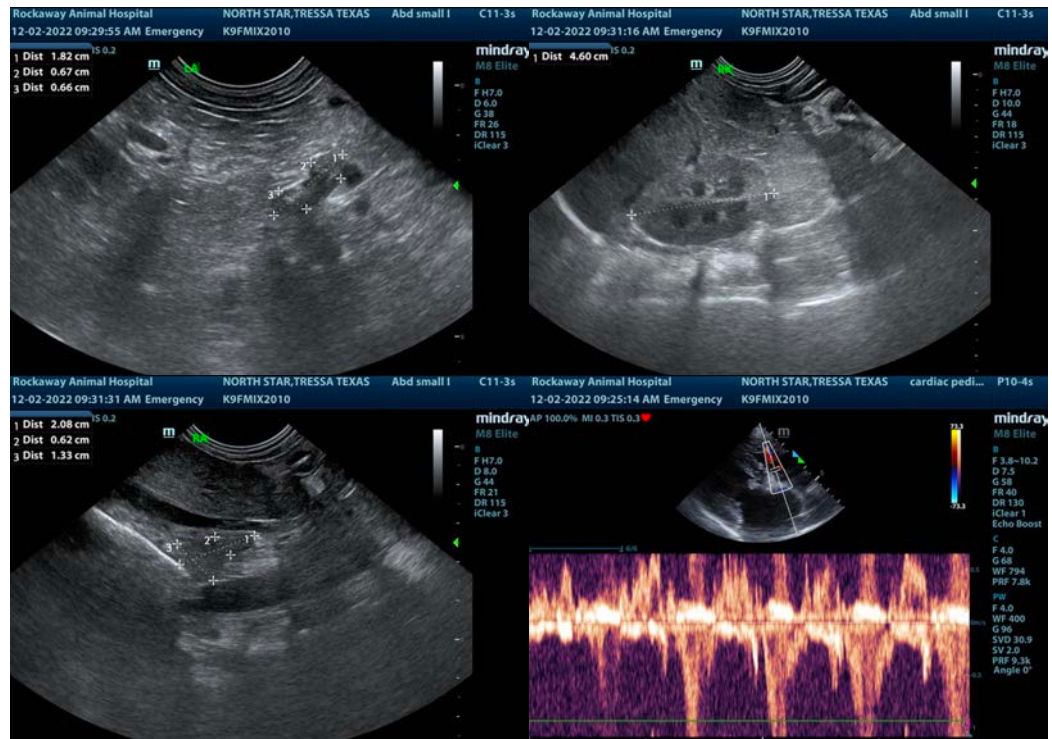
Dr. Gannon

**INVOICE**

43140

**DATE**

12/2/22



The information and recommendations provided are based on the images presented by the referring veterinarian/sonographer. No evaluation can be communicated regarding pathology that was not visible in the image/video clips provided.

Thank you for this referral. If the clinical or image interpretation does not parallel your findings or if I can be of any further assistance please contact me.

**Eric Lindquist, DMV, DABVP, Cert. IVUSS, CEO of SonoPath.com**

[info@SonoPath.com](mailto:info@SonoPath.com)